

# Percutaneous Intervention in Axillary Loop-Configured Arteriovenous Grafts for Chronic Hemodialysis Patients

Beom Jin Park, MD<sup>1</sup>  
Hyoung Rae Kim, MD<sup>2</sup>  
Hwan Hoon Chung, MD<sup>1</sup>  
Deuk Jae Sung, MD<sup>1</sup>  
Sang Joon Park, MD<sup>1</sup>  
Ho Sung Son, MD<sup>3</sup>  
Sang Kyung Jo, MD<sup>4</sup>  
Yun Hwan Kim, MD<sup>1</sup>  
Sung Bum Cho, MD<sup>1</sup>

## Index terms:

Dialysis, shunt  
Graft, interventional procedure  
Veins, transluminal angioplasty

DOI:10.3348/kjr.2010.11.2.195

*Korean J Radiol* 2010; 11: 195-202

Received September 16, 2009; accepted after revision November 3, 2009.

Departments of <sup>1</sup>Radiology, <sup>3</sup>General Thoracic and Cardiovascular Surgery, and <sup>4</sup>Internal Medicine, College of Medicine, Korea University, Seoul 136-705, Korea; <sup>2</sup>Department of Radiology, College of Medicine, Kangwon National University, Kangwon-do 200-947, Korea

## Address reprint requests to:

Hyoung Rae Kim, MD, Department of Radiology, College of Medicine, Kangwon National University Hospital, 17-1 Hyoja 3-dong, Chuncheon-si, Kangwon-do 200-947, Korea.  
Tel. (8233) 258-2328  
Fax. (8233) 258-2221  
e-mail: deimos@kangwon.ac.kr

**Objective:** The purpose of this study was to evaluate the fistulographic features of malfunctioning axillary loop-configured arteriovenous grafts and the efficacy of percutaneous interventions in failed axillary loop-configured arteriovenous grafts.

**Materials and Methods:** Ten patients with axillary loop-configured arteriovenous grafts were referred for evaluation of graft patency or upper arm swelling. Fistulography and percutaneous intervention, including thrombolysis, percutaneous transluminal angioplasty and stent placement, were performed. Statistical analysis of the procedure success rate and the primary and secondary patency rates was done.

**Results:** Four patients had graft related and subclavian venous stenosis, two patients had graft related stenosis and another four patients had subclavian venous stenosis only. Sixteen sessions of interventional procedures were performed in eight patients (average: 2 sessions / patient) until the end of follow-up. An interventional procedure was not done in two patients with central venous stenosis. The overall procedure success rate was 69% (11 of 16 sessions). The post-intervention primary and secondary patency rates were 50% and 63% at three months, 38% and 63% at six months and 25% and 63% at one year, respectively.

**Conclusion:** Dysfunctional axillary loop-configured arteriovenous grafts almost always had subclavian venous and graft-related stenosis. Interventional treatments are helpful to overcome this and these treatments are expected to play a major role in restoring and maintaining the axillary loop-configured arteriovenous loop grafts.

**A**n autogenous arteriovenous fistula (AVF) is clearly the surgical modality of choice for end-stage renal disease (ESRD) patients on hemodialysis. Creation of a fistula between the cephalic vein and the radial or brachial artery is widely regarded as the ideal vascular access. Unfortunately, only a minority of patients who have ESRD and require vascular access have suitable vessels to create an autogenous fistula (1). Furthermore, the number of patients who have exhausted their upper extremity arteriovenous dialysis access sites and who have also lost all chances for a conventional upper extremity arteriovenous dialysis access has been increasing, and this is in line with the general increase of the hemodialysis patient population (2).

In our institute, axillary loop-configured arteriovenous grafts (ALAVGs) were created in those patients who had lost all opportunities for having upper extremity arteriovenous dialysis access. We experienced dysfunctional ALAVGs and then we

performed percutaneous interventions. There are some surgical reports on this type of exotic arteriovenous graft (AVG). However, there have been only a few published studies on the results of interventional procedures in such grafts (3–5). The purpose of this study was to evaluate the fistulographic features of ALAVGs and the efficacy of percutaneous intervention in malfunctioning ALAVGs.

## MATERIALS AND METHODS

From March 2003 to February 2005, 10 patients (3 males and 7 females: mean age, 58.7 years [range, 43–76 years]) with ALAVGs were referred to our interventional radiology practice for evaluation of graft patency or upper arm swelling. This study was approved by our Institutional Review Board, and all the patients gave us their informed written consent. The patients had no central venous stenosis or obstruction on venography before creation of the hemodialysis grafts. All patients had lost their optimal sites for a hemodialysis fistula or graft in both upper extremities and they had undergone an operation for creating ALAVGs with a 4–6 mm or 4–7 mm ringed-tapered polytetrafluoroethylene graft (PTFE, Vascugraft B BRAUN, Berlin, Germany).

Eight patients were referred for evaluation and treatment of graft dysfunction or graft failure, which was clinically suggested on the basis of clot aspiration, decreased or impalpable thrill, and a decreased flow rate during hemodialysis. The other two patients had swelling of the ipsilateral upper arm (Table 1). The interval between the creation of the ALAVGs and the first intervention was 7 to 1,184 days (average,  $272.8 \pm 329.1$ ).

## Fistulography and the Interventional Procedures

All the interventional procedures were performed with the patients admitted to the hospital. A duplex ultrasound examination was done prior to the interventional procedures. When thrombus was present, 100,000 IU of urokinase was administered into the graft, and aspiration thrombectomy was done 1 or 2 hours later (the 'lyse and wait' technique) (6). The 'apex puncture technique' was used in all cases (7). The apex of the graft was punctured using a 21 gauge needle, and contrast media was then slowly injected. An 8 Fr Hoffman sheath (Cook, Bloomington, IN) was inserted through the apex of the graft, and manual aspiration was then performed. The thrombus in the venous limb was aspirated first and, if present, any thrombus in the arterial limb was then removed after changing the direction of the sheath into the arterial limb. Fistulography was repeated after aspiration thrombectomy by using a 5 Fr multiside-hole or Cobra Catheters (Cook, Bloomington, IN) to evaluate the precise location of any stenosis or central venous stenosis, and to determine the diameters of the graft and vein.

Percutaneous transluminal angioplasty (PTA) was performed after the stenosis was diagnosed, 6 to 8 mm PTA balloon dilatation catheters were used for the intragraft and anastomotic stenoses, and 12–14 mm PTA balloon dilatation catheters were used for the central venous stenoses. A 6 to 8 mm cutting balloon catheter (Boston Scientifics, IN) was applied when necessary to abolish the waist of a tight stenosis. A small amount of residual thrombus, if present, was pushed out into the central veins after dilatation of the stenotic segment.

A stent was applied in the case of elastic recoil after PTA with using the usual balloon catheter or a cutting balloon catheter.

**Table 1. Demographic Data and Fistulographic Features in All Cases**

Case No.	Gender	Age	Interval between Operation and First Intervention	Size of ALAVG	Cause of Fistulography	Stenosis Site			
						Arterial Anastomosis	Venous Anastomosis	Intragraft	Subclavian Vein
1	F	43	235 days	4 – 6 mm	Clot aspiration	o	o		
2	M	57	204 days	4 – 6 mm	Clot aspiration	o	o	o	o
3	F	73	7 days	4 – 6 mm	Decreased thrill				o
4	F	49	211 days	4 – 6 mm	Clot aspiration				o
5	F	48	252 days	4 – 6 mm	Clot aspiration	o			o
6	F	67	199 days	4 – 6 mm	Decreased blood flow rate	o		o	
7	M	45	1,184 days	4 – 7 mm	Decreased blood flow rate	o	o	o	o
8	M	76	114 days	4 – 6 mm	Upper arm swelling				o
9	F	75	225 days	4 – 6 mm	Impalpable thrill	o	o	o	o
10	F	54	97 days	4 – 6 mm	Upper arm swelling				o

Note.—ALAVG = axillary loop-configured arteriovenous graft

## Percutaneous Intervention in Axillary Loop-Configured AV Grafts for Chronic Hemodialysis Patients

A duplex sonographic exam was performed first for the case of upper arm swelling. The basilic vein was punctured under ultrasonographic guidance and a 6–8 Fr introducing sheath was inserted. A larger size introducing sheath than the usual size was preferred due to the PTA. A 5 Fr multisidehole catheter (Cook, Bloomington, IN) was introduced into the basilic vein for venography. When a central vein stenosis was found, a 5 Fr Cobra catheter (Cook, Bloomington, IN) was advanced into the subclavian artery via the graft to evaluate the precise location of the anastomotic sites and the anastomotic stenosis. Dilatation of the stenotic central vein was then performed.

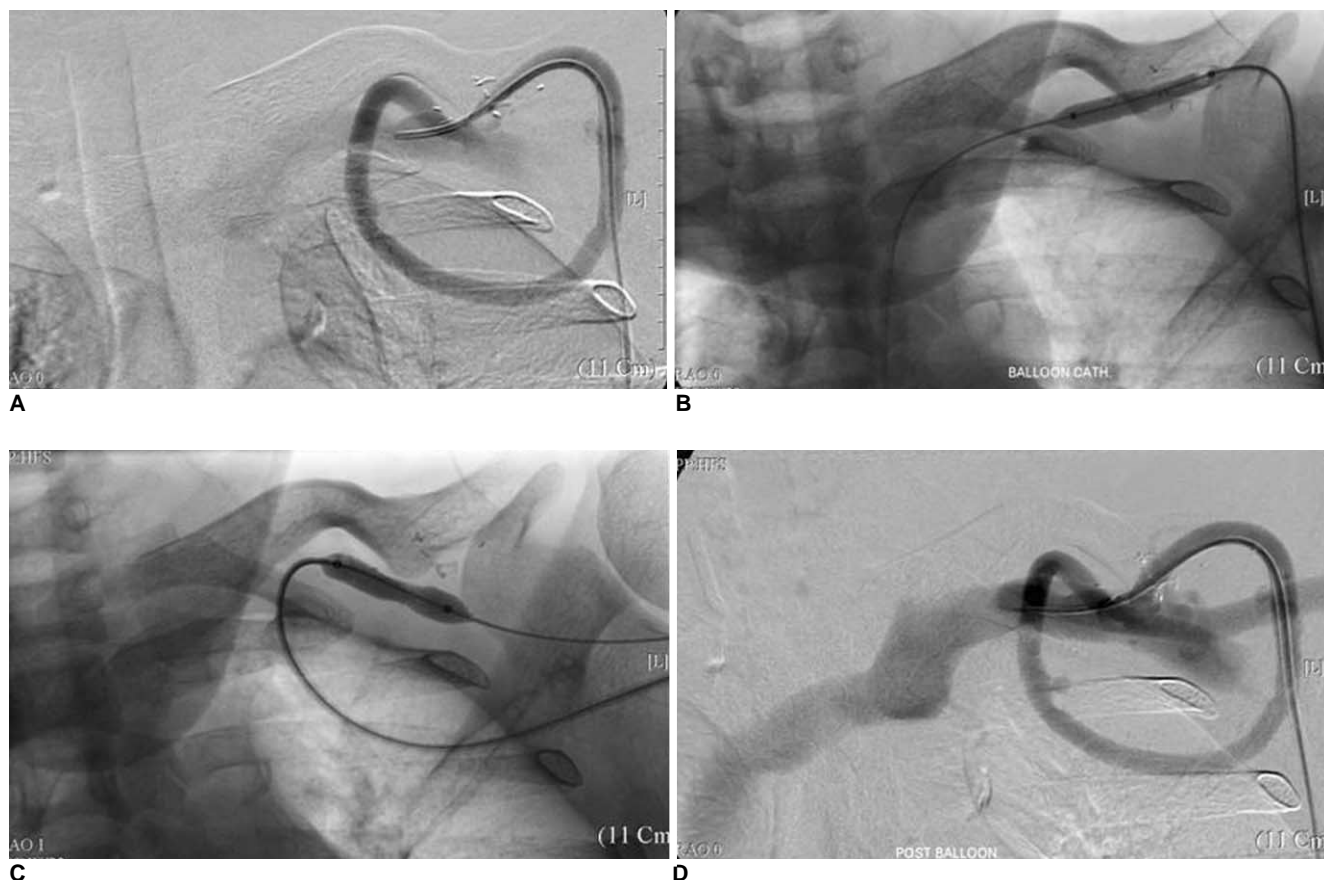
After the interventional procedures, the puncture sites were closed with a symmetric purse-string suture arrangement using 4–0 nylon monofilament (Ethicon; Johnson & Johnson, Somerville, NJ).

### Definitions and the Study Endpoints

Follow-up was ended on June 2006 and a retrospective review of the patients' charts was done. The procedural success rate, the post-intervention primary and secondary

patency rates and the complications were defined according to 'reporting standards for percutaneous interventions in dialysis access' (8). The procedural success rate was defined as an anatomic success with at least one indicator of either hemodynamic or clinical success. Primary patency was defined as the interval following intervention until the next access thrombosis or repeated intervention. Secondary patency meant the interval after intervention until the access was surgically declotted, revised or abandoned because of the inability to treat the original lesion, the choice of the surgeon, transplant, the patient was lost to follow-up etc. Death of a patient was regarded as a censored case. The 6 month and 12 month post-intervention primary and secondary patency rates were calculated by the Kaplan-Meier Method using the SPSS for Windows, version 12.0 (SPSS Inc, Chicago, IL).

Major complications were defined as those resulting in admission to a hospital for therapy, an unplanned increase in the level of care, prolonged hospitalization, permanent adverse sequela or death.



**Fig. 1.** 43-year-old female patient (case no. 1) was referred for evaluation of graft patency due to clot aspiration. Initial fistulogram showed stenosis at arterial and venous anastomoses (A). Percutaneous transluminal angioplasty was performed with 7 mm x 4 cm sized balloon catheter (B, C). Final fistulogram showed improvement of stenoses and no flow disturbance (D). Hemodialysis has been performed with this axillary to axillary autogenous arteriovenous fistula graft for 262 days after percutaneous intervention.

## RESULTS

### *Fistulographic Features*

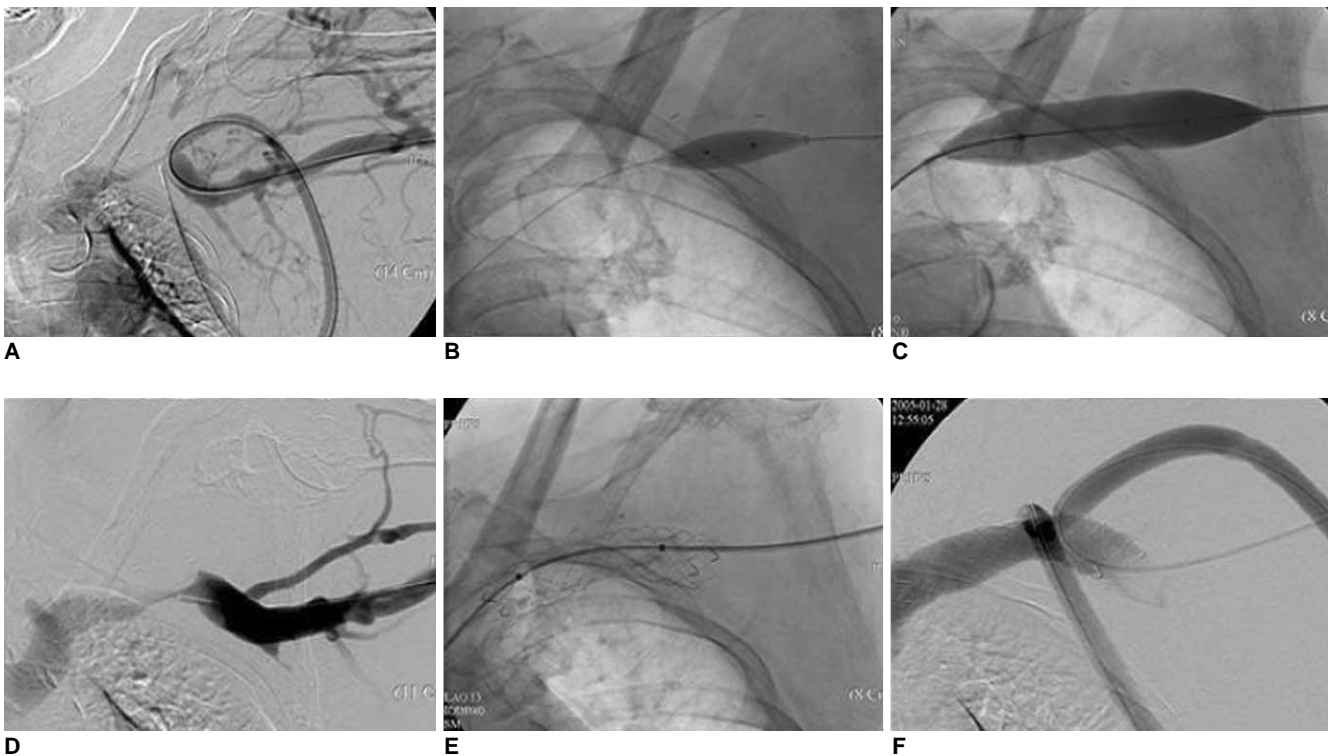
In all the patients, the outflow vein was the infraclavicular proximal axillary vein, and the inflow artery was proximal axillary artery just beneath the infraclavicular proximal axillary vein. All the arterial and venous anastomoses were located near the pinch-off region and they overlapped each other (Fig. 1).

On the initial fistulographies, six patients (60%) had graft-related stenosis; the stenosis was at the arterial anastomosis in all six patients (100%), the stenosis was at the venous anastomosis in four (67%), the stenosis was at both the arterial and venous anastomosis in four (67%) and there was an intragraft stenosis in four patients (Table 1). Of the six patients with a graft-related stenosis, four patients also had a subclavian or proximal axillary vein stenosis. The other four patients showed subclavian or proximal axillary vein stenosis without a graft-related stenosis, so there was a total of eight patients who showed subclavian or proximal axillary vein stenoses. Of these eight patients, only four patients (50%) had difficult hemodialysis or hemodialysis failure and they showed

graft-related stenoses; both arterial and venous anastomotic stenosis were found in three patients (3 of 4 patients, 75%), and arterial anastomotic stenosis was found in one patient. The other four patients had neither hemodialysis failure nor graft-related stenosis on their fistulograms. Two patients complained of ipsilateral arm swelling that necessitated an interventional procedure. The other two patients were referred for clot aspiration or decreased thrill; nevertheless, they did not have difficult hemodialysis or hemodialysis failure. No further intervention was needed.

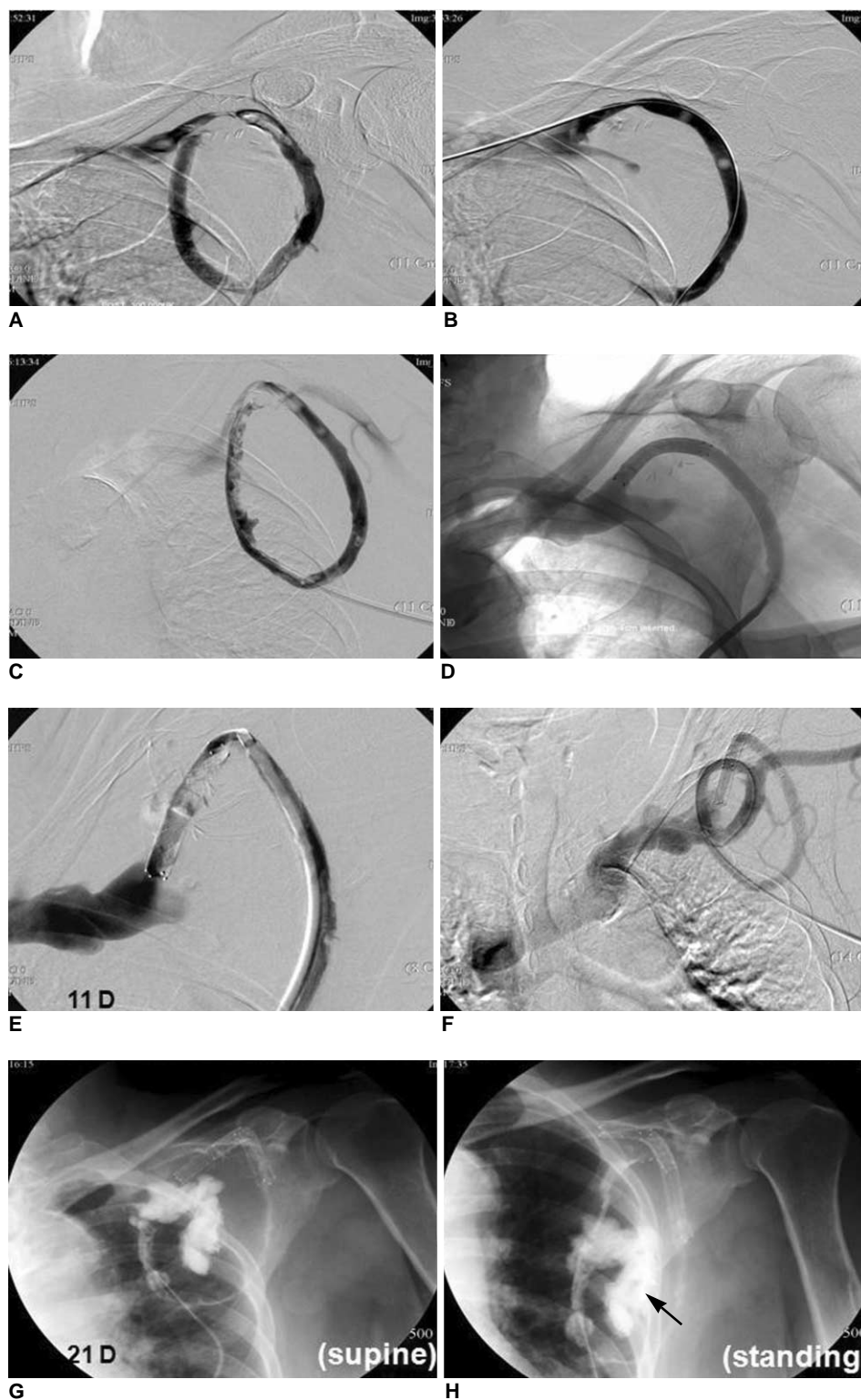
### *Interventional Procedures*

Sixteen sessions of interventional procedures were performed in eight patients (an average of 2 sessions/patient) until the end of follow-up, and six patients experienced two or more interventional procedures: there were eight sessions of PTA with thrombolysis, five sessions of PTA only and three sessions of stent placement (Figs. 2, 3). In one female patient, 6 mm × 4 cm and 6 mm × 8 cm sized Zilver vascular stents (Cook, Bloomington, IN) were placed for relieving a residual stenosis at a venous anastomosis, but complete failure of the graft occurred. She was obese and had big breasts. The AVG was movable in



**Fig. 2.** 54-year-old female patient (case no. 10) was referred for evaluation of upper arm swelling. Venography and fistulography showed stenosis in subclavian vein with multiple collateral veins and normal fistulogram (A). After conventional balloon angioplasty, waist of stenosis did not disappear. We used 8 mm × 2 cm sized cutting balloon (B) and we performed repeated percutaneous transluminal angioplasty with 14 mm × 4 cm balloon catheter. Waist then disappeared (C). Immediate elastic recoil was found on post-procedural venography (D). Three days after percutaneous transluminal angioplasty, 14 mm by 6 cm sized Hercules stent was placed (E), and venogram showed no flow disturbance in arteriovenous graft and subclavian vein.

### Percutaneous Intervention in Axillary Loop-Configured AV Grafts for Chronic Hemodialysis Patients



**Fig. 3.** 67-year-old female patient (case no. 6) visited our interventional radiology practice for evaluation of graft dysfunction. Initial fistulogram showed thrombus in graft, and 'lyse and wait' technique was performed. Residual thrombus and stenosis at venous arm of graft were noted on repeated fistulogram (A). Aspiration thrombectomy and percutaneous transluminal angioplasty were done, but elastic recoil occurred (B). On next day, thrombosis relapsed (C) and 6 mm by 4 cm Zilver stent was placed in stenotic venous arm after removal of thrombus (D). Eleven days after stent placement, repeated thrombosis was noted on fistulogram, and graft was bent at distal end of stent (E). Additional 8 mm by 4 cm Zilver stent was placed distally (F). After 21 days, patient was referred for graft dysfunction. Fistulogram with position change (G, H) showed kinking of venous anastomosis of graft in standing position. Graft moved downward in standing position, and proximal end of stent folded graft up (arrow). Patient refused additional interventions and tunneled hemodialysis catheter was placed through right internal jugular vein.

accordance with standing and lying down, and also according to movement of the shoulder joint. So the cephalic vein was folded at the point of the proximal end of the stent and the graft was completely occluded. In one case of subclavian venous stenosis, a 14 mm × 6 cm self-expandable Hercules stent (S&G Biotech, Seoul, Korea) was placed because of recoiling phenomenon after PTA. Only fistulography was done in the other two patients. The overall procedure success rate was 69% (11 of 16 sessions). Among the eight patients with subclavian venous stenosis, only four patients with simultaneous graft-related stenosis had problems during hemodialysis. On the other hand, the other four patients without simultaneous graft-related stenosis did well; nevertheless, their subclavian veins were stenotic. Among all six patients with graft-related stenosis, four patients showed subclavian venous stenosis and so balloon angioplasties were done. However, hemodialysis failure or difficult hemodialysis did not occur, even though the residual stenosis of the subclavian vein was over 30% in diameter after PTA.

Follow-up was possible in nine patients with an average follow-up period of 415.5 days (range: 1 – 700 days). Six ALAVGs were functioning at the end of follow-up and three ALAVGs were terminated. In the case of termination of the ALAVG, tunneled hemodialysis catheters were inserted for hemodialysis access. One patient died two weeks after fistulography due to acute myocardial infarction (Table 2).

The post-intervention patency rates are detailed in Figure 4. The post-intervention primary and secondary

patency rates of our study were 50% and 63% at three months, 38% and 63% at six months and 25% and 63% at one year, respectively.

No major complications occurred. In one patient, distal arterial embolization occurred at the bifurcation level of the brachial artery, and this was successfully treated with thrombolysis and aspiration of the residual embolus. Yet hospitalization was not prolonged in spite of thrombolysis therapy and no other complication was noted.

## DISCUSSION

When all the upper extremity sites for creating an arteriovenous fistula in a chronic hemodialysis patient are exhausted, the secondary site that's most frequently

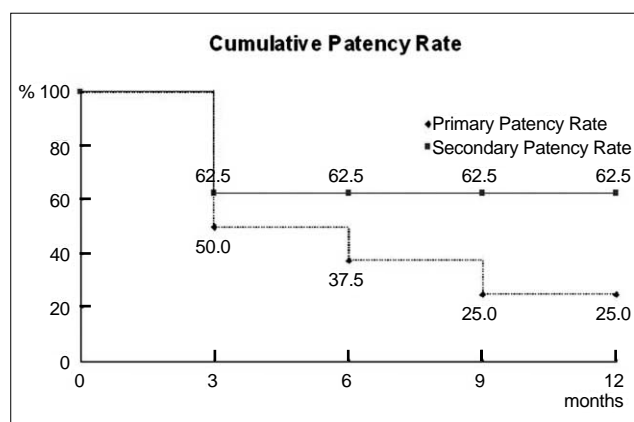


Fig. 4. Post-intervention cumulative primary and secondary patency rates.

Table 2. Types and Results of Percutaneous Intervention in Each of Cases

Case No.	Number of Procedures	Type of Procedures	Size of Balloon Catheter	Size of Stent	Status at End of Follow-up
1	1	PTA	6 mm × 4 cm		Functioning
2	1	PTA with thrombolysis	8 mm × 4 cm		Functioning
3	0	Observation	7 mm × 4 cm		Death
4	0	Observation			Functioning
5	4	PTA	6 mm × 4 cm		Functioning
6	3	PTA with thrombolysis, Stent placement	12 mm × 4 cm	6 mm × 4 cm 6 mm × 8 cm	Terminated
7	2	PTA with thrombolysis	6 mm × 4 cm 6 mm × 2 cm (CB*)		Terminated
8	1	PTA	7 mm × 4 cm		Functioning
9	2	PTA with thrombolysis	12 mm × 4 cm		Terminated
10	2	PTA Stent placement	7 mm × 4 cm 12 mm × 4 cm	8 mm × 2 cm (CB*) 14 mm × 6 cm	Functioning

Note.— PTA = percutaneous transluminal angioplasty, CB\* = cutting balloon catheter

selected is the leg or permanent venous catheters are used. However, the femoral vessels are frequently diseased and the femoral AVG has a high rate of complications such as infection (20%), thrombosis, extremity loss (22%) and even a high mortality rate (20%) (9, 10). Permanent central venous catheters also show a high rate of septic complications, low patency rates and discomfort (11). The use of the axillary artery and vein as dialysis access sites is not a new idea, and various types of AVGs in the anterior chest wall have been described in the literature since Manning et al. (12) first reported on an experimental case in 1975 (2, 12–16). However, an ipsilateral ALAVG is not popular at present. Hazinedaroglu et al. (2) described only three cases of ipsilateral ALAVGs among 27 AVGs in the anterior chest wall, and Jean-Baptiste et al. (3) reported the midterm results of 27 cases of ipsilateral ALAVG and they suggested that ALAVG construction may be preferable to lower extremity vascular access. Although we had not reviewed all the cases of ALAVGs in our institute, the results of our study also suggest that construction of an ALAVG may be preferable to lower extremity arteriovenous hemodialysis access.

In a large series of AVG stenoses, Maya et al. (17) found that venous anastomosis was the most common site of stenosis in an AVG, followed by stenoses of the venous outlet, intragraft stenoses, central vein stenoses and arterial anastomosis stenoses. In our present study, the distal subclavian or proximal axillary vein adjacent to the venous anastomosis was the most common site of stenosis, while arterial anastomotic stenosis was the second most common, followed by venous anastomotic and intragraft stenoses. Jean-Baptiste et al. (3) reported two cases of stenosis in the postanastomotic outflow vein with ipsilateral axillary loop grafts. In most cases of AVG, a subclavian vein stenosis is a consequence of previous subclavian catheterizations or high flow from an arteriovenous fistula (18). Yet in our series, no one had a history of ipsilateral subclavian vein catheterization or central vein stenosis on the preoperative venography. The reason for these differences is not presently clear. However, one possible reason could be the consequences of the surgical procedures. The anastomotic sites are very close to the pinch-off region and they are under the pectoralis major muscle. The space for anastomoses is narrow and surrounded by bone and muscle, which is in contrast to the conventional AVG in the upper extremity. Furthermore, the arterial and venous anastomoses overlap each other in that narrow space, and it is mandatory to dissect the pectoralis major muscle to expose the vessels and anastomose the graft to the vessels. Therefore, formation of granulation tissue and fibrosis is expected to be more abundant and to have a more severe

affect than that in a conventional AVG. As a consequence, stenoses of the subclavian and axillary veins and arterial anastomosis might occur more frequently. High-velocity, turbulent flow from the nearby graft might also affect the formation of intimal hyperplasia (18, 19).

For a PTFE AVG to function properly, there must be an adequate venous outflow, and stenosis of the venous outflow may cause dysfunction of a PTFE AVG. In the present study, a stenosis at the central vein, just proximal to the venous anastomosis, showed a suboptimal post-interventional result. These lesions might be more fibrous and have a greater chance of demonstrating elastic recoil than an intragraft or graft-related stenosis. Yet clinically, hemodialysis was performed without decreased flow or increased venous pressure. Although a 50% degree of narrowing or more was noted in a stenotic subclavian vein, the subclavian vein is a large vessel and it usually has abundant collaterals. Therefore, optimal flow for hemodialysis may be sustained. In the present study, only one patient needed stent placement in the subclavian vein due to elastic recoil after PTA and hemodialysis disturbance. Levit et al. (20) concluded that PTA of an asymptomatic central venous stenosis greater than 50% in the setting of hemodialysis access maintenance procedures is associated with more rapid progression of stenosis and escalation of lesions, as compared with a nontreatment approach, and Kanterman et al. (21) also reported that central vein stenosis rarely compromises the hemodialysis access function and that treatment with PTA may not be a necessary intervention. However, flow disturbance in the venous outflow tract and repeated thrombosis may occur due to changes of a patient's condition. This was the reason why we performed interventional procedures more frequently than that reported in the literature. Vijay et al. (22) reported that 1.22 interventions per graft year are necessary for maintaining access patency in the natural history of PTFE grafts. We performed an average of two interventions per patient.

Elastic recoil after conventional balloon angioplasty is not uncommon in a stenosis at a venous anastomosis, and stent placement in a rigid stenosis is an effective procedure (23–26). We performed two sessions of stent placement at a stenosis of the venous anastomosis in one female patient. However, the graft completely failed by kinking of the cephalic vein, which was due to the gravitational movement of the patient's breast. Another case of stent placement was performed in a subclavian vein stenosis and this showed good patency during the follow-up.

The post-intervention primary and secondary patency rates of our study were 50% and 63% at three months, 38% and 63% at six months and 25% and 63% at one



year, respectively. The primary patency rate at three months in our study was better than the minimum requirement recommended by the National Kidney Foundation (40% primary patency at three months after percutaneous thrombectomy). On the other hand, the primary and secondary patency rates at six months and one year were not so excellent. It is quite possible that these results might be due to the location of the graft near the pinch-off region as well as the configuration of the arterial and venous anastomoses overlapping each other.

The limitations of our study are the small sample size and the relatively lower primary and secondary patency rates at six month and one year than the results of percutaneous intervention in the usual AVG in the upper extremity. Other reports that have focused on an AVG in the anterior chest wall (4, 5) showed that percutaneous intervention was performed in three and five cases and this was successful in 66% (2 of 3) and 80% (4 of 5). But no available data about the primary and secondary patency rates after percutaneous intervention was noted. Further experiences with percutaneous intervention in failed ALAVGs will be needed in a larger population.

Despite of the small sample size, our study showed that an ALAVG is an alternative for patients who lost an opportunity for creating an autologous fistula and graft in their forearm and upper arm. Furthermore, percutaneous interventional treatments would be helpful for restoring and maintaining an ALAVG.

## References

- Fan PY, Schwab SJ. Vascular access: concepts for the 1990s. *J Am Soc Nephrol* 1992;3:1-11
- Hazinedaroglu S, Karakayali F, Tüzüner A, Ayli D, Demirer S, Duman N, et al. Exotic arteriovenous fistulas for hemodialysis. *Transplant Proc* 2004;36:59-64
- Jean-Baptiste E, Hassen-Khodja R, Haudebourg P, Declémy S, Batt M, Bouillanne PJ. Axillary loop grafts for hemodialysis access: midterm results from a single-center study. *J Vasc Surg* 2008;47:138-143
- Morsy MA, Khan A, Chemla ES. Prosthetic axillary-axillary arteriovenous straight access (necklace graft) for difficult hemodialysis patients: a prospective single-center experience. *J Vasc Surg* 2008;48:1251-1254
- Teruya TH, Schaeffer D, Abou-Zamzam AM, Bianchi C. Arteriovenous graft with outflow in the proximal axillary vein. *Ann Vasc Surg* 2009;23:95-98
- Cynamon J, Lakritz PS, Wahl SI, Bakal CW, Sprayregen S. Hemodialysis graft declotting: description of the "lyse and wait" technique. *J Vasc Interv Radiol* 1997;8:825-829
- Hathaway PB, Vesely TM. The apex-puncture technique for mechanical thrombolysis of loop hemodialysis grafts. *J Vasc Interv Radiol* 1999;10:775-779
- Gray RJ, Sacks D, Martin LG, Trerotola SO; Society of Interventional Radiology Technology Assessment Committee. Reporting standards for percutaneous interventions in dialysis access. *J Vasc Interv Radiol* 2003;14:S433-S442
- Morgan AP, Knight DC, Tilney NL, Lazarus JM. Femoral triangle sepsis in dialysis patients: frequency, management, and outcome. *Ann Surg* 1980;191:460-464
- Taylor SM, Eaves GL, Weatherford DA, McAlhany JC Jr, Russell HE, Langan EM 3rd. Results and complications of arteriovenous access dialysis grafts in the lower extremity: a five year review. *Am Surg* 1996;62:188-191
- Blankestijn PJ. *Cuffed tunneled catheters for long-term vascular access*. In: Conlon PJ, Schwab SJ, Nicholson ML (eds). *Hemodialysis vascular access practice and problems*. New York: University Press, 2001:67-68
- Manning LG, Mozersky DJ, Murray HM, Hagood CO. Axillary-axillary bovine arteriovenous fistula for hemodialysis. *Arch Surg* 1975;110:114-115
- Duclos J, Gil F. Axillo-axillary prosthetic internal arteriovenous fistula as an alternative for vascular access in hemodialysis. *Rev Med Chil* 1988;116:49-51
- Ono K, Muto Y, Yano K, Yukizane T. Anterior chest wall axillary artery to contralateral axillary vein graft for vascular access in hemodialysis. *Artif Organs* 1995;19:1233-1236
- Debing E, Van den Brande P. Axillo-axillary arteriovenous fistula as a suitable surgical alternative for chronic haemodialysis access. *Nephrol Dial Transplant* 1999;4:1252-1253
- McCann RL. Axillary grafts for difficult hemodialysis access. *J Vasc Surg* 1996;24:457-461
- Maya ID, Oser R, Saddekni S, Barker J, Allon M. Vascular access stenosis: comparison of arteriovenous grafts and fistulas. *Am J Kidney Dis* 2004;44:859-865
- Glanz S, Gordon DH, Lipkowitz GS, Butt KM, Hong J, Sclafani SJ. Axillary and subclavian vein stenosis: percutaneous angioplasty. *Radiology* 1988;168:371-373
- Saeed M, Newman GE, McCann RL, Sussman SK, Braun SD, Dunnick NR. Stenoses in dialysis fistulas: treatment with percutaneous angioplasty. *Radiology* 1987;164:693-697
- Levit RD, Cohen RM, Kwak A, Shlansky-Goldberg RD, Clark TW, Patel AA, et al. Asymptomatic central venous stenosis in hemodialysis patients. *Radiology* 2006;238:1051-1056
- Kanterman RY, Vesely TM, Pilgram TK, Guy BW, Windus DW, Picus D. Dialysis access grafts: anatomic location of venous stenosis and results of angioplasty. *Radiology* 1995;195:135-139
- Sreenarasimhaiah VP, Margassery SK, Martin KJ, Bander SJ. Salvage of thrombosed dialysis access grafts with venous anastomosis stents. *Kidney Int* 2005;67:678-684
- Turmel-Rodrigues LA, Blanchard D, Pengloan J, Sapoval M, Baudin S, Testou D, et al. Wallstents and Craggstents in hemodialysis grafts and fistulas: results for selective indications. *J Vasc Interv Radiol* 1997;8:975-982
- Zaleski GX, Funaki B, Rosenblum J, Theoharis J, Leef J. Metallic stents deployed in synthetic arteriovenous hemodialysis grafts. *AJR Am J Roentgenol* 2001;176:1515-1519
- Patel RI, Peck SH, Cooper SG, Epstein DM, Sofocleous CT, Schur I, et al. Patency of Wallstents placed across the venous anastomosis of hemodialysis grafts after percutaneous recanalization. *Radiology* 1998;209:365-370
- Liang HL, Pan HB, Lin YH, Chen CY, Chung HM, Wu TH, et al. Metallic stent placement in hemodialysis graft patients after insufficient balloon dilation. *Korean J Radiol* 2006;7:118-124