

Aggressive differentiated thyroid cancer with multiple metastases and NRAS and TERT promoter mutations: A case report

FABIANA PANI¹, ELISABETTA MACEROLA², FULVIO BASOLO²,
FRANCESCO BOI¹, MARIO SCARTOZZI³ and STEFANO MARIOTTI¹

¹Endocrinology Unit, Department of Medical Sciences 'M. Aresu', University of Cagliari and University Hospital of Cagliari, I-09042 Cagliari; ²Department of Surgical, Medical, Molecular Pathology and Critical Area, University of Pisa and University Hospital of Santa Chiara, Pisa I-56126; ³Medical Oncology Unit, Department of Medical Sciences 'M. Aresu', University Hospital of Cagliari and University of Cagliari, I-09042 Cagliari, Italy

Received July 4, 2016; Accepted January 26, 2017

DOI: 10.3892/ol.2017.6395

Abstract. Sorafenib, a tyrosine kinase inhibitor, is approved for the treatment of advanced differentiated thyroid carcinoma (DTC). Resistance to sorafenib may appear under treatment and may be associated with increased aggressiveness of the neoplasia. The present study reports the case of a 65-year-old male who underwent total thyroidectomy for a follicular thyroid carcinoma, Hürthle cell variant, in February 2005. Until January 2010, the patient received four consecutive ¹³¹I doses (total dose, 612 mCi) for increased serum thyroglobulin (Tg) and initial faint lung uptake (which eventually became undetectable). Subsequently, the patient developed several sequential bone (humerus, rib and skull), adrenal and lung metastases, the majority of which were surgically removed. Histological examination in all cases revealed evidence of DTC metastases that were strongly positive for Tg, as revealed by immunohistochemistry. In March 2014, sorafenib therapy was initiated, but it was discontinued 10 months later to allow an undelayable prostatectomy. Immediately upon surgery, the patient developed a large metastatic lesion in the right gluteal muscle, whose biopsy revealed undifferentiated neoplasia of epithelial origin, and the patient succumbed shortly afterwards. An extensive comparative search for biochemical and molecular markers was performed on all available tissues (primary tumor, and differentiated and undifferentiated metastases). The primary tumor and all the available metastases exhibited the same molecular oncogenic markers (namely, the RAS mutation p.Q61R and the telomerase promoter mutation C228T). In addition, the undifferentiated metastasis

exhibited a p53 mutation. The present study reports a case of a sudden acceleration of DTC metastatic progression following sorafenib discontinuation, which could have been due to the emergence of sorafenib-resistant undifferentiated p53-positive tumor cell clones.

Introduction

Differentiated thyroid carcinoma (DTC) constitutes ~95% of thyroid carcinomas and generally is associated with a favorable long-term survival; however, the prognosis is worse for patients developing distant metastases (DMs) (1,2). Radioactive iodine (RAI) therapy is the main treatment modality for DMs with ¹³¹I uptake, but 2/3 of patients with metastatic DTC become RAI refractory (3). In the majority of cases, progression is likely to occur in metastases without radioactive iodine uptake (in particular when ¹⁸F-FDG uptake is present) and RAI treatment will not be beneficial (3). Additional therapy involves external radiation, surgery or other local ablative procedures (4). Systemic therapies with the tyrosine kinase inhibitors (TKIs) sorafenib and lenvatinib have been recently approved (2-5). Sorafenib (Nexavar[®]), was the first drug employed in RAI-refractory DTC, and its inhibitory effect has been explored in an international, multicentric, phase 3 study (DECISION trial) (5). The present study demonstrates that the progression-free survival (PFS) of naïve patients receiving this drug was longer compared with the placebo group (10.8 vs. 5.8 months; P<0.0001). The positive results in terms of the safety and efficacy of sorafenib allowed for the approval of this drug by the FDA in 2013, and by the EMA in 2014. In addition, another TKI drug (lenvatinib, Lenvima[®]), was investigated for the treatment of RAI-refractory DTC, and the results were published in a phase 3, multicenter randomized, placebo controlled study (SELECT trial) (6). In the SELECT trial, PFS was longer in naïve and second line patients treated with lenvatinib than compared with the placebo group. Although TKIs are promising in the treatment of RAI-refractory DTC, the main limitation of them is the fact that following a variable period of time from the beginning of treatment, an indefinite number of cancer cells begin to grow again, possibly due to the development of an escape mechanism (7).

Correspondence to: Dr Fabiana Pani, Endocrinology Unit, Department of Medical Sciences 'M. Aresu', University of Cagliari and University Hospital of Cagliari, Strada Statale 554-bivio Sestu, Monserrato, I-09042 Cagliari, Italy
E-mail: panifabiana@libero.it

Key words: sorafenib, thyroid cancer, molecular biology, oncogenes, metastases

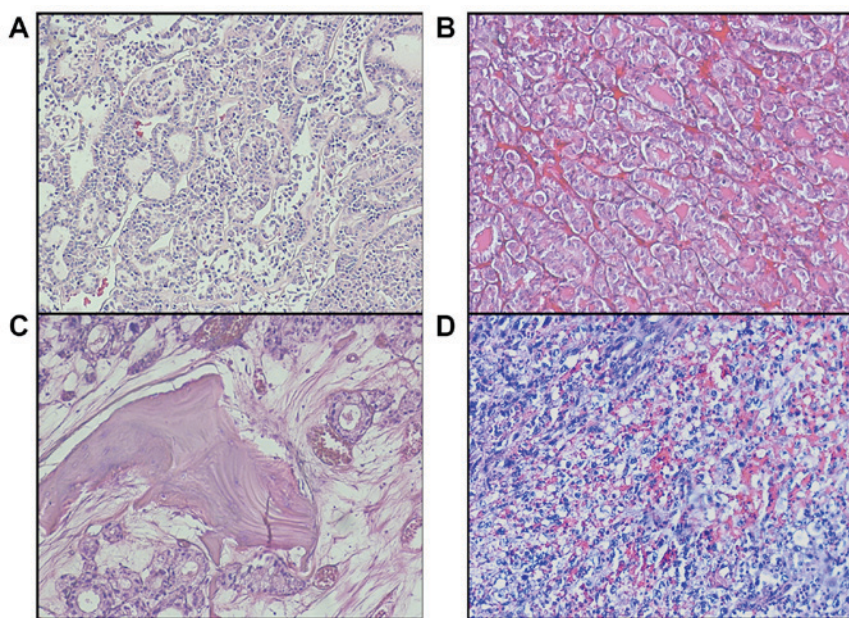


Figure 1. Representative histological images of metastases. (A) Primary thyroid tumor, (B) adrenal metastasis, (C) cranial metastasis, (D) right gluteus metastasis. Hematoxylin and eosin staining, magnification, x100.

Case report

A 65-year-old male underwent total thyroidectomy (TT) for pre-toxic multinodular goiter in February 2005. Histological examination revealed a 4-cm follicular thyroid carcinoma (FTC), Hürthle cell variant, with capsular invasion and vascular emboli (Fig. 1A). During the subsequent 5 years, the patient received four ^{131}I administrations (cumulative dose, 612 mCi) for increasing serum thyroglobulin (Tg) levels (from 9 to 144 ng/ml) on fully suppressive L-thyroxine therapy and faint lung uptake at ^{131}I whole body scan (WBS), in the absence of any radiological [computed tomography (CT)] evidence of lung metastases. Bone scintigraphy was negative 3 years after TT. No relevant RAI uptake was detected at WBS performed following the last RAI dose (200 mCi), which was administered 5 years after TT, despite the further increase in serum Tg levels (≥ 800 ng/ml) obtained with fully suppressed TSH. At that time, a new bone scintigraphy detected an osteolytic lesion in the left humerus neck, which was treated by embolization, electrochemotherapy and partial resection. Histology confirmed an FTC (metastatic lesion) which was strongly positive for Tg at immunohistochemistry (Tg $^{++}$). Nine months later, a chest CT revealed a new osteolytic lesion at the fifth left rib, which was surgically removed in October 2011. Histology confirmed a Tg $^{++}$ FTC (metastatic lesion). In 2012, an infusion cyclic-therapy with zoledronic acid (Zometa $^{\text{®}}$, 4 mg at monthly intervals) was performed for 12 months. In April 2013, positron emission tomography (PET)/CT displayed a skull bone lesion, which was confirmed by total body CT (TBCT). TBCT also demonstrated a synchronous PET-negative adrenal left metastasis. Both lesions were surgically resected and were histologically confirmed to be FTC metastases expressing Tg and thyroid transcription factor 1 (TTF1). (Fig. 1B and C). A further TBCT performed 6 months later documented progression of bone metastatic lesions and new appearance of lung metastases. According to the Response

Evaluation Criteria In Solid Tumors (8), in March 2014, the patient started a first-line treatment with sorafenib (2,4) with a full daily oral dose of 800 mg. At that time, the patient was asymptomatic and in good general condition, but one month later, the patient developed a severe hand-foot skin reaction, requiring reduction of sorafenib to 400 mg/day. Six months after the initiation of the therapy, a new TBCT demonstrated stable disease, although the progressive increase in serum Tg levels suggested biochemical progression.

Four months later, sorafenib was stopped to allow urgent prostatectomy for acute urinary retention due to prostatic hyperplasia. Three days after the surgery, the patient suddenly reported an intense pain in the sacral region, and a TBCT performed two weeks later identified a markedly large (9 cm) necrotic right gluteus muscle lesion, alongside the appearance of additional lung metastatic lesions. A review of the TBCT scan performed four months earlier confirmed the absence at the time of any detectable mass in the gluteus. Since the precise nature of the gluteal lesion was unclear, a diagnostic biopsy was performed. Histology (Fig. 1D) revealed an extensively necrotic undifferentiated neoplasia, with rhabdoid aspects, Tg negativity at immunohistochemistry, and positivity for cytokeratin 7, Ki-67 (40%) and TTF1 (Fig. 2A-D). All immunohistochemistry assays have been performed using the same platform (Ventana Medical Systems, Inc., Tucson, AZ, -USA); all antibodies were ready-to-use: Thyroglobulin, mouse monoclonal antibody-clone 2H11+6E1 (cat. no., 760-2671); TTF1, mouse monoclonal antibody, clone 8G7G3/1 (cat. no., 790-4462); Ki-67, rabbit monoclonal antibody, clone 30-9 (cat. no., 760-2542) (Ventana Medical Systems, Inc.). Two weeks after the biopsy, the clinical conditions rapidly worsened. Thus, the patient was admitted to a local hospital for severe anemia and succumbed few hours later.

The patient had signed an informed consent form stating that all the clinical examinations required for an accurate diagnosis could be performed. The ethics committee or head

Table I. Comparison of histological and immunohistochemical features of the primary neoplasia and metastatic lesions.

Lesion site	Surgical removal date	Histology	Immunohistochemistry				Serum Tg (ng/ml)	
			TTF1	CK7	Ki67 (%)	Prior to surgery	Following surgery	
Thyroid gland	Feb 2005	Differentiated	++	++	ND	ND	ND	9
Humerus	Aug 2010	Differentiated	++	ND	ND	ND	800	144
Rib	Oct 2011	Differentiated	++	ND	ND	ND	672	31
Skull	May 2013	Differentiated	++	ND	ND	ND	168	159
Adrenal gland	July 2013	Differentiated	++	++	ND	ND	168	159
Gluteus	Feb 2015	Undifferentiated	+	++	++	++	1,484	1,784

Feb, February; Aug, August; Oct, October; Tg, Thyroglobulin; TTF1, Thyroid transcription factor 1; CK, cytokeratin; ND, not determined.

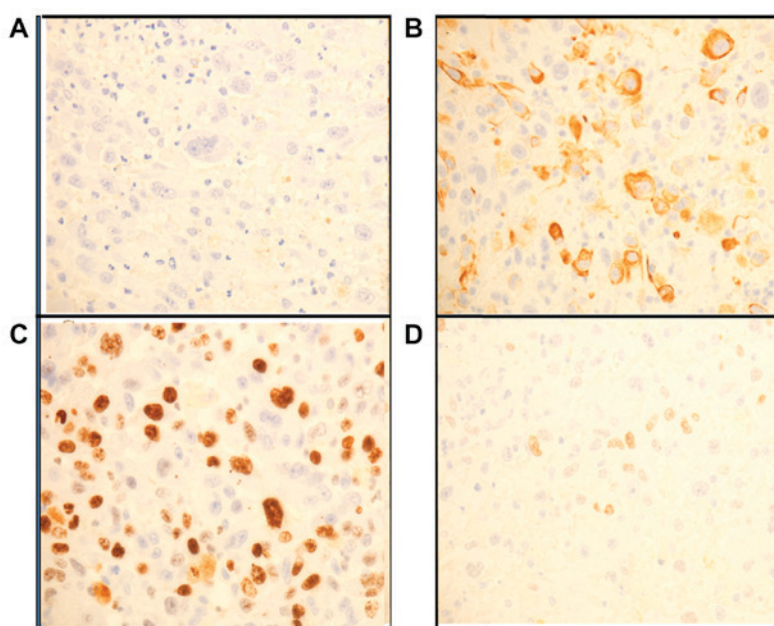


Figure 2. Images of (A) thyroglobulin (-), (B) cyokeratin 7 (++), (C) Ki67 (40%), and (D) thyroid transcription factor 1 (++) immunohistochemical stains of undifferentiated right gluteus metastasis. (A-C) Magnification, x100, (D) Magnification, x200.

of the University Hospital of Cagliari (Cagliari, Italy) reviewed and approved the study protocol. No autopsy was performed. The histological and immunohistochemical features of the primary tumor and all the available metastatic tissues, together with the serum Tg concentrations prior and subsequent to the removal of each metastatic lesion are reported in Table I.

Several oncogenes involved in thyroid tumorigenesis were evaluated in all the available tissues (Table II). All tumor samples were formalin fixed and paraffin embedded. For each case, the most representative paraffin block was selected, and three 10- μ m unstained sections were prepared for DNA purification. The DNA from the primary tumor and that from the adrenal and gluteal metastatic lesions were adequate for molecular analysis. However, bone-derived DNA is known to contain high levels of polymerase chain reaction (PCR) inhibitors (9). In consequence, the cranial metastatic lesion DNA resulted unsuitable for downstream analyses. An extensive molecular analysis was performed using a mass spectrometry

platform (MassARRAY System, Agena Bioscience, San Diego, CA, USA) and the Myriapod Colon Status kit (Diotech Pharmacogenetics SRL, Jesi, Italy), which allowed the identification of 216 cancer-associated hotspot mutations in the KRAS, BRAF, NRAS and phosphatidylinositol-4,5-bisphosphate 3-kinase, catalytic subunit alpha oncogenes. All lesions had the same point mutation in NRAS codon 61 (p.Q61R, c.182C>G), while a wildtype result was obtained for the other oncogenes. These data are in agreement with a previous study reporting that NRAS-mutant thyroid carcinoma exhibit a high risk with respect to develop bone metastases (10). Further molecular analyses were carried out by PCR, followed by direct Sanger sequencing (AbiPrism 3130 Genetic Analyzer, Applied Biosystem, Foster City, CA, USA) in order to assess the presence of mutations in the exons 4-9 of the p53 gene and in the promoter region of the telomerase (TERT) gene, which are known to be associated with clinicopathological features of aggressiveness in DTC (11). Sequencing of p53 was

Table II. Mutational status of oncogenes in primary tumor and metastatic lesions.

Tumor tissue	Oncogenes						
	BRAF	NRAS	KRAS	PIK3CA	TERT	p53	
						PCR	IHC
Thyroid (primary)	WT	p.Q61R	WT	WT	C228T	Unassessable	-
Adrenal gland (metastasis)	WT	p.Q61R	WT	WT	C228T	Unassessable	-
Skull (metastasis)	Ins	Ins	Ins	Ins	C228T	Unassessable	-
Gluteus (metastasis)	WT	p.Q61R	WT	WT	C228T	p.P72R, c.215C>G	++

TERT, telomerase; PIK3CA, phosphatidylinositol-4,5-biphosphate 3-kinase; catalytic subunit alpha; PCR, polymerase chain reaction; IHC, immunohistochemistry; WT, wild type; Ins, insufficient material.

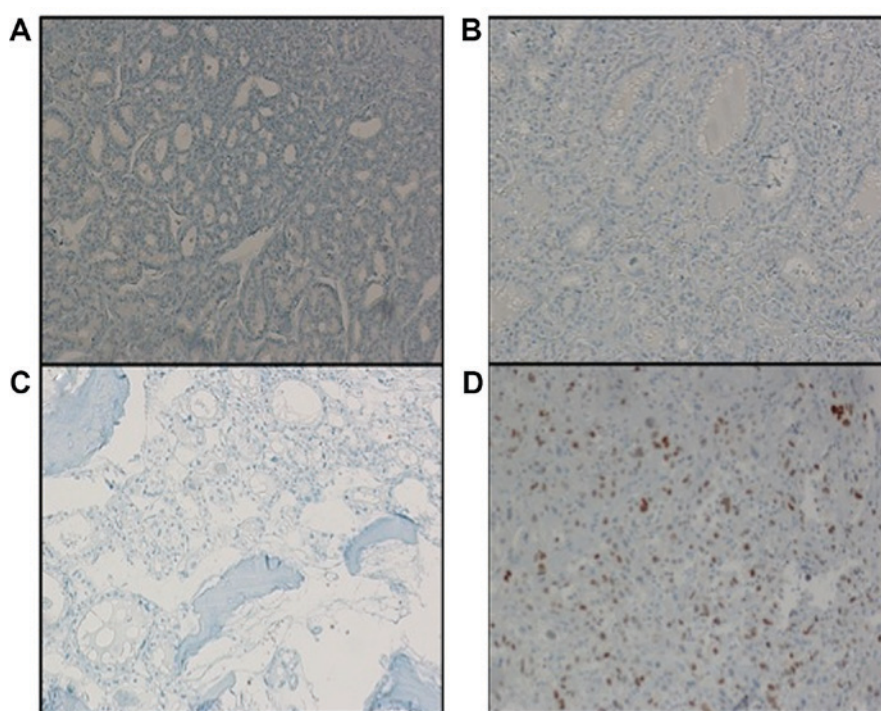


Figure 3. Images of p53 immunohistochemical stain. (A) Primary thyroid tumor, (B) adrenal metastasis, (C) cranial metastasis, (D) right gluteus metastasis. (A-D) Absence of p53 expression, magnification, x100.

carried out following the protocol provided by the IARC TP53 Mutation Database (available on the website: p53.iarc.fr), and analysis of TERT promoter was performed as described previously (12). The analysis revealed the presence of the C228T TERT promoter mutation in the primary thyroid tumor and in all other metastatic lesions samples. A p53 non-synonymous polymorphism was also identified in the undifferentiated gluteal metastatic lesion [p.P72R, c.215C>G (rs 1042522)], while no p53 amplification reaction was observed with the other samples (primary tumor and differentiated MLs), probably due to high DNA fragmentation and excessive amplicon length (13). Thus, p53 protein expression was assessed by immunohistochemistry [mouse monoclonal antibody, clone Bp53-11 (cat. no., 760-2542)] and only the gluteal undifferentiated metastatic lesion resulted positive for p53 (Fig. 3A-D).

Discussion

Sudden rapid progression of tumors subsequent to sorafenib discontinuation (known as ‘flare-up’) is considered to be a rather common event, but it has been reported only in a limited number of patients with solid tumors, including a single case of papillary thyroid carcinoma (14-16). The mechanisms involved in this phenomenon are unknown, although the emergence of aggressive clones responsive to TKI and a vascular rebound following the withdrawal of angiogenesis inhibition are the most probable explanations (14).

The present case report provides a detailed description of a flare-up phenomenon observed in a patient with metastatic FTC few days following the interruption of sorafenib administration. The availability of formalin-embedded specimens

from the primary tumor and several metastases allowed the morphological, biochemical and molecular comparative analyses of all tissues. The primary tumor displayed double oncogenic mutations (RAS and TERT promoter), which are known to be associated with aggressive behavior (11,12). Accordingly, the patient developed in the last 5 years of life a large number of metastases (bone, adrenal and lung metastases), which remained well differentiated with a rather slow disease progression. The same two mutations were detected in all the MLs available for analysis, including the undifferentiated gluteal metastases, thus confirming the common origin of both differentiated and undifferentiated MLs. A p53 non-synonymous polymorphism was clearly detectable by Sanger sequencing in the undifferentiated lesion, but no conclusive data were obtained in the primary tumor or in the other metastatic lesions, probably due to high DNA fragmentation and PCR failure. However, immunohistochemical analysis of p53 protein expression indicated that p53 was strongly expressed only in the undifferentiated metastasis. Although the above mutations are typical of different DTC histotypes, the peculiarity of the present case is represented by the documentation of a chronological sequence of the oncogenic mutations from the primary tumor to the last undifferentiated metastasis. Taken together, the present findings suggest that, in the current case, the main pathogenic explanation was the rapid proliferation of p53-mutated neoplastic clones whose growth was previously controlled by sorafenib, which retrospectively appeared to be effective in the patient.

In conclusion, the present case confirms that remarkable flare-ups should be always considered prior to sorafenib withdrawal in all patients with metastatic tumors. In addition, the present case offered a unique opportunity to document the 'molecular history' of an aggressive form of FTC, from the primary tumor to the last undifferentiated metastasis.

Acknowledgements

The authors sincerely thank Dr Antonio Maccioni (Surgical Pathology SS Trinità Hospital Cagliari, Italy), Dr Giuseppe Salvatore Porcu (Surgical Pathology, Businco Hospital, Cagliari) and Dr Giuseppe Bianchi (Surgical Pathology, Rizzoli Bologna Hospital, Bologna, Italy) for providing paraffin-embedded tissue samples of the surgically removed primary tumor and metastatic lesions.

References

- DeGroot LJ, Kaplan EL, McCormick M and Straus FH: Natural history, treatment, and course of papillary thyroid carcinoma. *J Clin Endocrinol Metab* 71: 414-424, 1990.
- Haugen BR, Alexander EK, Bible KC, Doherty GM, Mandel SJ, Nikiforov YE, Pacini F, Randolph GW, Sawka AM, Schlumberger M, *et al*: American thyroid association management guidelines for adult patients with thyroid nodules and differentiated thyroid cancer: The American Thyroid Association Guidelines Task Force on Thyroid Nodules and Differentiated Thyroid Cancer. *Thyroid* 26: 1-133, 2016.
- Durante C, Haddy N, Baudin E, Leboulleux S, Harti D, Travagli JP, Caillou B, Ricard M, Lumbroso JD, De Vathaire F and Schlumberger M: Long-term outcome of 444 patients with distant metastases from papillary and follicular thyroid carcinoma: Benefits and limits of radioiodine therapy. *J Clin Endocrinol Metab* 91: 2892-2899, 2006.
- Smit JW, Vielvoje GJ and Goslings BM: Embolization for vertebral metastases of follicular thyroid carcinoma. *J Clin Endocrinol Metab* 85: 989-994, 2000.
- Brose MS, Nutting CM, Jarzab B, Elisei R, Siena S, Bastholt L, de la Fouchardiere C, Pacini F, Paschke R, Shong YK, *et al*: Sorafenib in radioactive iodine-refractory, locally advanced or metastatic differentiated thyroid cancer: A randomised, double-blind, phase 3 trial. *Lancet* 384: 319-328, 2014.
- Schlumberger M, Tahara M, Wirth LJ, Robinson B, Brose MS, Elisei R, Habra MA, Newbold K, Shah MH, Hoff AO, *et al*: Lenvatinib versus placebo in radioiodine-refractory thyroid cancer. *N Engl J Med* 372: 621-630, 2015.
- Wang S, Pashtan I, Tsutsumi S, Xu W and Neckers L: Cancer cells harboring MET gene amplification activate alternative signaling pathways to escape MET inhibition but remain sensitive to Hsp90 inhibitors. *Cell Cycle* 8: 2050-2056, 2009.
- Ruan M, Shen Y, Chen L and Li M: RECIST 1.1 and serum thyroglobulin measurements in the evaluation of responses to sorafenib in patients with radioactive iodine-refractory differentiated thyroid carcinoma. *Oncol Lett* 6: 480-486, 2013.
- Eilert KD and Foran DR: Polymerase resistance to polymerase chain reaction inhibitors in bone. *J Forensic Sci* 54: 1001-1007, 2009.
- Basolo F, Pisaturo E, Pollina LE, Fontanini G, Elisei R, Molinaro E, Iaconi P, Miccoli P and Pacini F: N-ras mutation in poorly differentiated thyroid carcinomas: Correlation with bone metastases and inverse correlation to thyroglobulin expression. *Thyroid* 10: 19-23, 2000.
- Melo M, da Rocha AG, Vinagre J, Batista R, Peixoto J, Tavares C, Celestino R, Almeida A, Salgado C, Eloy C, *et al*: TERT promoter mutations are a major indicator of poor outcome in differentiated thyroid carcinoma. *J Clin Endocrinol Metab* 99: E754-E765, 2014.
- Landa I, Ganly I, Chan TA, Mitsutake N, Matsuse M, Ibrahimagic T, Ghossein RA and Fagin JA: Frequent somatic TERT promoter mutations in thyroid cancer: Higher prevalence in advanced forms of the disease. *J Clin Endocrinol Metab* 9: E1562-E1566, 2013.
- Dobashi Y, Sugimura H, Sakamoto A, Mernyei M, Mori M, Oyama T and Machinami R: Stepwise participation of p53 gene mutation during dedifferentiation of human thyroid carcinomas. *Diagn Mol Pathol* 3: 9-14, 1994.
- Wolter P, Beuselinck B, Pans S and Schöffski P: Flare-up: An often unreported phenomenon nevertheless familiar to oncologists prescribing tyrosine kinase inhibitors. *Acta Oncol* 48: 621-624, 2009.
- Desar IM, Mulder SF, Stillebroer AB, van Spronsen DJ, van der Graaf WT, Mulders PF and van Herpen CM: The reverse side of the victory: Flare up of symptoms after discontinuation of sunitinib or sorafenib in renal cell cancer patients. A report of three cases. *Acta Oncol* 48: 927-931, 2009.
- Yun KJ, Kim W, Kim EH, Kim MH, Lim DJ, Kang MI and Cha BY: Accelerated disease progression after discontinuation of sorafenib in a patient with metastatic papillary thyroid cancer. *Endocrinol Metab (Seoul)* 29: 388-393, 2014.