


Erlotinib as a salvage treatment after gefitinib failure for advanced non-small-cell lung cancer patients with brain metastasis

A successful case report and review

Yong Dong, MD^a, Qijun Li, MD^a, Qian Miao, B.D^b, Da Li, MD, PhD^{a,*}

Abstract

Rationale: The guidelines recommended gefitinib as a first-line targeted treatment for stage IV non-small-cell lung cancer (NSCLC) patients with EGFR mutations. However, resistance to gefitinib ensues invariably and there is little evidence as for the effectiveness of subsequent salvage treatment for patients without T790m mutation. The case is to evaluate the efficacy of erlotinib, another EGFR-TKI, after failed first-line use of gefitinib.

Patient concerns: We described a 55-year-old man with good performance status (PS).

Diagnoses: He was histopathologically diagnosed stage IV lung adenocarcinoma with EGFR mutations in November 2018.

Interventions: He was administrated with gefitinib daily (250 mg) for activating epidermal growth factor receptor (EGFR) mutations (exon 19 deletions, 19del), and combined with platinum-based dual-drug chemotherapy. During the target treatments, the optimal efficacy evaluation was partial remission (PR) with a 12-month progression-free survival (PFS) time. Later, the intracranial progression of the patient rendered the treatment change to erlotinib.

Outcomes: It is surprising that the tumor lesion in brain as well as lung relieved obviously. His progression-free survival (PFS) was nearly 11 months, and the overall survival (OS) was >36 months up to now. The adverse events were tolerable.

Lessons: This case manifests that re-biopsy of advanced or recurrent NSCLC is beneficial to make a better therapeutic regimen, and erlotinib can be used as a salvage treatment after gefitinib failure.

Abbreviations: AEs = adverse events, CNS = central nervous system, CR = complete remission, CT = computed tomography, EGFR-TKI = epidermal growth factor receptor-tyrosine kinase inhibitor, ICIs = immune checkpoint inhibitors, IMRT = intensity modulated radiation therapy, MET = mesenchymal epithelial transformation, MRI = magnetic resonance imaging, MTD = maximum tolerated dose, NGS = next Generation Sequencing, NSCLC = non-small cell lung cancer, OS = overall survival, PD = progressive disease, PFS = progression-free survival, PR = partial response, RECIST 1.1 = response evaluation criteria in solid tumors version 1.1, VAFs = variant allele frequencies, VEGF = vascular endothelial growth factor.

Keywords: case report, erlotinib, gefitinib, non-small-cell lung cancer (NSCLC), salvage treatment

Editor: Maya Saranathan.

The authors have no funding and conflicts of interest to disclose.

Ethical Approval: Not applicable.

Consent for publication: Written informed consent was obtained from the patient for publication of the case details and accompanying images.

Statement of Informed Consent: Written informed consent was obtained from the patient for publication of this case report and any accompanying images.

All data generated or analyzed during this study are included in this published article [and its supplementary information files].

^a Department of Medical Oncology, Sir Run Run Shaw Hospital, College of Medicine, Zhejiang University, Hangzhou, ^b Department of Medical Oncology, Quzhou People's Hospital, Zhongludi, Quzhou, Zhejiang, China.

* Correspondence: Da Li, Department of Medical Oncology, Sir Run Run Shaw Hospital, College of Medicine, Zhejiang University, No.3 Qingchun East Road, Jianggan District, Hangzhou, Zhejiang, 310016, China (e-mail: lidaonconew@zju.edu.cn).

Copyright © 2021 the Author(s). Published by Wolters Kluwer Health, Inc.

This is an open access article distributed under the Creative Commons Attribution License 4.0 (CCBY), which permits unrestricted use, distribution, and reproduction in any medium, provided the original work is properly cited.

How to cite this article: Dong Y, Li Q, Miao Q, Li D. Erlotinib as a salvage treatment after gefitinib failure for advanced non-small-cell lung cancer patients with brain metastasis: A successful case report and review. *Medicine* 2021;100:25(e26450).

Received: 13 April 2021 / Received in final form: 29 May 2021 / Accepted: 7 June 2021

<http://dx.doi.org/10.1097/MD.00000000000026450>

1. Introduction

Lung cancer is the most common cause of tumor associated death mortalities with the highest incidence.^[1] Generally speaking, the development of drugs and mechanism researches of drug resistances were always discovered firstly in lung cancer, and then gradually expanding application to other cancers. Although immunotherapy has developed rapidly and become an efficient treatment for many cancers, such as non-small cell lung cancer (NSCLC), malignant melanoma and other cancers,^[2,3] as treatments with more mature researches, chemotherapy and targeted treatments still play important roles in the oncotherapy. Epidermal growth factor receptor-tyrosine kinase inhibitor (EGFR-TKI) is a significant milestone in drug therapy, which is widely used in patients of NSCLC with constantly more accurate indications. Nowadays, EGFR-TKI has been administered as a first-line treatment for NSCLC in stage IV with EGFR mutations, and it demonstrates a better efficacy compared to traditional chemotherapy in the selected patients.^[4,5] Drugs are rapidly updated, in terms of EGFR-TKI, includes the first generation of gefitinib, erlotinib and icotinib, the second generation of afatinib, dacomitinib and the third generation of osimertinib. However, most tumors inevitably develop acquired resistance to EGFR TKIs over time, which limits the benefits of patients and makes patients eventually undergo disease progression.^[6,7] How to make rational administration of drug therapy, such as the combination of drugs to reduce the occurrence of drug resistance, the indication of continuing the original TKI or dressing change treatments after drug resistance, is our grand challenges in tumor therapy. The correct strategy of EGFR-TKI treatments can maximize the survival time of patients, while the implicit mechanism of EGFR-TKI resistance is the major obstacle which need a plenty of case reports and clinical trials to illustrate and point out the research direction. This paper reports a patient of primary lung adenocarcinoma with brain metastasis who developed drug resistance after first-line gefitinib combined with chemotherapy, and erlotinib succeeded in complete remission of intracranial lesions and partial remission of pulmonary lesions as the second-line treatment. In the meanwhile, we expounded the phenomenon of no cross-drug resistance among the first generation of EGFR-TKI and related clinical problems in the treatments of lung cancer complicating with brain metastasis.

2. Case presentation

A 55-year-old man without the history of smoking or related pulmonary diseases previously was presented to hospital for coughing with sputum, chest distress and breathless in November 2018. Computed tomography (CT) scans showed a lung mass of the lower left lobe, and brain magnetic resonance imaging (MRI) revealed brain metastases in left frontal lobe and insula (Figure 1). Percutaneous lung biopsy confirmed adenocarcinoma on November 19, 2018, and he was clinically diagnosed with stage IVa lung adenocarcinoma (cT1cN1M1b) with an EGFR 19del mutation, detected through the Next Generation Sequencing (NGS) platform. Variant allele frequencies (VAFs) of the detected EGFR 19del mutation were 19.6%. Gefitinib (250mg, once a day) was then administered from December 3, 2018. After one month of gefitinib treatment, chest CT scans on December 31st 2018 showed original lung mass was significantly reduced, and the brain metastases almost disappeared, which were evaluated partial remission (PR) and complete remission (CR) respectively according to the Response Evaluation Criteria in Solid Tumors

(RECISTv1.1) (Figure 1). During the treatment of gefitinib, the patients received PC (pemetrexed 1g and carboplatin 500mg) regimen for 6 cycles (from 2019-01 to 2019-06), and maintain with single pemetrexed (1g) chemotherapy for 5 cycles (from 2019-07 to 2019-11) in Shanghai Thoracic Hospital. Regular follow-up shows the therapeutic effects PR. Unfortunately, in December 3, 2016, a new craniocerebral metastasis was discovered by brain MRI. According to the CSCO guidelines, oligoprogression or only progression in central nervous system (CNS) of NSCLC with EGFR mutation in stage IV after drug resistance, the original EGFR-TKI and local treatment can be continued, and the mechanism of drug resistance can be confirmed by biopsy again. Therefore, the patient explored the genetic mutation through hematological tests for his unpuncturable lung lesion. He finally was administered with gefitinib continually with no EGFR mutation detected, combined with brain intensity modulated radiation therapy (IMRT) (DT 3000cGy/10F whole brain) from December 18, 2019 to December 31, 2019. The patient sustained the treatment of gefitinib until March 3, 2020, when brain MRI indicated that multiple metastases in brain were in explosive development, and chest computed tomography (CT) showed masses in lung were significantly larger than the baseline. The overall evaluation of the efficacy was progressive disease (PD), and it is recommended to change treatments after biopsy according to the guidelines. In our perspective, it takes time for obtaining the result of re-biopsy and NGS, and the huge tumor load and rapid progress in intracranial tumor made the waiting long and tough. Ultimately, targeted therapy of erlotinib (150mg once a day) was administered from March 20, 2020, and no bevacizumab combined with temporarily for biopsy preparation. On March 24, 2020, percutaneous lung biopsy under CT was performed. Pathology revealed lung adenocarcinoma and NGS identified the molecular profiling of c.2240_2254delp.L747_T751del (13.8%), TP53 (28.98%), MSS, PD-L1 (-) without T790M mutation. In the meanwhile, it was miraculously found that brain MRI on April 22, 2020 indicated a PR status in brain metastases. Therefore, the patient continued administering with erlotinib and was performed regular follow-ups thereafter. Up to March 31st, 2020, the intracranial and pulmonary metastases were almost evaluated as CR.

3. Discussion

The emergence of small molecular targeted drugs revolutionized the therapeutic strategies of NSCLC with positive driving genes. Although the first-generation EGFR TKIs is more effective than conventional chemotherapy in patients with EGFR mutations, the median progression-free survival (PFS) of most patients is about 1 year due to ubiquitously acquired drug resistance in targeted drugs.^[8] At present, the most common acquired resistance mechanisms of EGFR TKI have been explored out includes alternative pathway activation, such as epithelial mesenchymal transformation (EMT), mesenchymal epithelial transformation (MET) or ERBB2/HER2 amplification, tumor histological as well as phenotypic transformation, and especially target gene modification like T790M.^[9-11] With the development of NGS, more and more mutations related with drug resistance to EGFR TKIs have been revealed. In addition to the T790M mutation, which accounts for about 50% of the drug resistance mechanism,^[12] other rare drug-resistant mutations includes insertion mutations in the site of Pro772_His773insGlnCysPro

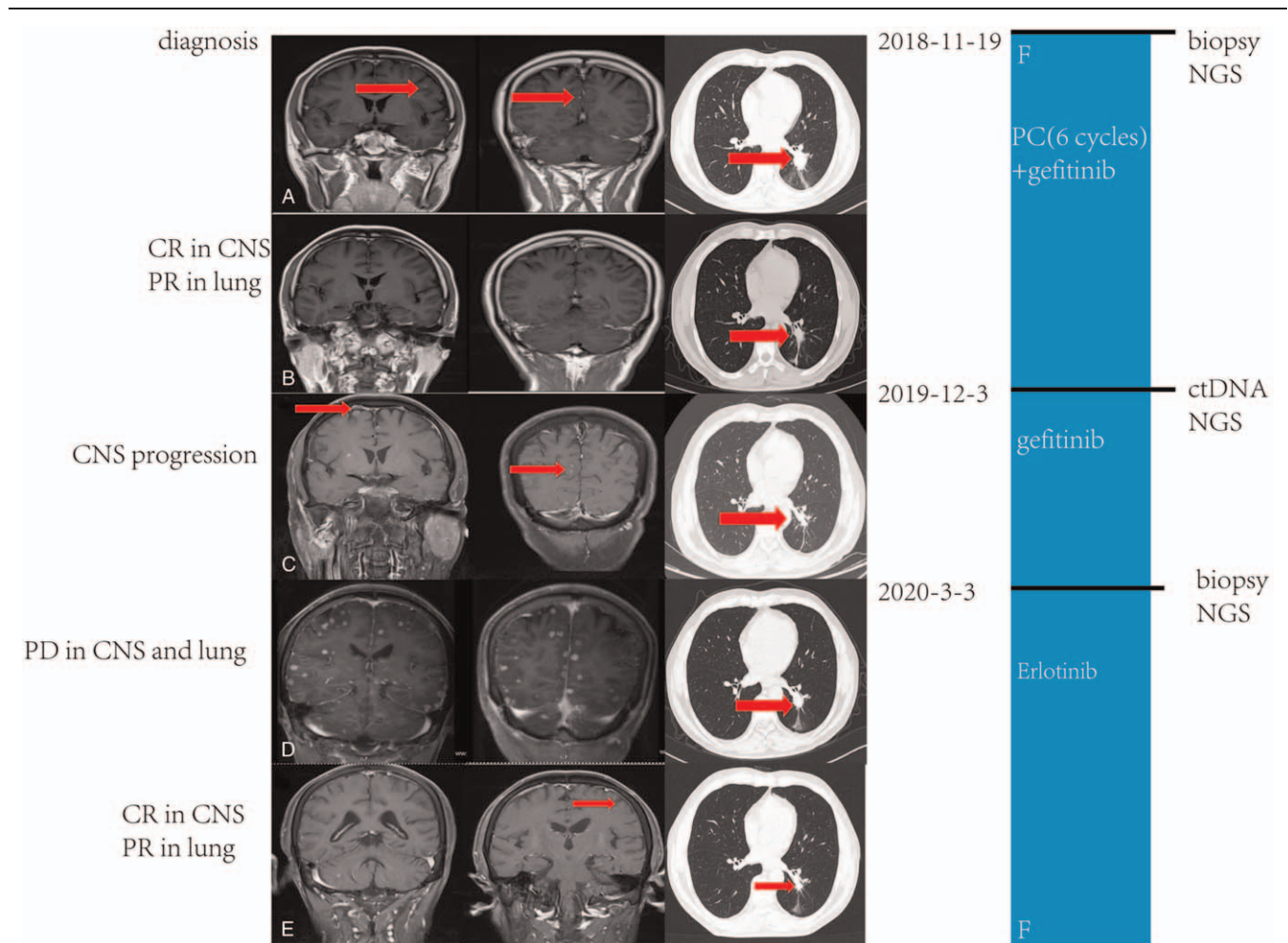


Figure 1. Timeline and effect of EGFR-TKI treatments. (A) Baseline images of CT and MRI at diagnosis; (B) Brain metastases complete remission (CR) and original lung mass partial response (PR) after six cycles of PC (pemetrexed 1 g and carboplatin 500 mg) and one year of gefitinib treatment; (C) Brain metastases progressed gefitinib treatment was administered; (D) Images of CT and MRI before erlotinib treatment; (E) Brain metastases CR and lung mass PR after erlotinib treatment was administered; (F) Treatment timeline; CNS = central nervous system; CT = computed tomography; EGFR, epithelial growth factor receptor; MRI = magnetic resonance imaging; PD = progressive disease; TKI = tyrosine kinase inhibitor.

in exon 20, which can lead to resistant to erlotinib,^[13] mutations of codon 719 and 709 in exon 18 often indicate resistance or low response to first-generation EGFR TKIs.^[14] Compared with other rare mutations, patients with T790M mutation tend to have a longer survival time for it is the only drug-resistant mutation which we have found a targeted drug.^[15] While the subsequent therapy after the first-generation EGFR TKIs resistant for patients without T790M mutation is still a problem difficult to overcome. In most instances, doctors will advise patients receive systematic chemotherapy, and there are also plenty of clinical studies on the combination of chemotherapy and immune checkpoint inhibitors (ICIs), or anti-vascular endothelial growth factor receptor (VEGFR) carried out. In fact, before the third-generation EGFR TKIs developed, a certain amount of small samples clinical studies abroad confirmed that after the failure of advanced NSCLC with gefitinib, erlotinib can achieve a good effect with 5–10% PR and 40–60% SD.^[16,17] Why there are different efficacy and cross-resistance spectrum among first-generation EGFR TKIs? What is the drug resistance mechanism? How to select the beneficiaries? On account of that NGS was not prevalent at that time, definite answers still remain to be solved.

According to the characteristics of disease progression, it can be divided into three subtypes, including oligoprogression, systemic progression and central nervous system (CNS) sanctuary progression,^[18] and based on the duration of disease control as well as clinical symptom, the diversity of EGFR-TKI failure could be categorized into three modes, including dramatic progression, gradual progression and local progression.^[19] In our case, there were two disease progression during the course of the treatments.

1. The patient was administered with gefitinib combined with chemotherapy as the first-line treatments, whose PFS reached 12 months, which was significantly shorter than the combined group of prospective randomized controlled trials NEJ009, whose median PFS reached 20.9 month.^[20] The baseline status complicated with brain metastasis may account for the reduced PFS, and the developed brain metastasis firstly came after gefitinib resistance confirmed our consideration. The research results of IMPRESS showed that there was no clinical benefit from the continuation of EGFR TKIs after the first-line EGFR TKIs resistant in advanced NSCLC patients with EGFR mutations, while in the subtypes with negative T790M

mutation, there was a tendency to benefit.^[21] Because the residual lesion in the lung was too small to be punctured, we performed a liquid biopsy and the result showed no T790M mutation. Combined with the slow and local CNS progression of the patient, we ultimately chose to continue the original TKI treatment plus craniocerebral local radiotherapy to control the disease progression.

2. The second progression of the patient was extensive and explosive progression in both brain and lung. Although we considered giving the patient a re-biopsy of the primary lung lesion to acquire a more precise treatment, the disease progressed fiercely, and the patient was administered with erlotinib while waiting for the results of genetic testing.

Fortunately, the patient had a good response under our treatment strategy.

During the course of treatments, we performed totally three times of genetic testing:

1. The genetic test of the punctured lung tissue in the initial state of disease indicated EGFR19 del, and we chose gefitinib for no osimertinib available in domestic market at that time, and the OS of the FIURA clinic trial hadn't been published.
2. We performed a fluid biopsy immediately after the disease progressed under the treatment of gefitinib. Fluid biopsy could avoid repeated biopsies and monitor the changes of clones in real time, which detected drug resistance mutations of EGFR TKIs early and reduce missed mutations due to tumor heterogeneity.^[22] However, plasma genotyping had a false negative rate of 30 percent,^[23] and ignored the resistance mediated by histological transformation.^[24] Therefore, patients whose fluid biopsies indicate negative drug resistance mutations still need further tumor biopsies to be combined with, which assisted in confirming the mechanism of drug resistance. However, in our case, it is worth noting that patient's local progression first to appear in CNS, and fluid biopsy became the only way to determine the cause of drug resistance for the limited biopsy technique of CNS in this case.^[25] Due to the existence of blood-brain barrier, secondary systemic drug resistance mutations were not the only explanation for CNS progression. Given that the difficulty of drug penetration into the CNS, tumor tissue may still remain sensitive to EGFR TKIs.^[26,27] No EGFR mutation was detected in the patient, and we consider that it may be a false negative situation for concentration of ctDNA in peripheral blood too low to be detected after treatments, who had to rely on tissue biopsy for confirming the resistance mechanism.
3. After the progression of the lung lesion, we had the opportunity to biopsy again. NGS of tumor tissues showed EGFR mutation again, without drug resistance mutation, and combined with a new mutation of TP53.

Up till now, there is no targeted drug aiming at TP53 mutation, and it is more commonly served as a predictive marker of best beneficiary population. Patients with EGFR mutations and wild-type TP53 benefit more from the combination treatments of EGFR-TKIs and bevacizumab,^[28] which may be related to the fact that TP53 mutations are a poor prognostic factor in patients with TKI and participate in primary drug resistance of EGFR-TKIs by small-cell lung cancer (SCLC) transformation.^[29–31] The detection of NGS during the treatments showed continuous change of EGFR mutation, which may be related to the dynamic

regulation of drug resistance phenotype. Some studies have shown that the emergence of drug resistance may be short and reversible, and EGFR-TKI holiday can make lung cancer cell lines regain the sensitivity to EGFR TKIs.^[32–34] However, stopping EGFR TKI treatment prematurely may lead to tumor regeneration or rapid progression.^[35,36] Therefore, it is often believed that when patients are assessed as oligoprogression according to RECIST, the best option is to continue the original TKI, delay the time of changing drugs, and overcome the small part of drug resistant subclones by combining with local therapy.^[37–39] As the first-generation of TKIs, both gefitinib and erlotinib had the same action mechanism through combining ATP binding site reversibly,^[40] but erlotinib had more survival benefits than gefitinib as first-line treatment.^[41] In terms of pharmacology, the standard dose of erlotinib is the maximum tolerated dose (MTD), while the standard dose of gefitinib is about one third of its MTD,^[42] let alone erlotinib has higher steady state concentration and bioavailability.^[43] Therefore, there should be clinical benefits from erlotinib after gefitinib resistance. However, some studies on erlotinib after gefitinib failure showed that the overall effective rate was less than 10%. Further exploration by stratifying indicated that groups previously benefited from gefitinib were more likely to benefit from erlotinib, especially in patients underwent gefitinib more than one year,^[44] which may be caused by the bias of better disease status and tumor stability in patients who can tolerate long-term treatment of gefitinib.^[44] In the meanwhile, the cross resistance with gefitinib caused by acquired EGFR T790M mutation or bypass oncogene MET amplification may also account for the failure of erlotinib after gefitinib resistance,^[45] especially in patients receiving EGFR TKIs lasting for more than 13 months, which is the independent factor of secondary T790M mutation.^[46] Therefore, the clinical benefit can be obtained by continuing the treatment of erlotinib after gefitinib failure without cross resistance. In patients without T790M mutation after first-line TKIs failure, OS of chemotherapy group was better than gefitinib combined with chemotherapy group. However, this study only demonstrated the comparison with original TKI, some studies suggest that switched gefitinib to erlotinib after gefitinib failure can get benefit. In this case, the patient had multiple brain metastasis as well as systemic progression, and the abundance of EGFR mutation was less than that before. However, the patient still got better clinical benefits under the treatment of erlotinib. Therefore, after the first-line of gefitinib resistance, in the case of oligoprogression in CNS without drug resistance mutations, it a better treatment to switch to erlotinib as soon as possible, for erlotinib's higher biological concentration and better permeability of the blood-brain barrier. And for NSCLC patients with leptomeningeal metastasis, it has been confirmed that erlotinib may improve their clinical outcome after initial failure of gefitinib and apatinib.^[47] We summarized the treatment process after gefitinib resistance and the characteristics of patients suitable for continuing EGFR-TKI treatment (Figure 2). Previous studies have shown that patients who has better performance status (PS) scores, a long-term response of (longer PFS) or washout period of chemotherapy between gefitinib and erlotinib, can benefit from erlotinib after gefitinib failure.^[48–50] Nowadays, with the widespread development of NGS, second biopsies to identify genetic status after gefitinib treatment make the beneficiaries of second-line erlotinib treatment found with more possibilities. We hanker for prospective randomized controlled trials to look for more evidence to support our inference.

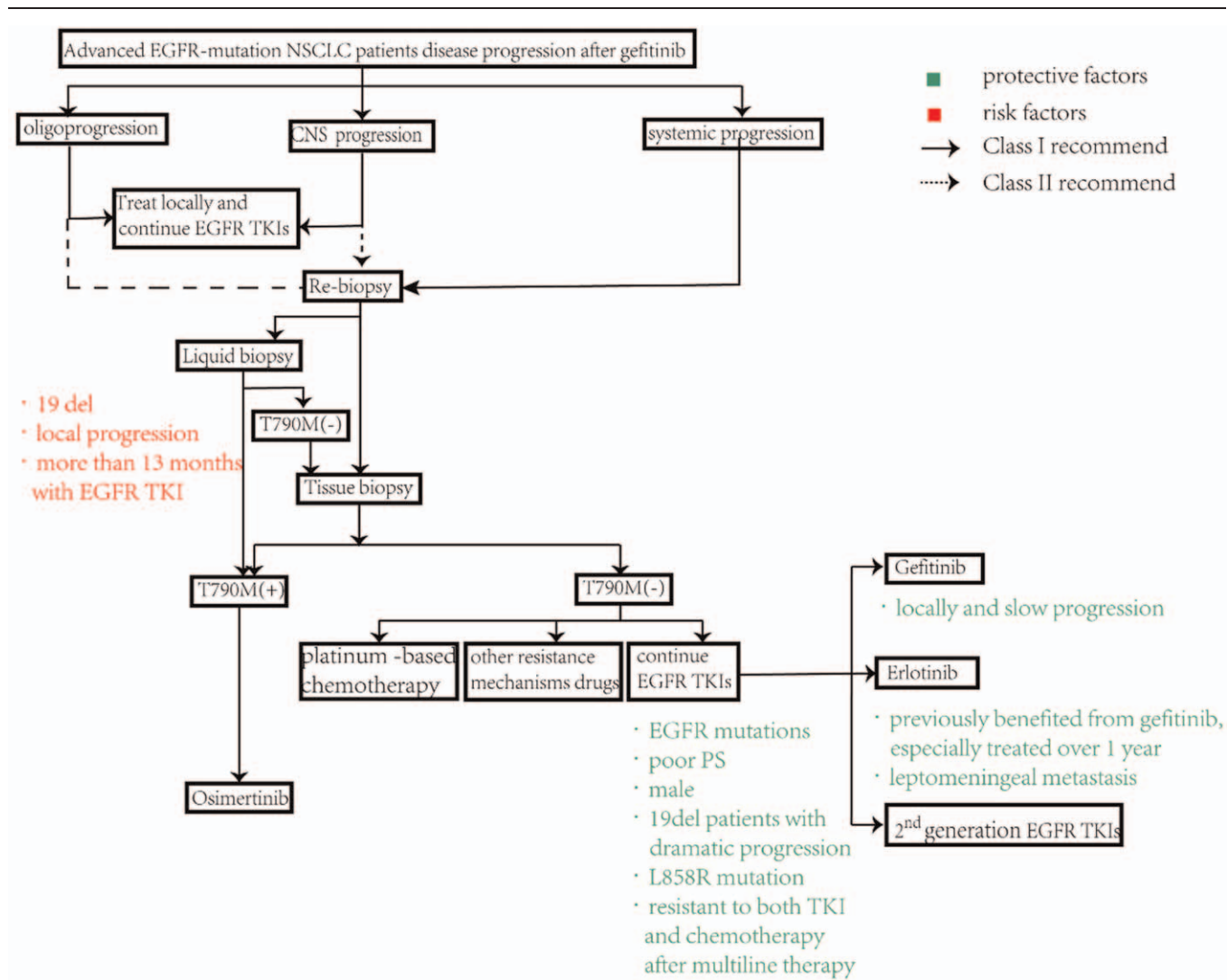


Figure 2. Treatment algorithm and influence factor for advanced EGFR-mutant NSCLC patients disease progression after gefitinib. CNS = central nervous system; PS = performance status.

4. Conclusion

Generally speaking, our case report suggested that when CNS progresses without drug resistance mutation indicated by NGS during the first-line use of gefitinib, switching to erlotinib as soon as possible may be a well treatment. In addition, it was also confirmed that repeated evaluation of drug-resistant mutations in the course of TKI treatment is indispensable, which provides ideas for stratifying the best beneficiary population of the TKI re-challenge.

Author contributions

Conceptualization: Da Li.
Data curation: Yong Dong.
Formal analysis: Yong Dong.
Investigation: Yong Dong.
Resources: Qijun Li.
Supervision: Qian Miao.
Writing – original draft: Yong Dong, Qian Miao, Qijun Li.
Writing – review & editing: Da Li.

References

- Bray F, Ferlay J, Soerjomataram I, Siegel RL, Torre LA, Jemal A. Global cancer statistics 2018: GLOBOCAN estimates of incidence and mortality worldwide for 36 cancers in 185 countries. *CA Cancer J Clin* 2018;68:394–424. doi: 10.3322/caac.21492. PubMed PMID: 30207593.
- Borghaei H, Paz-Ares L, Horn L, et al. Nivolumab versus docetaxel in advanced nonsquamous non-small-cell lung cancer. *N Engl J Med* 2015;373:1627–39. Epub 2015/09/29. doi: 10.1056/NEJMoa1507643. PubMed PMID: 26412456; PubMed Central PMCID: PMC45705936.
- Weber JS, D’Angelo SP, Minor D, et al. Nivolumab versus chemotherapy in patients with advanced melanoma who progressed after anti-CTLA-4 treatment (CheckMate 037): a randomised, controlled, open-label, phase 3 trial. *Lancet Oncol* 2015;16:375–84. Epub 2015/03/22. doi: 10.1016/S1470-2045(15)70076-8. PubMed PMID: 25795410.
- Maemondo M, Inoue A, Kobayashi K, et al. Gefitinib or chemotherapy for non-small-cell lung cancer with mutated EGFR. *N Engl J Med* 2010;362:2380–8. doi: 10.1056/NEJMoa0909530. PubMed PMID: 20573926.
- Zhou C, Wu Y, Chen G, et al. Erlotinib versus chemotherapy as first-line treatment for patients with advanced EGFR mutation-positive non-small-cell lung cancer (OPTIMAL, CTONG-0802): a multicentre, open-label, randomised, phase 3 study. *Lancet Oncol* 2011;12:735–42. doi: 10.1016/s1470-2045(11)70184-x. PubMed PMID: 21783417.

- [6] Jackman D, Pao W, Riely G, et al. Clinical definition of acquired resistance to epidermal growth factor receptor tyrosine kinase inhibitors in non-small-cell lung cancer. *J Clin Oncol* 2010;28:357–60. doi: 10.1200/jco.2009.24.7049. PubMed PMID: 19949011.
- [7] Tan C, Gilligan D, Pacey S, et al. Treatment approaches for EGFR-inhibitor-resistant patients with non-small-cell lung cancer. *Lancet Oncol* 2015;16:e447–59. doi: 10.1016/s1470-2045(15)00246-6. PubMed PMID: 26370354.
- [8] Kobayashi S, Boggon TJ, Dayaram T, et al. EGFR mutation and resistance of non-small-cell lung cancer to gefitinib. *N Engl J Med* 2005;352:786–92. Epub 2005/02/25. doi: 10.1056/NEJMoa044238. PubMed PMID: 15728811.
- [9] Wu S, Shih JJ, et al. Management of acquired resistance to EGFR TKI-targeted therapy in advanced non-small cell lung cancer. *Mol Cancer* 2018;17:38doi: 10.1186/s12943-018-0777-1. PubMed PMID: 29455650.
- [10] Takezawa K, Pirazzoli V, Arcila M, et al. HER2 amplification: a potential mechanism of acquired resistance to EGFR inhibition in EGFR-mutant lung cancers that lack the second-site EGFR T790M mutation. *Cancer Discov* 2012;2:922–33. doi: 10.1158/2159-8290.Cd-12-0108. PubMed PMID: 22956644.
- [11] Engelman J, Zejnullahu K, Mitsudomi T, et al. MET amplification leads to gefitinib resistance in lung cancer by activating ERBB3 signaling. *Science* 2007;316:1039–43. doi: 10.1126/science.1141478. PubMed PMID: 17463250.
- [12] Nguyen KS, Kobayashi S, Costa DB. Acquired resistance to epidermal growth factor receptor tyrosine kinase inhibitors in non-small-cell lung cancers dependent on the epidermal growth factor receptor pathway. *Clin Lung Cancer* 2009;10:281–9. Epub 2009/07/28. doi: 10.3816/CLC.2009.n.039. PubMed PMID: 19632948; PubMed Central PMCID: PMC2758558.
- [13] Khan NA, Mirshahidi S, Mirshahidi HR. A novel insertion mutation on exon 20 of epidermal growth factor receptor, conferring resistance to erlotinib. *Case Rep Oncol* 2014;7:491–6. Epub 2014/09/10. doi: 10.1159/000365325. PubMed PMID: 25202264; PubMed Central PMCID: PMC4154193.
- [14] Gristina V, Malapelle U, Galvano A, et al. The significance of epidermal growth factor receptor uncommon mutations in non-small cell lung cancer: a systematic review and critical appraisal. *Cancer Treat Rev* 2020;85:101994doi: 10.1016/j.ctrv.2020.101994. PubMed PMID: 32113081.
- [15] Oxnard G, Arcila M, Sima C, et al. Acquired resistance to EGFR tyrosine kinase inhibitors in EGFR-mutant lung cancer: distinct natural history of patients with tumors harboring the T790M mutation. *Clin Cancer Res* 2011;17:1616–22. doi: 10.1158/1078-0432.Ccr-10-2692. PubMed PMID: 21135146.
- [16] Lee D, Kim S, Suh C, et al. Phase II study of erlotinib as a salvage treatment for non-small-cell lung cancer patients after failure of gefitinib treatment. *Ann Oncol* 2008;19:2039–42. doi: 10.1093/annonc/mdn423. PubMed PMID: 18644828.
- [17] Singh N, Jindal A, Behera DJ, et al. Erlotinib usage after prior treatment with gefitinib in advanced non-small cell lung cancer: A clinical perspective and review of published literature. *World J Clin Oncol* 2014;5:858–64. doi: 10.5306/wjco.v5.i5.858. PubMed PMID: 25493223.
- [18] Gandara D, Li T, Lara P, et al. Acquired resistance to targeted therapies against oncogene-driven non-small-cell lung cancer: approach to subtyping progressive disease and clinical implications. *Clin Lung Cancer* 2014;15:1–6. doi: 10.1016/j.clc.2013.10.001. PubMed PMID: 24176733.
- [19] Yang J, Chen H, Yan H, et al. Clinical modes of EGFR tyrosine kinase inhibitor failure and subsequent management in advanced non-small cell lung cancer. *Lung Cancer* 2013;79:33–9. doi: 10.1016/j.lungcan.2012.09.016. PubMed PMID: 23079155.
- [20] Hosomi Y, Morita S, Sugawara S, et al. Gefitinib alone versus gefitinib plus chemotherapy for non-small-cell lung cancer with mutated epidermal growth factor receptor: NEJ009 study. *J Clin Oncol* 2020;38:115–23. doi: 10.1200/jco.19.01488. PubMed PMID: 31682542.
- [21] Mok T, Kim S, Wu Y, et al. Gefitinib plus chemotherapy versus chemotherapy in epidermal growth factor receptor mutation-positive non-small-cell lung cancer resistant to first-line gefitinib (IMPRESS): overall survival and biomarker analyses. *J Clin Oncol* 2017;35:4027–34. doi: 10.1200/jco.2017.73.9250. PubMed PMID: 28968167.
- [22] Sacher A, Paweletz C, Dahlberg S, et al. Prospective validation of rapid plasma genotyping for the detection of EGFR and KRAS mutations in advanced lung cancer. *JAMA Oncol* 2016;2:1014–22. doi: 10.1001/jamaoncol.2016.0173. PubMed PMID: 27055085.
- [23] Oxnard G, Thress K, Alden R, et al. Association between plasma genotyping and outcomes of treatment with osimertinib (AZD9291) in advanced non-small-cell lung cancer. *J Clin Oncol* 2016;34:3375–82. doi: 10.1200/jco.2016.66.7162. PubMed PMID: 27354477.
- [24] Westover D, Zugazagoitia J, Cho BC, Lovly CM, Paz-Ares L. Mechanisms of acquired resistance to first- and second-generation EGFR tyrosine kinase inhibitors. *Ann Oncol* 2018;29:110–9. Epub 2018/02/21. doi: 10.1093/annonc/mdx703. PubMed PMID: 29462254; PubMed Central PMCID: PMC6454547.
- [25] Jiang T, Ren S, Zhou C, et al. Role of circulating-tumor DNA analysis in non-small cell lung cancer. *Lung Cancer* 2015;90:128–34. doi: 10.1016/j.lungcan.2015.09.013. PubMed PMID: 26415994.
- [26] Song T, Yu W, Wu S-X. Subsequent treatment choices for patients with acquired resistance to EGFR-TKIs in non-small cell lung cancer: restore after a drug holiday or switch to another EGFR-TKI? *Asian Pac J Cancer Prev* 2014;15:205–13. doi: 10.7314/apjcp.2014.15.1.205. PubMed PMID: 24528028.
- [27] Jackman D, Holmes A, Lindeman N, et al. Response and resistance in a non-small-cell lung cancer patient with an epidermal growth factor receptor mutation and leptomeningeal metastases treated with high-dose gefitinib. *J Clin Oncol* 2006;24:4517–20. doi: 10.1200/jco.2006.06.6126. PubMed PMID: 16983123.
- [28] Cheng Y, Ma L, Liu Y, et al. Comprehensive characterization and clinical impact of concomitant genomic alterations in EGFR-mutant NSCLCs treated with EGFR kinase inhibitors. *Lung Cancer* 2020;145:63–70. doi: 10.1016/j.lungcan.2020.04.004. PubMed PMID: 32408134.
- [29] Hou H, Qin K, Liang Y, et al. Concurrent TP53 mutations predict poor outcomes of EGFR-TKI treatments in Chinese patients with advanced NSCLC. *Cancer Manag Res* 2019;11:5665–75. doi: 10.2147/cmar.S201513. PubMed PMID: 31417310.
- [30] Canale M, Petracchi E, Delmonte A, et al. Impact of TP53 mutations on outcome in EGFR-mutated patients treated with first-line tyrosine kinase inhibitors. *Clin Cancer Res* 2017;23:2195–202. Epub 2016/11/01. doi: 10.1158/1078-0432.CCR-16-0966. PubMed PMID: 27780855.
- [31] Lee J, Lee J, Kim S, et al. Clonal history and genetic predictors of transformation into small-cell carcinomas from lung adenocarcinomas. *J Clin Oncol* 2017;35:3065–74. doi: 10.1200/jco.2016.71.9096. PubMed PMID: 28498782.
- [32] Haven B, Heilig E, Donham C, et al. Registered report: a chromatin-mediated reversible drug-tolerant state in cancer cell subpopulations. *Elife* 2016;5doi: 10.7554/eLife.09462. PubMed PMID: 26905833.
- [33] Becker A, Crombag L, Heideman D, et al. Retreatment with erlotinib: regain of TKI sensitivity following a drug holiday for patients with NSCLC who initially responded to EGFR-TKI treatment. *Eur J Cancer* 2011;47:2603–6. doi: 10.1016/j.ejca.2011.06.046. PubMed PMID: 21784628.
- [34] Sequist L, Waltman B, Dias-Santagata D, et al. Genotypic and histological evolution of lung cancers acquiring resistance to EGFR inhibitors. *Sci Transl Med* 2011;3: 75ra26, doi: 10.1126/scitranslmed.3002003. PubMed PMID: 21430269.
- [35] Riely GJ, Kris MG, Zhao B, et al. Prospective assessment of discontinuation and reinitiation of erlotinib or gefitinib in patients with acquired resistance to erlotinib or gefitinib followed by the addition of everolimus. *Clin Cancer Res* 2007;13:5150–5. Epub 2007/09/06. doi: 10.1158/1078-0432.CCR-07-0560. PubMed PMID: 17785570.
- [36] Chaff J, Oxnard G, Sima C, Kris MG, Miller VA, Riely GJ. Disease flare after tyrosine kinase inhibitor discontinuation in patients with EGFR-mutant lung cancer and acquired resistance to erlotinib or gefitinib: implications for clinical trial design. *Clin Cancer Res* 2011;17:6298–303. doi: 10.1158/1078-0432.Ccr-11-1468. PubMed PMID: 21856766.
- [37] Xu Q, Zhou F, Liu H, et al. Consolidative local ablative therapy improves the survival of patients with synchronous oligometastatic NSCLC harboring EGFR activating mutation treated with first-line EGFR-TKIs. *J Thorac Oncol* 2018;13:1383–92. Epub 2018/06/01. doi: 10.1016/j.jtho.2018.05.019. PubMed PMID: 29852232.
- [38] Lo P, Dahlberg S, Nishino M, et al. Delay of treatment change after objective progression on first-line erlotinib in epidermal growth factor receptor-mutant lung cancer. *Cancer* 2015;121:2570–7. doi: 10.1002/cncr.29397. PubMed PMID: 25876525.
- [39] Patel P, Palma D, McDonald F, Tree AC. The dandelion dilemma revisited for oligoprogression: treat the whole lawn or weed selectively?

- Clin Oncol (R Coll Radiol)* 2019;31:824–33. doi: 10.1016/j.clon.2019.05.015. PubMed PMID: 31182289.
- [40] Kumar A, Petri E, Halmos B, et al. Structure and clinical relevance of the epidermal growth factor receptor in human cancer. *J Clin Oncol* 2008;26:1742–51. doi: 10.1200/jco.2007.12.1178. PubMed PMID: 18375904.
- [41] Shepherd FA, Rodrigues Pereira J, Ciuleanu T, et al. Erlotinib in previously treated non-small-cell lung cancer. *N Engl J Med* 2005;353:123–32. Epub 2005/07/15. doi: 10.1056/NEJMoa050753. PubMed PMID: 16014882.
- [42] Blackhall F, Ranson M, Thatcher F. Where next for gefitinib in patients with lung cancer? *Lancet Oncol* 2006;7:499–507. doi: 10.1016/s1470-2045(06)70725-2. PubMed PMID: 16750500.
- [43] Honeywell RJ, Kathmann I, Giovannetti E, et al. Epithelial transfer of the tyrosine kinase inhibitors erlotinib, gefitinib, afatinib, crizotinib, sorafenib, sunitinib, and dasatinib: implications for clinical resistance. *Cancers (Basel)* 2020;12: Epub 2020/11/14. doi: 10.3390/cancers12113322. PubMed PMID: 33182766; PubMed Central PMCID: PMC7696666.
- [44] Horiike A, Yamamoto N, Tanaka H, et al. Phase II study of erlotinib for acquired resistance to gefitinib in patients with advanced non-small cell lung cancer. *Anticancer Res* 2014;34:1975–81. PubMed PMID: 24692734.
- [45] Wu S, Chiang C, Liu C, et al. EGFR An observational study of acquired T790M-dependent resistance to EGFR-TKI treatment in lung adenocarcinoma patients in Taiwan. *Front Oncol* 2020;10:1481doi: 10.3389/fonc.2020.01481. PubMed PMID: 33014788.
- [46] Lin Y, Chen J, Liao W, et al. Clinical outcomes and secondary epidermal growth factor receptor (EGFR) T790M mutation among first-line gefitinib, erlotinib and afatinib-treated non-small cell lung cancer patients with activating EGFR mutations. *Int J Cancer* 2019;144:2887–96. doi: 10.1002/ijc.32025. PubMed PMID: 30485437.
- [47] Flippot R, Biondani P, Auclin E, et al. Activity of EGFR tyrosine kinase inhibitors in NSCLC with refractory leptomeningeal metastases. *J Thorac Oncol* 2019;14:1400–7. doi: 10.1016/j.jtho.2019.05.007. PubMed PMID: 31108248.
- [48] Cho K, Keam B, Kim T, Lee SH, Kim DW, Heo DS. Clinical efficacy of erlotinib, a salvage treatment for non-small cell lung cancer patients following gefitinib failure. *Korean J Intern Med* 2015;30:891–8. doi: 10.3904/kjim.2015.30.6.891. PubMed PMID: 26552465.
- [49] Hata A, Katakami N, Yoshioka H, et al. Erlotinib after gefitinib failure in relapsed non-small cell lung cancer: clinical benefit with optimal patient selection. *Lung Cancer* 2011;74:268–73. doi: 10.1016/j.lungcan.2011.03.010. PubMed PMID: 21529987.
- [50] Kwon B, Park J, Kim W, et al. Predictive factors for switched EGFR-TKI retreatment in patients with EGFR-mutant non-small cell lung cancer. *Tuberc Repair Dis (Seoul)* 2017;80:187–93. doi: 10.4046/trd.2017.80.2.187. PubMed PMID: 28416959.