




ELSEVIER

Contents lists available at ScienceDirect

Veterinary and Animal Science

journal homepage: www.elsevier.com/locate/vas

Dental pathology of the wild Iberian wolf (*Canis lupus signatus*): The study of a 20th century Portuguese museum collection

AE Pires^{a,b,1}, IS Caldeira^{a,1}, F Petrucci-Fonseca^c, I Viegas^{a,2}, C Viegas^d, C Bastos-Silveira^{c,e}, JF Requicha^{a,d,*}

^a Faculty of Veterinary Medicine, Lusófona University, Lisbon, Portugal

^b Archaeogenetics group from CIBIO - Research Centre in Biodiversity and Genetic Resources/InBIO - Research Network in Biodiversity and Evolutionary Biology, Porto, Portugal and Laboratório de Arqueociências (LARC) – Direção Geral do Património Cultural (DGPC), Lisbon, Portugal

^c cE3c - Centre for Ecology, Evolution and Environmental Changes, Sciences Faculty, Lisbon University, Lisbon, Portugal

^d Department of Veterinary Sciences, University of Trás-os-Montes e Alto Douro, Vila Real, Portugal

^e MUHNAC - National Museum of Natural History and Science, University of Lisbon, Portugal

ARTICLE INFO

Keywords:

Dental pathology
Canis lupus signatus
 Iberian wolf
 Museum collection
 Dental radiography

ABSTRACT

For some wild canids, such as the Iberian wolf, there is a lack of in-depth knowledge about dental pathology. We aimed to evaluate it, in a standardized manner, in specimens from a Portuguese museum collection.

Sixty-five deceased specimens of wild Iberian wolves, 61 complete skulls and 4 mandibles, collected in Portugal between 1977 and 1995, were analyzed. Sample comprised 18 females, 24 males and 23 individuals of undetermined sex. Teeth were evaluated by visual observation and dental radiography for tooth wear, periodontitis, fractures and other dental lesions.

We have found several causes for teeth absence: artefactual, secondary to periodontitis and agenesis. About 30% of the teeth showed signs of wear. Only a small (<13%) fraction of maxillary and mandibular teeth did not show periodontitis. The tooth 308 showed periodontitis in all males ($p = 0.017$) and the tooth 104 was significantly affected by this condition in females ($p = 0.020$). A significant relationship was found between females and tooth wear in three teeth. Periodontitis showed a significant association with tooth wear ($p < 0.001$) and fractures ($p = 0.027$). Tooth fractures were more frequent in the maxilla than in the mandible. Seven periapical lesions, seven root fusions and three specimens with malocclusion were identified in the collection. Results are discussed integrating information from diet, habitat, genetic and spatial behavior.

Dental radiography is here proposed as an approach for the age estimation in archaeological canids. This research contributes to the knowledge of the dental disease in the largest wolf population in Western Europe, a target subspecies of multiple conservation measures.

1. Introduction

The Iberian wolf *Canis lupus signatus* (Cabrera, 1907) is an Iberian Peninsula endemism of the European gray wolf. Currently its population is isolated from its European counterparts (Chapron et al., 2014; Hindrikson et al., 2017) and its distribution spans from the north-western part of the Iberian Peninsula to south of the Douro river, with an uncertain small group in Sierra Morena (south of Spain) (Álvares, 2011; López-Bao et al., 2015). Demographically, the population reached minimum numbers in the 1970's, but has expanded to an estimated size of > 2,000 individuals (Álvares, 2011). In Portugal, the

conservation status of this sub-species is “endangered” (Cabral et al., 2005) and it is fully protected by law in Portugal (Decree-Law No. 139/90 regulating Law No. 90/88). In Spain, its protection varies regionally (Trouwborst, 2014). Iberian wolf persists in landscapes with high human densities and, although being a highly mobile mammalian carnivore, the Iberian wolf shows high levels of genetic structure and low levels of admixture between clusters (Silva et al., 2018).

As to diet, wolves are carnivores, but can act as opportunist to adapt to a large variety of ecological conditions in the wild. The world's gray wolves feeding habits have been recently characterized (Newsome et al., 2016), showing significant differences among

* Corresponding author.

¹ These two authors contributed equally to this manuscript.

² Present address: ICAAM - Mediterranean Institute of Agronomical and Environmental Sciences, Institute for Advanced Research and Formation, Évora University, Évora, Portugal.

<https://doi.org/10.1016/j.vas.2020.100100>

Received 2 November 2019; Received in revised form 11 February 2020; Accepted 18 February 2020

Available online 22 February 2020

2451-943X/ © 2020 The Authors. Published by Elsevier Ltd. This is an open access article under the CC BY-NC-ND license

(<http://creativecommons.org/licenses/by-nc-nd/4.0/>).

continents. Based on a review of 177 studies, which analyzed the dietary content from stomachs and scats, gray wolves' diet greatly depends on wild ungulates. In Europe, medium sized ungulates predominate in the wolf's diet, but domestic animals also comprised a large dietary percentage. The analysis of 251 stomach contents from Iberian wolves in Spain, showed that even fish constituted a small part of their diet (Cuesta, Barcena, Palacios, and Reig, 1991). In human-dominated landscapes without enough wild preys, Iberian wolves feed mainly on anthropogenic sources of food - e.g. livestock, such as horse, cattle, sheep, goat and pig (Álvares, 2011; Llana, López-Bao, and Sazatornil, 2012; Petrucci-Fonseca, 1990). Human-provided foods, including garbage/carrion, is also present in the diet of wolf populations in Europe (Newsome et al., 2016). In the past, before 1986 when environmental and agricultural policies were not so strict (López-Bao et al., 2015), carrion was highly available, and it was an important food source for wolves in Iberia (Cuesta et al., 1991).

Regarding the dental anatomy of this canid, puppies are born toothless. The primary or deciduous dentition is followed by a secondary or permanent dentition, which comprises 42 teeth. The dental formula (maxilla/mandible) presents incisors 3/3, canines 1/1, premolars 4/4 and molars 2/3. Wolves reach dental maturity at the age of 4 to 6 months, but their skeletal maturity is reached later, at around 10 to 12 months of age (Geiger, Gendron, Willmitzer, and Sánchez-Villagra, 2016).

Dental disease is a common condition in domestic carnivores. In dogs, the most frequently observed pathology is the periodontal disease (Albuquerque et al., 2012), as well as tooth fractures and dentoalveolar traumatic lesions, tooth wear, endodontic and periapical lesions, persistence of deciduous teeth, absent or supernumerary teeth, malocclusion, among other abnormalities (Niemiec, 2008).

Regarding the wild Iberian wolf, information about its dental and periodontal pathology is very scarce. As expected, it is challenging to capture and examine these animals specially for a methodical and systematic clinical oral inspection. However, natural history collections through their specimens and associated documentation, are important source of information allowing, for example, for collecting medical data from both domestic and wild animals. In fact, several species were already assessed for dental abnormalities using museum collection, as the case of gray wolf (*Canis lupus*) (Barber-Meyer, 2012; Döring, Arzi, Winer, Kass, and Verstraete, 2018; Janssens, Verhaert, Berkowic, and Adriaens, 2016; Pavlović, Gomerčić, Gužvica, Kusak, and Huber, 2007; Valkenburgh, 1988; Vilà, Urios, and Castroviejo, 2008), red fox (*Vulpes vulpes*) (Szuma, 2014), African lion (*Panthera leo*), leopard (*P. pardus*), jaguar (*P. onca*), cheetah (*Acinonyx jubatus*), puma (*Puma concolor*), spotted hyena (*Crocuta crocuta*), striped hyena (*Hyaena hyaena*), and the African wild dog (*Lycaon pictus*) (Valkenburgh, 1988), Southern sea otter (*Enhydra lutris nereis*) (Winer, Liang, and Verstraete, 2013), Iberian lynx (*Lynx pardinus*) (Collados, Garcia, and Rice, 2018), domestic dog (*Canis lupus familiaris*) (MacKinnon, 2010), domestic cat (*Felis silvestris catus*) and free-living Soay sheep (*Ovis aries*) (Arthur et al., 2015).

Considering the accelerating environmental changes we are witnessing and the increase of human-dominated landscapes, one can question the impact on wild animals' welfare. By taking the incidence of dental and periodontal pathology as proxy to evaluate health, we aim to reduce the gap of knowledge regarding wild Iberian wolves' health conditions. To do so we combined a visual evaluation and a radiographic analysis of museum specimens. The generated data will be analyzed under the light of biological and ecological factors that are of importance for the survival of a free-ranging species.

2. Materials and methods

2.1. Museum collection

The present study was conducted using the Mammal Collection from

the National Museum of Natural History and Science (MUHNAC), University of Lisbon, Portugal. Sixty-one complete skulls and four mandibles of Iberian wolves were analyzed (Supplementary Materials, Table S1). These specimens were collected in Portugal between years 1977 and 1995, resulting from scientific research projects, in particular the Portuguese lupine population study (Petrucci-Fonseca, 1990) and monitoring campaigns conducted by the Portuguese Wolf Group (<http://www.grupolobo.pt/>) within the area of the Iberian wolf geographical distribution in Portugal. These animals were found dead in the wild, mainly by causes including hunting (until 1988), illegal trapping, road killing and poisoning. No animal was sacrificed for the purpose of this investigation.

2.2. Macroscopic analysis

All teeth from the four dental quadrants were assessed for dental alterations according to American Veterinary Dental College nomenclature (AVDC, 2016) and these were annotated in a dental chart according to the modified Triadan system currently used in Veterinary Dentistry (Fig. 1). For the visual evaluation, the following parameters were investigated: absent teeth, periodontal disease and its stages, tooth wear and presence of tertiary dentin, presence of periapical lesions, tooth fractures and tooth malformations (Supplementary Materials, Table S2). All museum specimens were handled with care and the observers wore latex gloves during their observations.

2.3. Radiographic analysis

The intraoral radiographic analysis has been useful in carnivore companion animals for the diagnosis and treatment of tooth and periodontal conditions (Bannon, 2013). Dental x-rays also offer the possibility to estimate specimens' age at death (Park et al., 2014). Based on dogs' radiographic dental anatomy, if there was a wide pulp chamber and if the root apices were opened the specimen was considered younger than 18 months old (Gorrel, 2004).

In the present study, a portable dental x-ray generator (Port-X II, Genoray, South Korea) and an indirect digital system (VistaScan Mini View, Durr Dental, Germany) were used to perform the dental radiographs, whenever there was a need to further characterize any identified alteration. For mandibular premolars and molars teeth, the parallel technique was carried out. For canines, incisors and maxillary premolars and molars teeth, the bisecting technique was used (Bannon, 2013).

2.4. Statistical analysis

For the statistical analysis we used the software SPSS, version 22.0 (IBM, USA). For the studied parameters the descriptive statistics was based on a frequency analysis. The inferential statistical analysis was based on chi-square tests, when relationships between the parameters were established. We considered a *p* value as significant when its value is \leq the significance level of $\alpha = 5\%$.

All the *postmortem* lesions, or marks derived from specimen preparation and preservation, were registered, but not included in the statistical analysis. In artefactual exfoliated teeth it was possible to evaluate and classify some of the studied parameters, such as the tooth wear, tooth fractures and tooth malformations.

3. Results

In the present study, a total of 61 complete skulls and 4 mandibles were observed, resulting in 1,280 maxillary and 1,309 mandibular teeth screened for dental lesions.

Only five (7.69%) of the studied specimens were considered young animals, less than 8 months old, as adult teeth eruption was ongoing. In contrast, 60 individuals (92.31%) were considered to be adults due to

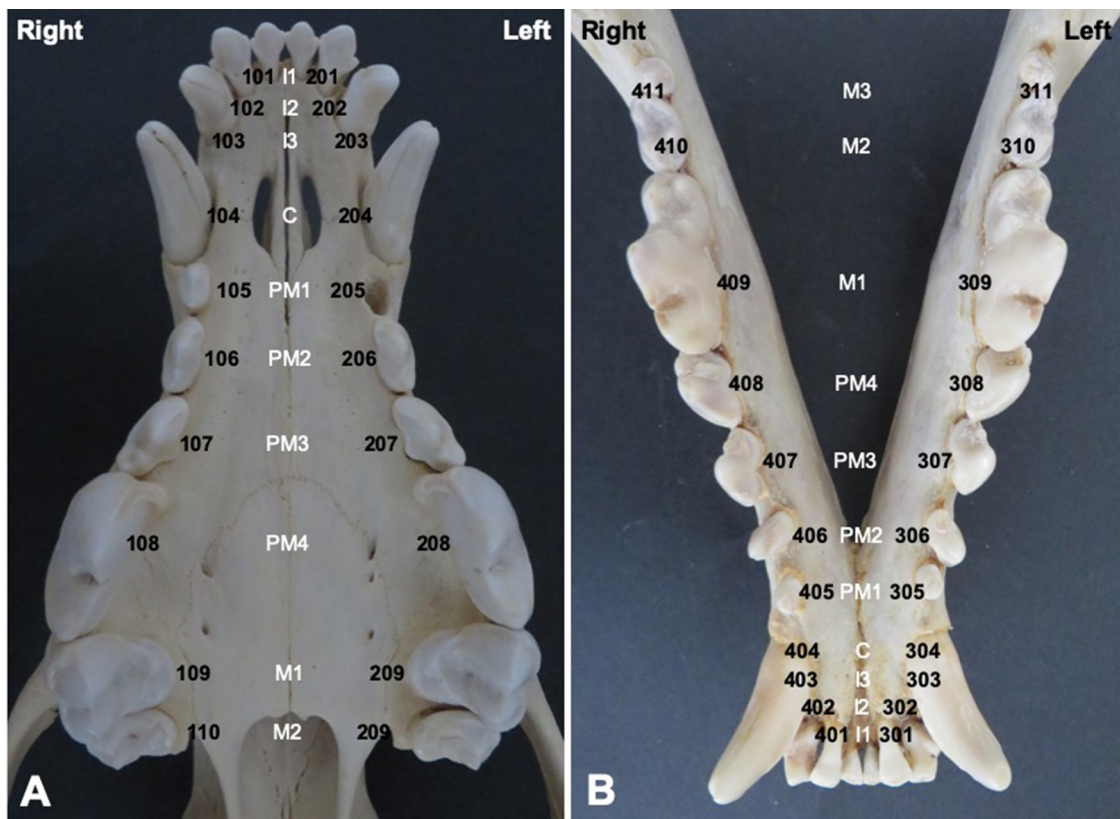


Fig. 1. Photograph of the maxillary (A) and mandibular (B) dental arches from an Iberian wolf museum specimen showing the permanent teeth numbered according to the modified Triadan system used in Veterinary Dentistry.

the observation of permanent dentition. Eighteen specimens were females, 24 were males and 23 had no data regarding sex identification. Hereafter, data are reported per tooth and not per specimen.

Fig. 2 illustrates the usefulness of dental radiography as a tool for evaluating the morphology of endodontic system, namely the width of root canals and the apex appearance.

3.1. Absent teeth

One hundred and forty teeth, approximately 11% (10.9%) of the maxillary teeth were artefactually absent (Figs. 3.A and 4.A). The acquired absence of teeth, most likely due to periodontitis, amounts to 16 (1.3%) (Fig. 3.D and 4.B). A minute fraction of two teeth (0.2%) were under eruption.

Regarding the mandibular teeth, 126 (9.6%) were artefactually absent (Fig. 4.C,E), 10 (0.8%) refers to acquired absence due to periodontitis, four (0.3%) were agenesic (Figs. 3.B-C and 4.D) and five (0.4%) were erupting. The teeth 306, 311 and 411 were the most frequently absent by agenesis (1, 1.7%; 2, 3.3% and 1, 1.7%, respectively). In this study, artefactual absence was the most frequent cause of tooth absence.

3.2. Tooth wear

We were able to evaluate dental wear in 1,122 of maxillary teeth, and 635 presented signs of wear. The tooth 208 showed dental wear in 51 cases (81%). In contrast, tooth 105 exhibited dental wear in 22 cases - the lowest frequency (40.8%). In a small fraction of 70 teeth (6.7%), it was not possible to estimate dental wear stage due to tooth absence. The remaining 412 teeth (36.7%) showed dental wear stage 0, 266 (23.7%) stage 1, 167 (14.9%) stage 2, 150 (13.4%) stage 3 and 52 (4.6%) stage 4. In the maxillary teeth, tooth wear stage 1 was the most detected. The tooth with a higher wear grade (grade 4) was

tooth 109, followed by teeth 108, 209 and 208, in a frequency of 10.0% (6), 10.0% (6), 8.5% (5) and 8.1% (4), respectively (Figs. 3.D and 5.E-F).

In a total of 1,161 mandibular teeth, in which dental wear analysis was possible, 672 teeth (61.7%) showed signs of wear. In 72 of these teeth (6.2%), it was not possible to assess the dental wear stage. In 417 (35.9%) teeth, we found evidence of dental wear stage 0, 302 (26.0%) stage 1, 184 (15.8%) stage 2, 134 (11.5%) stage 3 and 52 (4.5%) stage 4. The mandibular teeth that showed the highest and lowest frequency of dental wear were tooth 409 (50, 83.6%) and tooth 401 (18, 32.6%), respectively. Stage 1 was the most observed dental wear stage. The mandibular teeth most affected by dental wear stage 4 (severe) were the mandible carnassial teeth 409 (11, 18.2%) and 309 (8, 15.5%) (Figs. 3.E-F, 4.D-F and 5.G-H).

3.3. Periodontal disease

Periodontitis, which includes the periodontal disease stages 2 to 4, was present in 908 of the 1,123 maxillary teeth analyzed for this parameter (92.1%). For 91 teeth (8.1%), it was not possible to determine the stage of the periodontal disease (avulsed or extruded teeth). In the assessed teeth, 124 (11.0%) presented periodontal disease stage 0-1 (absence of periodontitis), 830 (73.9%) stage 2 (mild periodontitis), 72 (6.4%) stage 3 (moderate periodontitis) and only six (0.5%) stage 4 (severe periodontitis) (Fig. 3.G-H and 5.A-B, Table 1).

Periodontitis was found in 876 (88%) of 1164 mandibular teeth. In a fraction of 109 (9.4%) of the mandibular teeth, periodontal disease was not possible to be assessed due to artefactual dental avulsion or extrusion from the alveolus. In the remaining teeth, 179 (15.4%) did not show signs of disease, 792 (68.0%) stage 2, 80 (6.9%) stage 3 and 4 (0.3%) stage 4 (Figs. 3.I-J, 4.E-F and 5.C-D, Table 1).

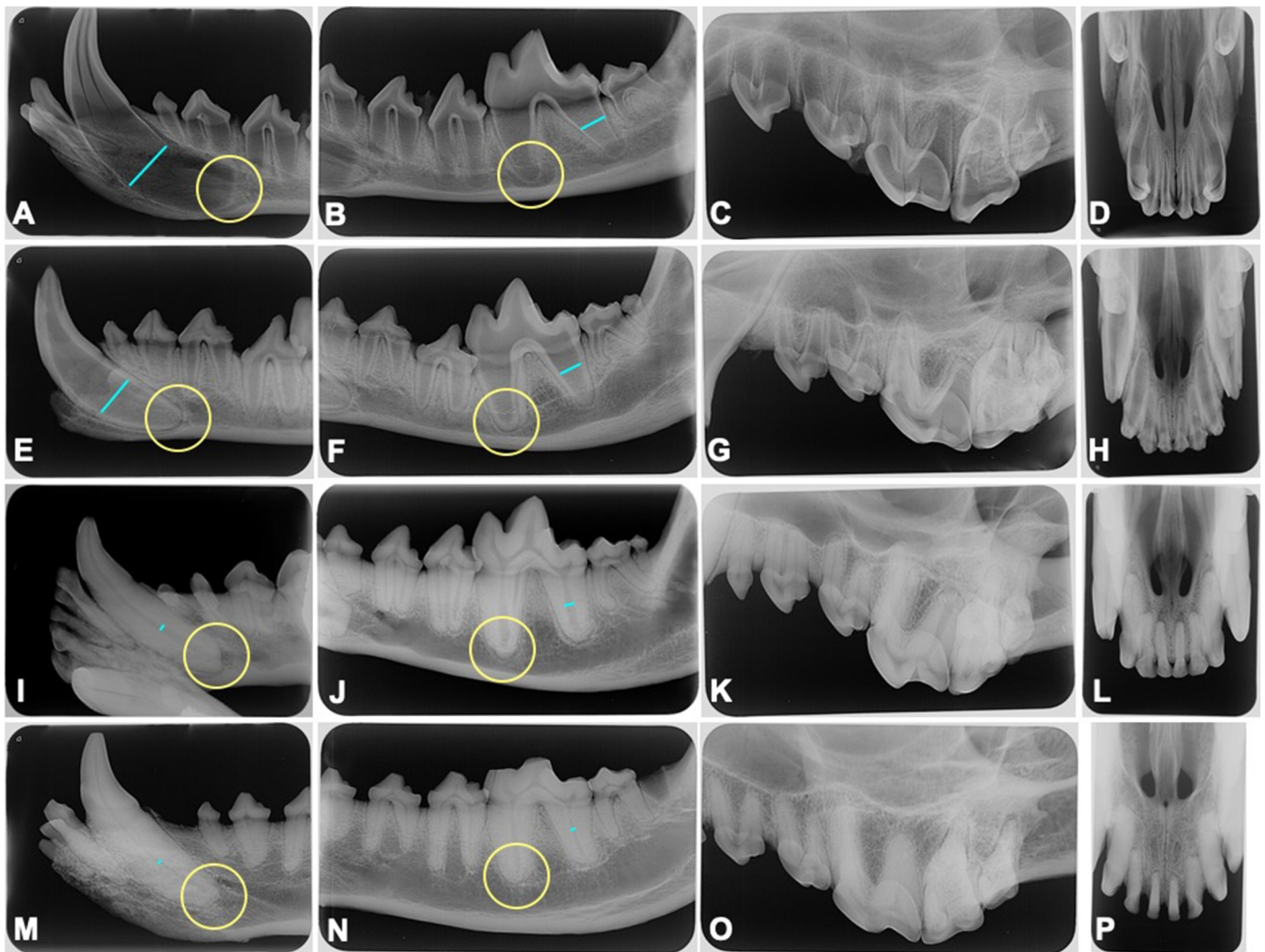


Fig. 2. Representative radiographic images of dental maturation from Iberian wolves' permanent teeth after eruption. Images taken from four specimens with different ages. A-D: Juvenile wolf's teeth with typical large pulp chamber and root canals (represented by blue lines), root is being formed (rizogenesis) and a single wide opened apical foramen (represented by yellow circle) is still present. E-H: Juvenile wolf's teeth with formed apices (apexogenesis) and a narrower endodontic system, due to the centripetal secondary dentine deposition along the development of the permanent tooth. I-L and M-P: Adult wolves from different ages presenting a typical narrow endodontic system and closed apices. The first, third and fourth columns' x-rays were acquired using the bisecting technique and the second column's images acquired using the parallel technique.

3.4. Tooth fracture

Regarding the presence of tooth fractures, among the 1,124 maxillary teeth analyzed for this parameter, only 52 (4.5%) showed fractures. Twenty of the latter (1.8% from the total) were enamel fractures, 16 (1.4%) complicated crown fractures, 5 (0.4%) complicated crown-root fractures, 6 (0.5%) uncomplicated crown fractures and in 5 (0.4%) uncomplicated crown-root fractures. The maxillary tooth with the highest fracture frequency was tooth 203 (6, 10.3%), followed by 104 (5, 9.1%) and 107 (5, 9.1%). Teeth 102 and 210 never revealed fractures.

Considering the 1,164 mandibular teeth available to be evaluated, only 35 (3.0% from the total) presented fractures, among which 15 of them (1.3%) were enamel fractures, 7 (0.6%) were complicated crown fracture, 7 (0.6%) uncomplicated crown fracture and 6 (0.5%) classified as complicated crown-root fractures. The mandibular teeth with highest frequency of fracture were the 304, 405 and 406, all of them with four (7.5%) affected teeth. The teeth 410, 402, 403, 302 and 311 did not show fractures (Fig. 3.K-L, Table 2).

3.5. Other observed abnormalities

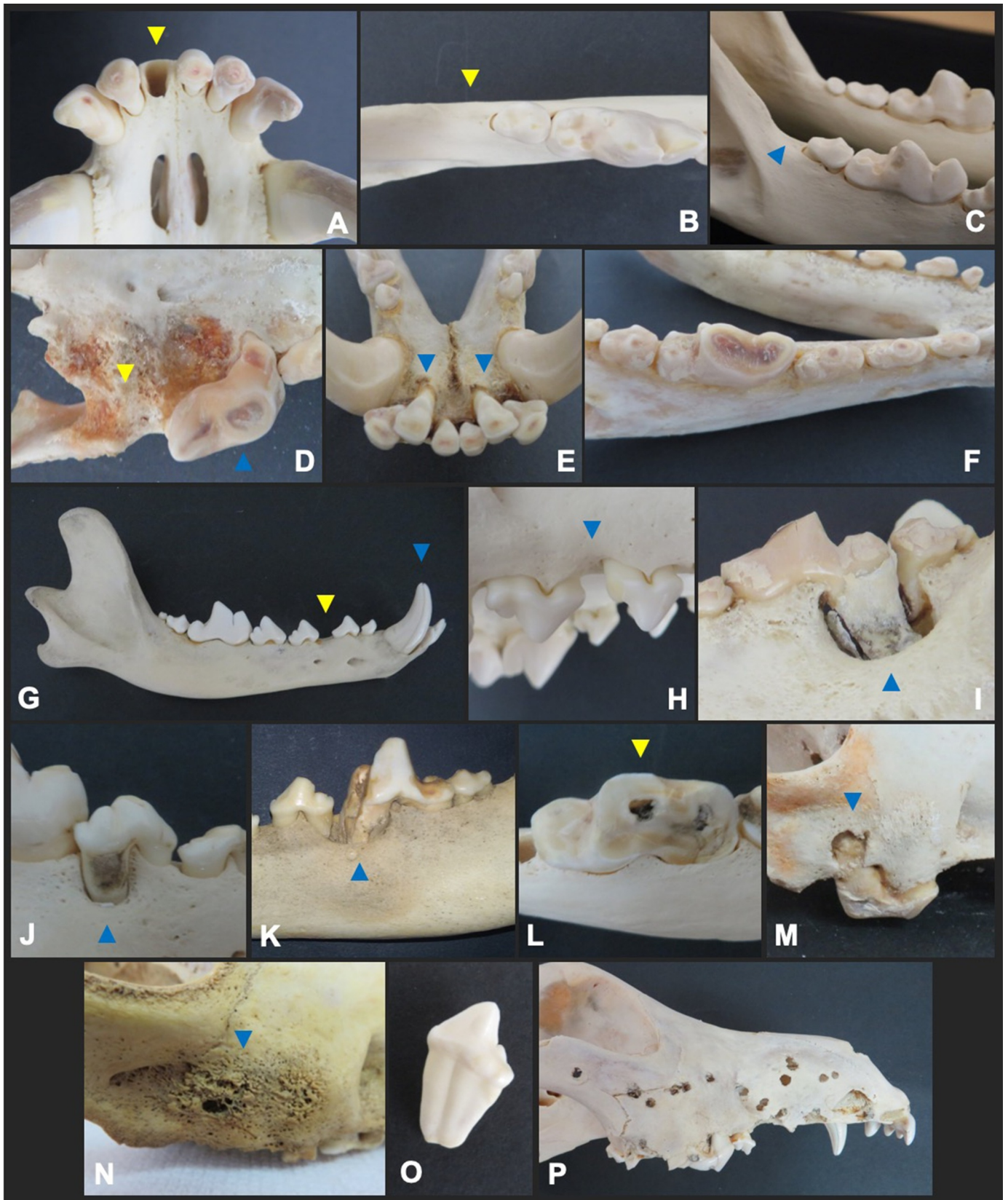
Seven periapical lesions were also identified in the collection by visual observation of a bone defect (Fig. 3.M-N) and further confirmed by X-ray analysis (Fig. 4.B).

Three wolves were identified with mandibular distocclusion, a skeletal malocclusion, and tooth wear (stages 3-4 in two specimens and stages 1-2 in the third) was observed possibly secondary to attrition. Persistence of deciduous teeth was not observed in the studied collection.

Regarding tooth malformations, seven individuals, two males and five females, presented teeth with fused roots in the 306 tooth (5 times), 406 tooth (3), and in 206, 210 and 110 teeth (3 for each) (Figs. 3.O and 4.C).

3.6. Significant associations

A significant relationship between the presence of periodontitis and sex was detected for tooth 308 in males ($p = 0.017$) and tooth 104 in females ($p = 0.020$). All 104 teeth analyzed in females ($n = 15$) exhibited periodontal disease from stage 2 to 4. A significant relationship



(caption on next page)

Fig. 3. Representative images of dental and periodontal abnormalities observed in the studied Iberian wolves' museum specimens. A: Artefactual absence of the 101 tooth. B: Congenital absence of the 311 tooth (arrow). C: Congenital absence of the 411 tooth (arrow). D: Acquired absence of the 209 and 210 teeth with signs of bone remodeling in the alveolus (arrow), severe tooth wear (stage 4) in the 208 tooth (blue arrow). E: Lingualization (dental malocclusion) of 302 and 402 incisors teeth, mild tooth wear (stage 1). F: Severe tooth wear in the mandibular premolars (stage 3) and in the 309 tooth (stage 4). G: Normal appearance of mandibular teeth inserted in the alveolar process, no signs of periodontitis (PD stage 0 or 1), diastema between the 406 and 407 teeth (yellow arrow), artefactual crown fracture of the 404 tooth (blue arrow). H: Mild periodontitis (PD2) in distal root of 106 tooth and mesial root of 107 tooth. I: Severe periodontitis (PD4) in distal root of 309 tooth and mesial root of 310 tooth (see Fig. 4.F). J: Severe periodontitis (PD4) in distal root of 408 tooth. K: Complicated crown and mesial root fracture of the 409 tooth (arrow) associated to periodontitis between the 408 and 409 teeth. L: Complicated crown fracture of the 409 tooth (arrow). M: Periapical lesion at the distal root of 108 tooth (see Fig. 4.B). N: Multifocal osteolytic lesions compatible with maxillary bone osteitis. O: Fused roots. P: Penetrating bone injuries caused by gunshot.

was found between females and tooth wear in the following teeth: 305 ($p = 0.031$), 404 ($p = 0.018$) and 406 ($p = 0.019$).

We have found another statistically significant association, between tooth wear and periodontitis, in both maxilla and mandible ($p < 0.001$). Periodontitis and fractures were also positively correlated ($p = 0.027$), but restricted to the maxilla (association not verified for the mandible, $p = 0.095$).

4. Discussion

Natural history collections are an important source of information about extant and extinct organisms and constitute valuable foundations for research on several scientific domains. The National Museum of Natural History and Science (MUHNAC) is the institution responsible for holding the national collection of wolves resulting from the "Monitoring System for dead Iberian wolves" conducted by the Portuguese Nature Conservation Institute since 1999. With more than 100 specimens, comprising skulls, skins, complete skeletons and mounted specimens, MUHNAC holds the largest Iberian wolf collection

at national level. The analysis of museum collections allows the characterization of normal and pathological anatomy of different animal species. Therefore, this work contributes to this objective, namely, in the assessment of dental pathology in the Iberian wolf.

4.1. Absent teeth

In our study, the most frequent cause for tooth absence seems to be artefactual and two factors may explain that. First, tooth absence could be the result of longer exposure, of the carcass, to adverse environment conditions before being collected. Secondly, effects of the taxidermic process during specimen preparation cannot be discarded. The teeth that showed congenital absence were the 306, 311 and 411. [Lacerda and colleagues \(2000\)](#) observed that, in 100 skulls obtained from dead dogs, only two showed absence of both left and right third mandibular teeth (teeth 311 and 411, respectively) and one specimen also showed a congenital absence of both right and left 2nd maxillary molars (teeth 110 and 210, respectively) ([Lacerda, Oliveira, and Queiroz, 2006](#)). The high frequency of congenital absence of mandibular third molars (311

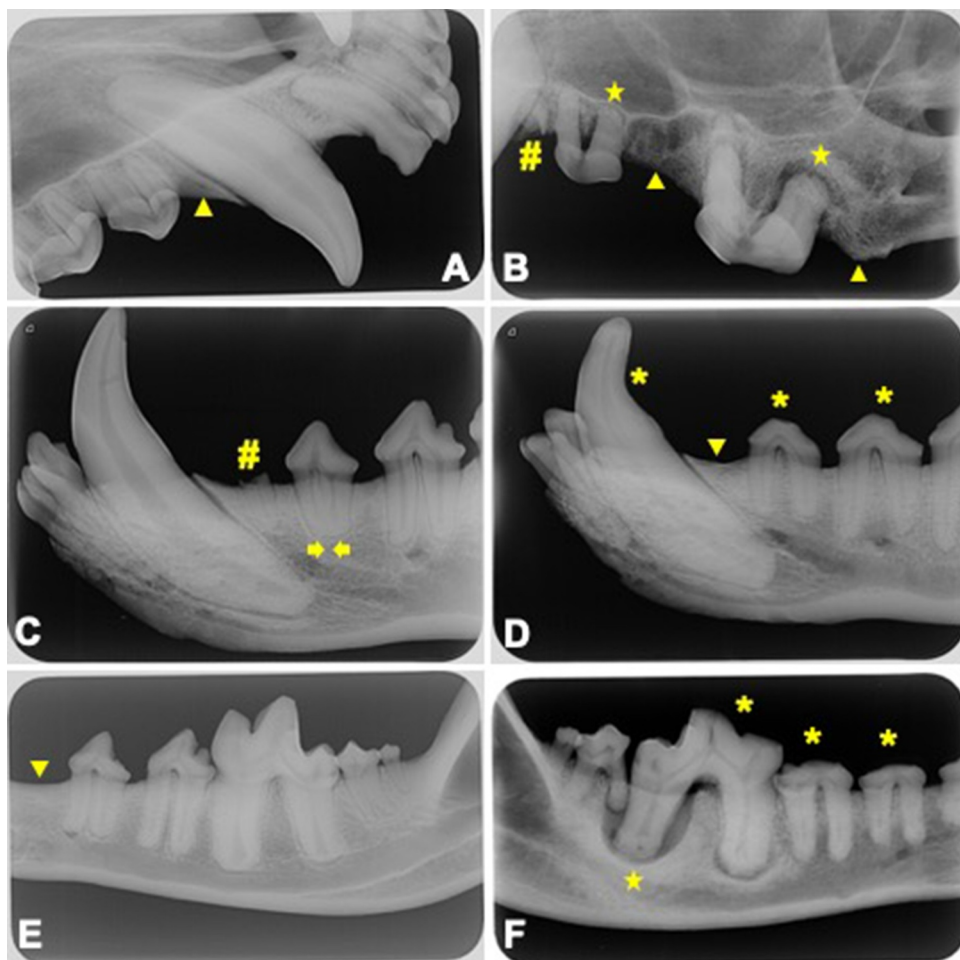
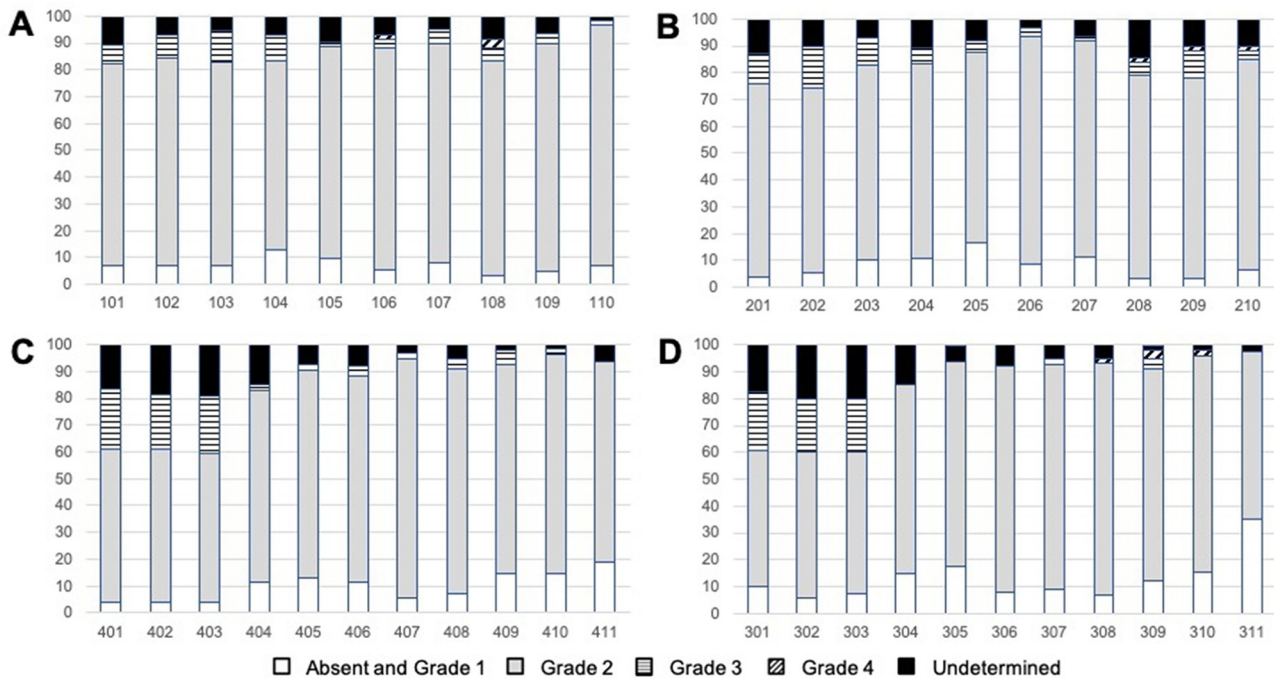
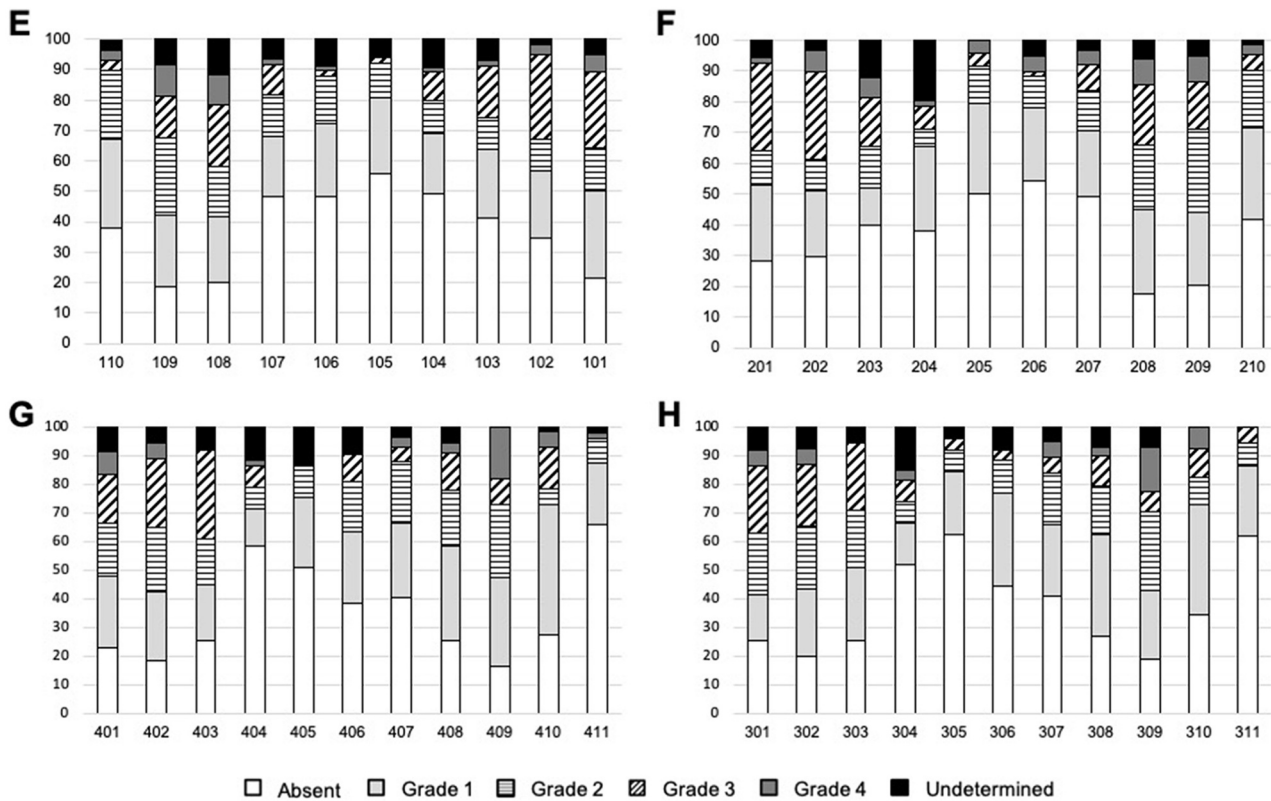


Fig. 4. Representative radiographic images of the studied Iberian wolves' museum specimens, acquired using the parallel and bisecting techniques. A: Congenitally absent 105 tooth (arrow). B: Acquired absent teeth probably secondary to periodontitis (arrow), artefactual root fragment (#), severe bone loss around distal root of 208 tooth associated with a periapical lesion (star). C: Fused roots (convergent arrows), root fragment. D: Congenitally absent 305 tooth (arrow), tooth wear in multiple teeth (*). E: Congenitally absent 306 tooth (arrow), no radiographic signals of periodontitis (PD01). F: Severe bone loss around distal root of 409 tooth associated to a periapical lesion and radiographic signals of tooth wear (*).

Periodontal Disease



Tooth Wear



(caption on next page)

Fig. 5. Graphic representation of the degree of periodontal disease (A-D) and dental wear (E-H) per tooth. A and B: Maxillary teeth that showed the highest and the lowest periodontitis frequency were the 108 at 96.4% and 205 at 81.8%, respectively. Teeth 106, 108, 208, 209 and 210 exhibited the most severe grade of periodontitis (grade 4) at a frequency of 1.7%, 3.3%, 1.6%, 1.7% and 1.7%, respectively. C and D: Mandibular teeth that showed the highest and the lowest periodontitis frequency were the 402 tooth at 95.5% and 311 tooth at 64.9%, respectively. Teeth 308, 309 and 310 exhibited the most severe grade of periodontitis (grade 4) at a frequency of 1.7%, 3.4% and 1.9%, respectively. E and F: Maxillary teeth that showed the highest and the lowest frequency of dental wear were the 208 at 81% and 105 at 40.8%, respectively. Teeth 109, 108, 209 and 208, exhibited the most severe grade of tooth wear (grade 4) at a frequency of 10.2%, 10.0%, 8.5% and 8.1%, respectively. G and H: Mandibular teeth that showed the highest and the lowest dental wear frequency were the 409 tooth at 83.6% and 401 tooth at 32.6%, respectively. Tooth 409 showed the highest grade of wear (grade 4) at 18.2% followed by its contralateral tooth 309 at 15.5%.

Table 1

Frequency of periodontal disease stages in the studied Iberian wolves' museum specimens. In both maxillary and mandibular teeth, the stage 2 (mild periodontitis) was the most frequently detected, in contrast to stage 4 (severe periodontitis).

Periodontal disease	Maxilla (n = 1,123)	Mandible (n = 1,164)
Stages 0-1	124; 11%	179; 15.4%
Stage 2	830; 73.9%	792; 68.0%
Stage 3	72; 6.4%	80; 6.9%
Stage 4	6; 0.5%	4; 0.3%
Not possible to evaluate	91; 8.1%	109; 9.4%

Table 2

Frequency of tooth fractures detected in the studied Iberian wolves' museum specimens. In both maxillary and mandibular teeth, the most frequently detected type was the enamel fracture.

Tooth fracture	Maxilla (n = 1,124)	Mandible (n = 1,164)
Uncomplicated crown fracture	6; 0.5%	7; 0.6%
Complicated crown fracture	16; 1.4%	7; 0.6%
Uncomplicated crown and root fracture	5; 0.4%	0; 0%
Complicated crown and root fracture	5; 0.4%	6; 0.5%
Enamel fracture	20; 1.8%	15; 1.3%

and 411 teeth) maybe related to their small sized roots and less alveolar bone support at mandible. These teeth, as well as both the mandibular and maxillary first and second premolars (teeth 108 and 208) are the most frequently reported to be missing in Terrier dogs (Pavlica, Erjavec, and Petelin, 2001).

From the analysis of 500 gray wolf skulls, Vilà et al. (2008) described 101 cases with acquired missing teeth associated to periodontitis (61 located in the maxilla and 40 in the mandible). Alveolar bone resorption was more frequent in premolars, followed by those of molars. In nine cases, authors observed anodonty of uncertain origin. Alveolar sockets, after adult teeth exfoliation, were filled by trabecular bone during the process of bone regeneration (Vilà et al., 2008). The present study also showed similar results, as the teeth with a higher occurrence of acquired absence were also the premolars (108 and 306) and then the molars (109 and 110) teeth with evidences of trabecular bone filling in the alveolus.

When tooth absence is observed during an oral examination, an intraoral radiography should be obtained to confirm its absence or to document the presence of any unerupted or retained tooth (Bannon, 2013). In the present study, we followed this methodology but did not detect any of the two mentioned abnormalities.

4.2. Tooth wear

Abrasion is defined as wear caused by contact of a tooth with a non-dental hard object, whereas attrition refers to dental wear caused by contact of a tooth with its antagonist tooth (AVDC, 2016). The distinction between both types of wear is important when evaluating wild canids. If an individual presents signs of tooth attrition, it is more difficult to infer about its food habits, determine tooth wear grade or

estimate specimen's age.

Considering that only three specimens were observed with a mandibular distocclusion which causes attrition between teeth, we can affirm that the majority of the tooth wear identified in the collection (ca. 60% of the teeth) was due to abrasion possibly caused, for example, by inadequate handling of abrasive objects.

In dire wolves (*Canis dirus*), Binder and Valkenburgh (2010) found tooth wear and fractures specimens from different ages, assuming that these abnormality were not associated with age, but instead with different feeding habits, possibly as bone consumption (Binder and Valkenburgh, 2010). That is why wild wolves can have a higher grade of damaged teeth compared to wolves in captivity (Shelbourne, 2010). Ellis and Sloan (2006) refer that small pieces of vegetation can also be used by wolves in order to clean their teeth after a meal. All these hard materials can cause a considerable grade of tooth wear.

Given the above, the association between teeth wear and increasing age is not an easy task and needs further investigation. However, Gipson and collaborators (2000) mention that the carnassial teeth, in gray wolves, starts to show signs of dental wear in animals older than 6 years old. Considering that in our study the most frequently observed tooth wear grade was grade 1, we can infer that the analyzed MUHNAC skulls analyzed belongs to animals that died with less than 6 years old, and therefore were young adults. This is in accordance with data from Petrucci Fonseca (1990), who estimated the age of these specimens of MUHNAC collection, based on cementum aging analysis of 81 teeth and also on *baculum* morphology.

4.3. Periodontal disease

Periodontal disease is a pathological inflammatory condition of the periodontal tissues usually caused by the effect of the dental biofilm on the gingiva (gingivitis, periodontal disease stage 1) and other tissue including alveolar bone, periodontal ligament and root cementum (periodontitis, periodontal disease stages 2-3) (Albuquerque et al., 2012). This condition is reported in 95% of Beagle dogs older than 26 months of age (Rosenberg, Rehfeld, and Emmering, 1966). In Poodles, all dogs older than 4 years old were documented to have, at least, one tooth with periodontitis (Hoffmann and Gaengler, 1996). Other authors referred that periodontal disease has a higher prevalence in small and miniature breeds (Harvey, 1998). Different frequencies were already reported in Yorkshire Terrier (25.2%), Cocker Spaniel (12.8%), cross-breeds (9.2%), Labrador Retriever (3.2%) and Staffordshire Bull Terrier (2.4%) (O'Neill, Church, McGreevy, Thomson, and Brodbelt, 2014). Domestication factors, such as stress, longer mean life span and chemical and mechanical aspects of the diet, in addition to the genetics, could justify the higher incidence of the disease in dogs comparing to wild canids (Harvey, 1998). In our study, ~ 90% of the analyzed teeth showed signs of periodontitis (periodontal disease stages 2 to 4). It is important to note that, some wolves which did not show clinical or radiographic signs of periodontitis, such as alveolar bone lysis, may have suffered from periodontal disease stage 1 (gingivitis). This condition leaves no marks on the skulls, because the gingival insertion at the cemento-enamel junction can only be assessed when soft tissue is present (Janssens et al., 2016). Thus, an important management measure would be to assess gingivitis, through the visualization of the oral tissues, during medical intervention on Iberian wolves individuals

which are under monitoring programs.

The fact that wild Iberian wolf can scavenge and feed on dumpsters (David Mech and Boitani, 2007), could lead an extra load of oral microbes that predisposes this subspecies to periodontal disease. Our results show that maxillary tooth 108, used to break bones and grind small fragments, showed the highest frequency of periodontitis, and in mandible the tooth showing the highest frequency of periodontitis was the 402. The higher frequency of periodontitis in a maxillary carnassial tooth (108) could be justified by the significative mechanical stress caused during mastication that can justify the nonbacterial etiology of periodontal lesions and the observed changes in alveolar bone mineral density (Tsutsumi et al., 2018).

4.4. Tooth fracture

The observation of fractures at the gingival level of a tooth is reported as very frequent in wild wolves (Vilà et al., 2008), however, in our study, these fractures were not frequently found. Valkenburgh (1988) refers that the most fractured teeth in African carnivores that consume bones, such as hyenas, are the canine teeth, followed by the premolars, first molars and incisive teeth. In Alaskan wolves, canines and premolars were found with fractures teeth in around half of the collection (Döring et al., 2018), in opposition to the data published by Losey, Jessup, Nomokonova, and Sablin (2014) who noted fractures in 27.8% of wolves teeth, mainly in maxillary incisors and canines. The same team refer that male wolves suffered more tooth fracture than females, being the Subarctic Russian wolves those having more females than males affected.

This dental abnormality was recently highlighted in Pleistocene carnivorans, being associated with the increase of bone consumption related with intensified interspecific competition when prey availability become scarce (Van Valkenburgh, Peterson, Smith, Stahler, and Vucetich, 2019). A study by Cuesta et al. (1991) report the analysis of stomach content and scats from specimens collected between 1970 and 1985 (partially covering the temporal range of our sampling) and mention that Iberian wolf diet varied much along the Spanish territory. Just the Sierra Morena population (south of Spain), which survival is nowadays uncertain (Álvares, 2011; López-Bao et al., 2015), preyed exclusively on large game. Iberian wolves largely rely on domestic species (Álvares, 2011; Petrucci-Fonseca, 1990), which are abundant in the geographical distribution of the Iberian wolf (meat availability and low levels of bone consumption) and this may contribute to the lower level of teeth fractures we detected in the collection examined.

4.5. Other observed abnormalities

Caries result from a bacterial decay of the tooth structure caused by acids from oral bacteria fermenting carbohydrates (Hale, 2009). Pavlović et al. (2007) observed that, in 34 skulls from wild wolves from Croatia, three animals (8.8%) showed signs of cavities at the mandibular molars. Our data contrasts this findings since cavities were not observed in any of the 1,280 maxillary and 1,309 mandibular teeth screened in this study. In fact, our result support the idea that cavities are rare in carnivores (Kyllar and Witter, 2005). In gray wolves, Döring et al. (2018) have just reported one carious lesion among 392 specimens. Hale (2009) founds that 5.25% of adult canine patients had one or more cavities. This low incidence is justified by the protective alkaline salivary pH and the existence of tooth crowns with secodont morphology (cutting edges on the cusps) where is more difficult to accumulate carbohydrates in the grooves, more typical in human bunodont teeth. Wild animals tend to feed on a more fibrous diet. In periods of food scarcity, gray wolves can consume fruits, berries and nuts (Ellis and Sloan, 2006).

Fusion of the teeth roots is a rare case, but we detected seven cases of such abnormality. We were unable to assess if there were adequate environmental conditions for a normal development of the teeth or not.

In the studied collection, supernumerary teeth and enamel hypoplasia were not identified, in opposition to data reported by Janssens et al. (2016) from Middle East wild wolves.

Regarding malocclusion, it was referred to be inexistent in Alaskan wolves (Döring et al., 2018), on contrary to the observed in an inbred wolf population from Scandinavia, where Raikkonen, Vucetich, Vucetich, Peterson, and Nelson (2013) found severe forms of malocclusion. Based on genetic data, the Iberian wolf population, in which only three cases of this condition were observed, is highly fragmented as showed by the statistically supported genetic clusters (Silva et al., 2018). Despite the surprisingly low dispersal level of these animals in Iberia, the inbreeding level across clusters is considered to be low, with only the groups South of Douro river and Alto Minho presenting mean relatedness values that would be expected for half-siblings (i.e., $r \geq 0.25$) (Silva et al., 2018).

4.6. Sex related dental alterations

We observed a significant relationship between periodontal disease and the sex of the specimen regarding teeth 104 in females and 308 in males. Canine teeth are most used to capture and tear prey's meat. Ellis and Sloan (2006) refer that in most cases females are the hunters since they are 20–25% smaller than males and therefore can run faster. In our study, no association was observed between tooth wear and sex, except in three teeth, corroborating what Döring et al. (2018) found for Alaskan wolves.

4.7. Tooth wear, fractures and periodontitis

In our study, we detected a significant association between periodontitis and tooth wear or fractures (for maxilla only). The main function of maxillary fourth premolars and mandibular first molars, known as carnassial teeth, is to break prey's large bones and grind fragments. We suggest that the pressure caused between teeth during hunting activities are the most frequent cause for fractures which can worsen dental wear and then cause periodontitis. No association between tooth wear and fracture was found.

In Schnauzer dog breed, periodontitis progression is known to be faster in older specimens (Marshall et al., 2014). As mentioned by Vilà et al. (2008), the number of fractures is related to the periodontal disease and increases with age, mainly as a result of dental mechanical trauma suffered during hunting and feeding behaviours throughout animal's life. Döring et al. (2018) found that periodontitis was significantly more frequent in adult wolves (75.0%) than in young individuals (41.9%).

4.8. Tooth and age estimation

Geiger and colleagues estimates dental maturity, according to completed eruption of permanent dentition, of 10 to 11 months in domestic dogs and 10 to 12 months in wolves (Geiger et al., 2016). However, dental maturation continues throughout the dog's life, even after eruption of permanent dentition, through secondary dentin deposition by odontoblasts leading to increased dentin thickness and decreased endodontic space width (Gorrel, 2004). As opposed to the histological evaluation of dentin layers, the analysis of dental radiographic images is not an invasive method, allowing to ascertain with great precision the age of the individuals, namely, by measuring the pulp canal vs root width ratio (PCR) (Kershaw, Allen, Lisle, and Withers, 2005), a method already applied by members of this team in mandibular first molars of client-owned Yorkshire Terrier dogs (Pereira et al., 2019).

Using data and approach implemented by the above-mentioned works (Gorrel, 2004; Pereira et al., 2019) we evaluated the age of some of the specimens screened for dental lesions. Based on the radiographic visualization of a single wide-open apex (ongoing rizogenesis) we

estimate that the specimens represented by Fig. 2.A-D are younger than 7 months old. For specimens shown on Figs. 2.E-H and 2.I-L, a confirmed apexogenesis and their wide root canals (PCR = 0.68 and 0.25, respectively) lead to estimate that these individuals are younger than 2 years old. On Fig. 2.M-H we can find adult wolves between 2 and 8 years old, as we can observe the presence of narrower canals (PCR = 0.11).

These results encourage future studies focusing on the analysis of the pulp canal vs root width ratio and its relationship with specimens' age in a captive breeding population of Iberian wolves. Considering that determination of the age in archeological remains is of major importance in Zooarchaeology, this non-destructive method for the tooth sample can generate baseline information for age estimation in archeological specimens -historic and prehistoric *Canis*, when teeth with roots are preserved.

5. Conclusion

Museum collections can provide access to crucial information about wild species concerning their oral health condition, especially in cases where individuals are difficult to capture or handle in the wild. Additionally, due to their time-series and cross-taxa collections, specimens from museums allow researchers to be able to evaluate the epidemiology of the certain pathologies across time and between related species.

Observed dental and periodontal abnormalities, like severe periodontitis or tooth fractures could be a cause of pain and discomfort which possibly led to difficulties in feeding and a general bad health condition in some wolves. The Iberian wolves studied revealed high frequency of periodontitis, although not severe on their majority and high frequency of tooth wear, which is in accordance to their food habits and feeding behavior, at least within the time range of almost 20 years interval (1977–1995) considered in the present work.

Our results showed that the application of dental radiography in the evaluation of museum specimens is of great relevance because it allows for a better diagnosis and classification of the dental pathology, specially from a historical perspective. Additionally, as highlighted in this study, it can be an important tool for zooarchaeologists in the identification of the approximate age of the *Canis* specimens when teeth roots are present.

To our knowledge, the present study is the first to be applied to the wild Iberian wolf population. The achieved results contribute to pave the way to identify a set of dental parameters to be assessed in live specimens when photos from the oral cavity are available. Since oral health has an impact in the global welfare of individuals, it would be important to include the studied parameters on the ongoing monitoring programs for this endangered species. The data collected, when analyzed in conjunction with ecological and genetic data, provides crucial information for wildlife and captive populations of wolves.

Author contributions

AEP and JFR conceived the idea; ISC, CV and JFR registered the dental abnormalities in the studied specimens; FPF and CBS were responsible for the selection of the museum collection; IV performed the statistical analysis; AEP, ISC and JFR wrote the paper with input from all authors.

Acknowledgments

The research leading to these results has received funding from the National Portuguese Foundation for Science and Technology (FCT grant 29545-02/SAICT/2017 - PTDC/HAR-ARQ/29545/2017). We thank Dr. Cleia Detry from UNIARQ - Centro de Arqueologia, Faculdade de Letras from Lisbon University (Lisbon, Portugal) for her insights and expertise in the analyses of museum specimens and to Mr. Rui Escudeiro from

Dentalvet-iM3 company for his support in the radiographic analysis. We also thank Dulce Silva Gould and Robert William Gould for the English revision of this manuscript.

Supplementary materials

Supplementary material associated with this article can be found, in the online version, at doi:10.1016/j.vas.2020.100100.

References

- Albuquerque, C., Morinha, F., Requiça, J., Martins, T., Dias, I., Guedes-Pinto, H., et al. (2012). Canine periodontitis: the dog as an important model for periodontal studies. *The Veterinary Journal*, 191(3), 299–305.
- Álvares, F. (2011). *Ecologia e conservação do lobo (Canis lupus, L.) no Noroeste de Portugal*. Lisbon: Faculdade de Ciências, University of Lisbon 193 PhD Thesis Conservation Biology.
- Arthur, C., Watt, K., Nussey, D. H., Pemberton, J. M., Pilkington, J. G., & Herman, J. S. (2015). Osteoarthritis of the temporo-mandibular joint in free-living Soay sheep on St Kilda. *The Veterinary Journal*, 203(1) 120–105.
- AVDC. (2016). *American veterinary dental college AVDC nomenclature [WWW document]*. URL <https://www.avdc.org/Nomenclature/Nomen-Intro.html>.
- Bannon, K. M. (2013). Clinical canine dental radiography. *Veterinary Clinics of North America: Small Animal Practice*, 43(3), 507–532.
- Barber-Meyer, S. (2012). Severe maxillary osteomyelitis in a gray wolf (*Canis lupus*). *Canadian Field-Naturalist*, 126(3), 238–241.
- Binder, W. J., & Van Valkenburgh, B. (2010). A comparison of tooth wear and breakage in Rancho La Brea sabertooth cats and dire wolves across time. *Journal of Vertebrate Paleontology*, 30(1), 255–261.
- Cabral, M. J., Almeida, J., Almeida, P. R., Delliger, T., Ferrand de Almeida, N., Oliveira, M., et al. (2005). *Livro vermelho dos vertebrados de Portugal*. Lisbon: Instituto da Conservação da Natureza (ICNF).
- Cabrera, A. (1907). Los lobos de España. *Boletín de la Real Sociedad Española de Historia Natural*, 7, 193–197.
- Chapron, G., Kaczensky, P., Linnell, J. D. C., von Arx, M., Huber, D., Andrén, H., et al. (2014). Recovery of large carnivores in Europe's modern human-dominated landscapes. *Science*, 346(6216), 1517–1519.
- Collados, J., Garcia, C., & Rice, C. A. (2018). Dental pathology of the Iberian lynx (*Lynx pardinus*). Part I: Congenital, developmental, and traumatic abnormalities. *Journal of Veterinary Dentistry*, 35(3), 195–208.
- Cuesta, L., Barcena, F., Palacios, F., & Reig, S. (1991). The trophic ecology of the Iberian wolf (*Canis lupus signatus*, Cabrera, 1907): A new analysis of stomach's data. *Mammalia*, 55(2), 239–254.
- Mech, L. D., & Boitani, L. (2007). *Wolves – Behavior, ecology, and conservation* (2nd ed.). Chicago: University of Chicago Press.
- de Lacerda, M. S., de Oliveira, S. T., & Queiroz, D. N. (2000). Anatomical variations in the dentition of mongrel domestic dogs. *Ciência Rural*, 30(4), 655–659.
- Döring, S., Arzi, B., Winer, J. N., Kass, P. H., & Verstraete, F. J. M. (2018). Dental and temporomandibular joint pathology of the grey wolf (*Canis lupus*). *Journal of Comparative Pathology*, 160, 56–70.
- Ellis, S., & Sloan, M. (2006). *Spirit of the Wolf* (3rd ed.). New York: Barnes and Noble.
- Geiger, M., Gendron, K., Willmitzer, F., & Sánchez-Villagra, M. R. (2016). Unaltered sequence of dental, skeletal, and sexual maturity in domestic dogs compared to the wolf. *Zoological Letters*, 2(1), 16.
- Gipson, P. S., Ballard, W. B., Nowak, R. M., & Mech, L. D. (2000). Accuracy and precision of estimating age of gray wolves by tooth wear. *The Journal of Wildlife Management*, 64(3), 752–758.
- Gorrel, C. (2004). Anatomy of the teeth and periodontium. In C. Gorrel (Ed.). *Veterinary dentistry for general practitioner* (pp. 30–33). Philadelphia: W.B. Saunders.
- Hale, F. A. (2009). Veterinary dentistry: dental caries in the dog. *Canadian Veterinary Journal*, 50(12), 1301–1304.
- Harvey, C. E. (1998). Periodontal disease in dogs. Etiopathogenesis, prevalence, and significance. *Veterinary Clinics of North America: Small Animal Practice*, 28(5), 1111–1128.
- Hindrikson, M., Remm, J., Pilot, M., Godinho, R., Stronen, A. V., Baltrūnaitė, L., et al. (2017). Wolf population genetics in Europe: A systematic review, meta-analysis and suggestions for conservation and management. *Biological Reviews*, 92(13), 1601–1629.
- Hoffmann, T., & Gaengler, P. (1996). Epidemiology of periodontal disease in poodles. *Journal of Small Animal Practice*, 37(7), 309–316.
- Janssens, L., Verhaert, L., Berkowic, D., & Adriaens, D. (2016). A standardized framework for examination of oral lesions in wolf skulls (*Carnivora: Canidae: Canis lupus*). *Journal of Mammalogy*, 97(4), 1111–1124.
- Kershaw, K., Allen, L., Lisle, A., & Withers, K. (2005). Determining the age of adult wild dogs (*Canis lupus dingo*, *C. l. domesticus* and their hybrids). I. pulp cavity:tooth width ratios. *Wildlife Research*, 32(6), 581–585.
- Kyllar, M., & Witter, K. (2005). Prevalence of dental disorders in pet dogs. *Veterinární Medicína – Czech*, 40(11), 496–505.
- Llaneza, L., López-Bao, J. V., & Sazatornil, V. (2012). Insights into wolf presence in human-dominated landscapes: The relative role of food availability, humans and landscape attributes. *Diversity and Distributions*, 18(5), 459–469.
- López-Bao, J. V., Blanco, J. C., Rodríguez, A., Godinho, R., Sazatornil, V., Álvares, F., et al.

- (2015). Toothless wildlife protection laws. *Biodiversity and Conservation*, 24(8), 2015–2018.
- Losey, R. J., Jessup, E., Nomokonova, T., & Sablin, M. (2014). Craniomandibular trauma and tooth loss in northern dogs and wolves: Implications for the archaeological study of dog husbandry and domestication. *PLoS ONE*, 9, e99746.
- MacKinnon, M. (2010). 'Sick as a dog': Zooarchaeological evidence for pet dog health and welfare in the roman world. *World Archaeology*, 42(2), 290–309.
- Marshall, M. D., Wallis, C. V., Milella, L., Colyer, A., Tweedie, A. D., & Harris, S. (2014). A longitudinal assessment of periodontal disease in 52 miniature schnauzers. *BMC Veterinary Research*, 1(10), 166.
- Newsome, T. M., Boitani, L., Chapron, G., Ciucci, P., Dickman, C. R., Dellinger, J. A., López-Bao, J. V., Peterson, R. O., Shores, C. R., Wirsing, A. J., & Ripple, W. J. (2016). Food habits of the world's grey wolves. *Mammal Review*, 46, 255–269.
- Niemiec, B. A. (2008). Oral pathology. *Top Companion Animal Medicine*, 23(2), 59–71.
- O'Neill, D. G., Church, D. B., McGreevy, P. D., Thomson, P. C., & Brodbelt, D. C. (2014). Prevalence of disorders recorded in dogs attending primary-care veterinary practices in England. *PLoS ONE*, 9(3), e90501.
- Park, K., Ahn, J., Kang, S., Lee, E., Kim, S., Park, S., et al. (2014). Determining the age of cats by pulp cavity/tooth width ratio using dental radiography. *Journal of Veterinary Science*, 15, 557–561.
- Pavlica, Z., Erjavec, V., & Petelin, M. (2001). Teeth abnormalities in the dog. *Acta Veterinaria Brno*, 70(1), 65–72.
- Pavlović, D., Gomerčić, T., Gužvica, G., Kusak, J., & Huber, Đ (2007). Prevalence of dental pathology in wolves (*Canis lupus* L.) in croatia: A case report. *Veterinarski Arhiv*, 77(3), 291–297.
- Pereira, J., Viegas, I., Venturini, M., Ferro, D., Corrêa, H., Matos, R., et al. (2019). Evaluating the relationship between age and pulp canal/ dental root ratio on dental X-rays of 53 yorkshire terrier dogs. In European Veterinary Dental Society (Ed.). *Proceedings book of the XXVIII European Veterinary Dental Forum* (pp. 147). Utrecht.
- Petrucci-Fonseca, F. (1990). *O lobo (Canis lupus signatus Cabrera, 1907) em Portugal. Problemática da sua conservação*. Lisbon: Faculdade de Ciências, University of Lisbon392 PhD Thesis in Ecology e Systematics.
- Raikkonen, J., Vucetich, J. A., Vucetich, L. M., Peterson, R. O., & Nelson, M. P. (2013). What the inbred Scandinavian wolf population tells us about the nature of conservation. *PLoS ONE*, 8, e67218.
- Rosenberg, H. M., Rehfeld, C. E., & Emmering, T. E. (1966). A method for the epidemiologic assessment of periodontal health-disease state in a beagle hound colony. *Journal of Periodontology*, 37(3), 208–213.
- Shelbourne, T. (2010). *Life and behaviour of wolves. Wolf teeth: dentition diseasee*. [WWW document]. UKWCT Wolf Print URL <https://ukwct.org.uk/files/education/WPEd39-wolf-teeth-dentition-and-diseasee.pdf>.
- Silva, P., López-Bao, J. V., Llaneza, L., Álvares, F., Lopes, S., & Blanco, J. C. (2018). *Scientific Reports*, 8, 14108.
- Szuma, E. (2014). Dental abnormalities in the red fox *Vulpes vulpes* from Poland. *Acta Theriologica*, 44(4), 393–412.
- Trouwborst, A. (2014). The EU habitats directive and wolf conservation and management on the Iberian peninsula: A legal perspective. *Galemys: Spanish Journal of Mammology*, 26, 5–30.
- Tsutsumi, T., Kajiya, H., Tsuzuki, T., Goto, K. T., Okabe, K., & Takahashi, Y. (2018). Micro-computed tomography for evaluating alveolar bone resorption induced by hyperocclusion. *Journal of Prosthodontic Research*, 62(3), 298–302.
- van Valkenburgh, B. (1988). Incidence of tooth breakage among large, predatory mammals. *The American Naturalist*, 131(2), 291–302.
- Valkenburgh, B., Peterson, R. O., Smith, D. W., Stahler, D. R., & Vucetich, J. A. (2019). Tooth fracture frequency in gray wolves reflects prey availability. *eLife*, 8, e48628.
- Vilà, C., Urios, V., & Castroviejo, J. (2008). Tooth losses and anomalies in the wolf (*Canis lupus*). *Canadian Journal of Zoology*, 71(5), 968–971.
- Winer, J. N., Liang, S. M., & Verstraete, F. J. M. (2013). The dental pathology of southern sea otters (*Enhydra lutris nereis*). *Journal of Comparative Pathology*, 149(2-3), 346–355.