



## Case Report

# A Case of Systemic Capillary Leak Syndrome With Severe Cardiac Dysfunction After mRNA Vaccination for COVID-19

Takashi Araki, MD, Ryota Morimoto, MD, PhD, Ryota Ito, MD, Takashi Mizutani, MD, Yuki Kimura, MD, Shingo Kazama, MD, Hideo Oishi, MD, Tasuku Kuwayama, MD, PhD, Hiroaki Hiraiwa, MD, PhD, Toru Kondo, MD, PhD, Takahiro Okumura, MD, PhD, and Toyoaki Murohara, MD, PhD

*Department of Cardiology, Nagoya University Graduate School of Medicine, Nagoya, Japan*

### ABSTRACT

A 53-year-old woman with no significant medical history developed cardiogenic shock 4 days after receiving the second dose of the COVID-19 mRNA vaccine (BNT162b2, Pfizer/BioNtech). The patient required extracorporeal membrane oxygenation and an Impella device. Based on significant hemoconcentration, decreased plasma protein levels, and pathologic findings in myocardial specimens, the patient was diagnosed with vaccination-induced fulminant systemic capillary leak syndrome (SCLS) with severe cardiac dysfunction. This case highlights that SCLS can occur after COVID-19 mRNA vaccination and may be associated with cardiac dysfunction. In patients with cardiogenic shock, hemoconcentration, and hypoalbuminemia after vaccination, SCLS should be considered.

### RÉSUMÉ

Une femme de 53 ans sans antécédents médicaux significatifs a subi un choc cardiogénique quatre jours après avoir reçu la deuxième dose du vaccin à ARNm contre la COVID-19 (BNT162b2, Pfizer/BioNtech). Elle a eu besoin d'une oxygénation extracorporelle et d'un dispositif d'assistance Impella. Compte tenu de l'hémoconcentration importante, des taux inférieurs de protéines plasmatiques et d'observations pathologiques sur les échantillons myocardiques, la patiente a reçu un diagnostic de syndrome de fuite capillaire systémique (SFCS) fulminant provoqué par la vaccination avec dysfonction cardiaque sévère. Ce cas montre que le SFCS, parfois associé à une dysfonction cardiaque, peut survenir après l'administration du vaccin à ARNm contre la COVID-19. Un SFCS doit donc être soupçonné chez les patients présentant un choc cardiogénique, une hémococoncentration et une hypoalbuminémie après la vaccination.

A 53-year-old woman received the second dose of the COVID-19 mRNA vaccine (BNT162b2, Pfizer/BioNtech) 4 days prior to admission. Fever occurred on the day after the vaccination and resolved 2 days later. However, her general malaise and loss of appetite worsened, requiring transportation to the emergency department of the initial hospital. On admission to the initial hospital, no other symptoms were present, such as hives, flushing, or conjunctival swelling, to suggest anaphylaxis. Systolic blood pressure was 66 mm Hg, and heart rate was 139 beats per minute. Hemoglobin, troponin-T, and brain natriuretic

peptide (BNP) levels were remarkably elevated (20.8 g/dL, 7.6 ng/mL, and 1676 pg/mL, respectively). Left ventricular ejection fraction was significantly reduced to 17%, with severe myocardial edema noted on echocardiogram. After infusion of noradrenaline (0.3 mcg/kg per hour) and dobutamine (1.8 mcg/kg per hour), an emergency coronary angiography revealed no coronary artery stenosis, and fulminant myocarditis (FM) was suspected. Intubation was achieved relatively easily, with no oral/buccal edema noted, and after insertion of extracorporeal membrane oxygenation (ECMO) and an intra-aortic balloon pump (IABP), the patient was transferred to our hospital. At the time of admission to our hospital, the peripheral extremities were cold, and systemic computed tomography showed no abnormalities other than whole-body edema, pericardial effusion, and a small amount of bilateral pleural effusion. Electrocardiography revealed low voltage and no ST-segment elevation (Fig. 1). Echocardiography showed diffuse severe hypokinesia and marked edema of the left and right ventricular myocardium (interventricular septum thickness: 12.0 mm; posterior left ventricular wall thickness:

Received for publication January 28, 2022. Accepted March 21, 2022.

**Ethics Statement:** This case report was conducted in accordance with the Helsinki Declaration and obtained the patient's written informed consent.

Corresponding author: Dr Ryota Morimoto, Department of Cardiology, Nagoya University Graduate School of Medicine, 65 Tsurumai-cho, Showa-ku, Nagoya, Aichi 466-8550, Japan. Tel.: +81-52-744-2147; fax: +81-52-744-2210.

E-mail: [ryota.m0726@med.nagoya-u.ac.jp](mailto:ryota.m0726@med.nagoya-u.ac.jp)

See page 658 for disclosure information.

### Novel Teaching Points

- In patients with cardiogenic shock after COVID-19 vaccination, SCLS with cardiac dysfunction, as well as FM, should be considered.

17.2 mm). Furthermore, no opening of the aortic valve was observed, owing to the afterload due to ECMO retrograde blood flow (Video 1, [view video online](#)). The intra-aortic balloon pump was replaced with an Impella CP (Abiomed, Danvers, MA) device to prevent left ventricular thrombosis and reduce the left ventricular end-diastolic pressure. At the time of Impella CP insertion, the activated partial thromboplastin time was significantly prolonged, reflecting coagulation abnormalities, despite the patient have not received heparin since her arrival. Three myocardial biopsies from the right ventricular septum were performed to differentiate myocarditis. Hematoxylin and eosin staining of the myocardial tissues revealed no inflammatory cell infiltration and limited injuries within the myocardium. Immunostaining also detected no immuno-positive cells (Fig. 2). A significant decrease in plasma proteins was detected, including albumin (0.8 g/dL), complement (C3: 12.2 mg/dL; C4: 4.5 mg/dL),  $\gamma$ -globulin (IgG: 184 mg/dL; IgA: 28 mg/dL; IgM: 30 mg/dL), and coagulation factors (prothrombin time-international normalized ratio: 1.75; antithrombin-III (AT-III): 26.0%; fibrinogen: 102 mg/dL), which reflected an increase in vascular permeability. Additionally, the blood pressure could not be maintained without a large dose of noradrenaline, even with sufficient ECMO flow, making us suspect a significantly decreased vascular resistance. We diagnosed the patient with systemic capillary leak syndrome (SCLS) with severe cardiac dysfunction based on decreased blood pressure, low albumin level, and hemoconcentration without inflammatory findings in myocardial pathology.

Intravenous corticosteroids (methylprednisolone, 500 mg twice a day) were administered for 3 days to improve vascular hyperpermeability and vascular resistance, in addition to

vasopressin for maintaining blood pressure. Starting the next day, cardiac function improved rapidly, and catecholamine and vasopressin levels were gradually reduced. On the fourth day, ECMO was removed, and the Impella CP was removed on the following day. Blood, sputum, and urine cultures of samples collected at admission, and various polymerase chain reaction tests for viruses in the myocardium, were all negative. Magnetic resonance imaging showed no evidence of late gadolinium enhancement. Although the patient's weight had increased by approximately 15 kg from baseline, it was rapidly improved by diuretics.

After progressive reduction in dosage, corticosteroids were discontinued on the 23rd day without re-exacerbation of cardiac dysfunction or altered hemodynamics. The left ventricular ejection fraction improved to 68%, although some pericardial effusion persisted (Video 2, [view video online](#)).

### Discussion

Although several reports have been made of FM after COVID-19 vaccination,<sup>1</sup> to the best of our knowledge, this is the first report of SCLS with severe cardiac dysfunction requiring mechanical circulatory support after COVID-19 mRNA vaccination.

SCLS is a rare disorder that can lead to multiple organ failure due to rapid extravasation of body fluids and plasma proteins owing to a potentially life-threatening transient hyperpermeability of the vascular endothelium. SCLS is characterized by episodes of severe hypotension, hypoalbuminemia, hemoconcentration, and systemic edema.<sup>2</sup> Previously, Juthier et al. reported a case in which myocardial injury was caused by excessive interstitial edema, as in our case.<sup>3</sup> Although a strict distinction between FM and SCLS is difficult to make, we finally diagnosed SCLS with severe cardiac dysfunction based on our findings of hemoconcentration and a marked reduction in plasma proteins. SCLS has been reported after patients received adenovirus vector (ChAdOx1 nCoV-19, Ad26.COV2.S) and mRNA (mRNA-1273, BNT162b2) vaccines against COVID-19.

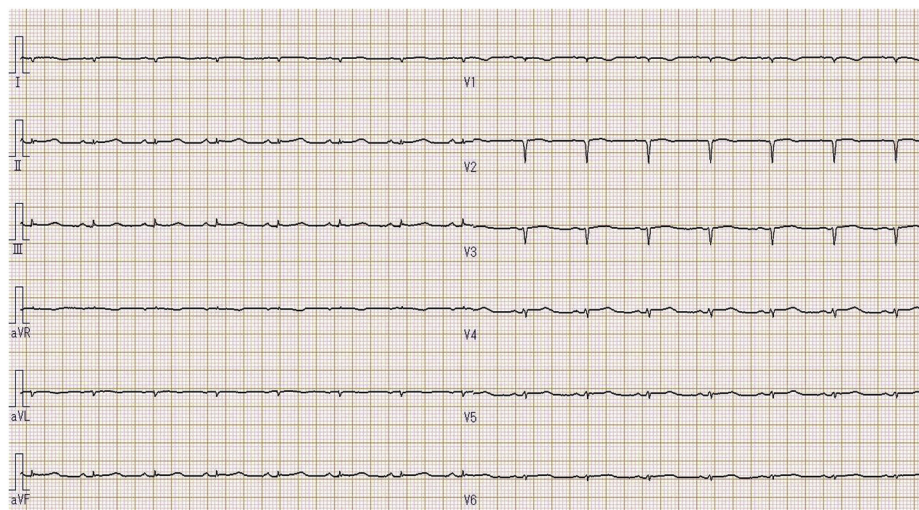
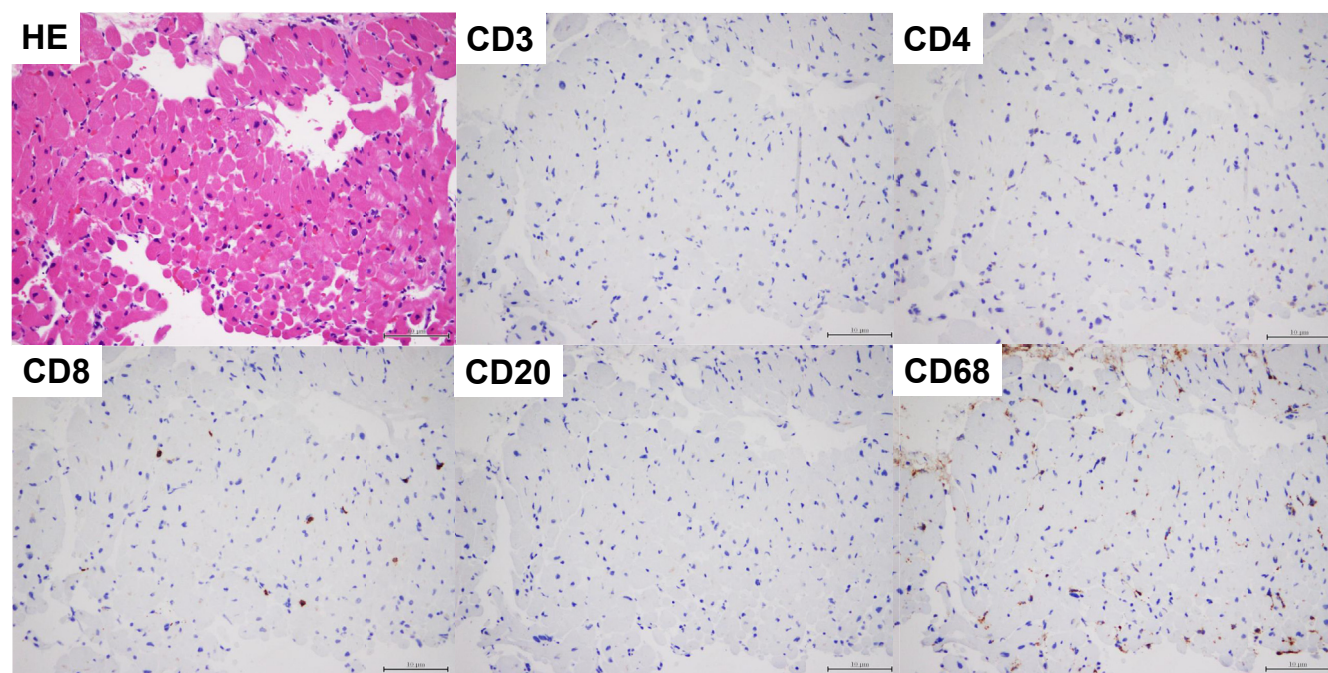


Figure 1. An electrocardiogram obtained after admission to our hospital revealed sinus rhythm with low voltage and no ST-segment elevation.



**Figure 2.** Hematoxylin and eosin (HE) staining of the myocardial tissue revealed no inflammatory cell infiltrates, eosinophils, or multinucleated giant cells, but showed limited injuries within the myocardium. Immunostaining also revealed the tissue to be CD3-negative, CD4-negative, CD8-negative, CD20-negative, and CD68-negative.

Although only one case of SCLS per 13 million ChAdOx1 nCoV-19 vaccine doses has been reported in Europe, the precise number of cases requiring mechanical circulatory support is unclear.<sup>4-6</sup> SCLS is reported to be caused by drugs such as human recombinant interleukin-2 (IL-2) and interferons, hematological malignancies, infectious diseases such as COVID-19 and influenza, and autoimmune diseases. Up to 79% of adult patients with SCLS have monoclonal gammopathy of undetermined significance (especially IgG kappa); however, such involvement was not detected in this case. The mortality rate of SCLS is 20%-30%, and treatment includes steroids and high-dose intravenous immunoglobulins.<sup>2</sup> The exact etiology of vaccine-associated SCLS remains unknown. After vaccination, a strong response of CD8+ and CD4+ T cells and production of interferon  $\gamma$  and IL-2 have been observed, and an association between IL-2 and SCLS has been reported.<sup>7</sup> Thus, immune response to the vaccination may be involved in SCLS; however, further research is needed to verify the cause.

In our patient, significant prolongation of activated partial thromboplastin time and reduction of plasma proteins, including coagulation factors such as antithrombin-III and fibrinogen, were observed at the time of admission. Although the cross-mixing test was not performed, all plasma protein levels normalized after recovery. Thus, we hypothesized that these issues were caused by the leakage of coagulation factors rather than production of autoantibodies. Multiglandular hormone deficiency has been reported in a patient with SCLS.<sup>8</sup> Although thyroid and adrenal hormone levels were normal after improvement of cardiac function in our patient, multiglandular hormones might have been deficient due to extravasation. Therefore, in addition to suppressing the immune response, as described above, prompt pulsed steroid

therapy might have been effective against adrenal insufficiency caused by extravasated proteins.

Even if no abnormalities are present, such as anaphylaxis, immediately after vaccination, attention should be paid to serious complications such as myocarditis and SCLS during the initial days after vaccination.

### Conclusion

FM-like hemodynamics can be caused by SCLS after COVID-19 mRNA vaccination.

### Funding Sources

Japan Society for the Promotion of Science (JSPS) KAKENHI, grant number JP22K08178 (to R.M.).

### Disclosures

The authors have no conflicts of interest to disclose.

### References

1. Abbate A, Gavin J, Madanchi N, et al. Fulminant myocarditis and systemic hyperinflammation temporally associated with BNT162b2 mRNA COVID-19 vaccination in two patients. *Int J Cardiol* 2021;340:119-21.
2. Bichon A, Bourenne J, Gannier M, Carvelli J. Capillary leak syndrome: state of the art in 2021. *Rev Med Interne* 2021;42:789-96.
3. Juthier F, Ennezat PV, Fornes P, et al. Myocardial involvement in systemic capillary leak syndrome: first demonstration by pathologic findings. *Eur Heart J Acute Cardiovasc Care* 2012;1:248-52.
4. Robichaud J, Côté C, Côté F. Systemic capillary leak syndrome after ChAdOx1 nCoV-19 (Oxford-AstraZeneca) vaccination. *CMAJ* 2021;193:E1341-4.

5. Choi GJ, Baek SH, Kim J, et al. Fatal systemic capillary leak syndrome after SARS-COV-2vaccination in patient with multiple myeloma. *Emerg Infect Dis* 2021;27:2973-5.
6. Matheny M, Maleque N, Channell N, et al. Severe exacerbations of systemic capillary leak syndrome after COVID-19 vaccination: a case series. *Ann Intern Med* 2021;174:1476-8.
7. Sahin U, Muik A, Vogler I, et al. BNT162b2 vaccine induces neutralizing antibodies and poly-specific T cells in humans. *Nature* 2021;595:572-7.
8. Then C, Ritzel K, Seibold C, Mann JFE, Reincke M. Multiglandular hormone deficiency in a patient with systemic capillary leak syndrome. *Case Rep Med* 2015;2015:958283.

### **Supplementary Material**

To access the supplementary material accompanying this article, visit *CJC Open* at <https://www.cjopen.ca/> and at <https://doi.org/10.1016/j.cjco.2022.03.008>.