

Lung Cancer Presenting as a Soft-Tissue Metastasis

Candice Baldeo Robert Ali Vandana Seeram Jeff House

University of Florida, Jacksonville, Fla., USA

Key Words

Lung cancer · Soft-tissue metastasis · Non-small-cell carcinoma · Computed tomography · Positron emission tomography · Magnetic resonance imaging

Abstract

Soft-tissue metastasis refers to the growth of cancer cells, originating from internal cancer, in soft tissues. In most cases, soft-tissue metastases develop after initial diagnosis of the primary internal malignancy and late in the course of the disease. In very rare cases, they may occur at the same time or before the primary cancer has been detected. In our cases, the soft-tissue metastases and the primary lung cancer were diagnosed at the same time.

© 2015 S. Karger AG, Basel

Introduction

Distant metastases to soft tissue (ST), defined as metastases to skeletal muscle and subcutaneous tissues, are rarely reported in the literature [1]. Autopsy series have reported ST metastasis in 0.75–9% of patients who died of metastatic carcinoma [2]. ST metastases from lung cancer are uncommon with a reported overall prevalence of 2.3% [3]. The detection of ST metastasis may affect staging and prognosis [2]. In both of the following cases, a single subcutaneous nodule was the initial presentation of the primary lung cancer.

Case 1

A 60-year-old Caucasian female presented with left hip pain for 5 months after falling off her bicycle. She was a chronic smoker with a 45-pack-year history. She also noted an unintentional 10-lb weight loss in the past month. On examination, she had decreased muscle

mass and looked cachectic. The left hip showed no evidence of trauma but demonstrated a decreased range of motion and was tender to palpation. Incidentally, a right scapular protruding mass was noted. It was about 4–5 × 4 cm, spherical, fixed and firm with no overlying skin changes, but it was mildly tender. It had been growing for the past 3 months.

A chest X-ray showed a right hilar mass. On computed tomography (CT) of the chest, abdomen and pelvis, there were several bilateral pulmonary nodules and a right suprahilar mass (fig. 1b), a mass in the left renal upper pole, a left thyroid lobe hypodensity, a right adrenal mass, a hepatic hypodensity as well as lytic lesions in the thoracic vertebrae.

A right upper lobe endobronchial mass biopsy was done, and pathology indicated a non-small-cell carcinoma which was not otherwise specified. However, the tissue sample was not adequate to differentiate which non-small-cell carcinoma it was.

A tissue biopsy of the right scapular mass (see fig. 1a, showing the right scapular mass on CT of the chest) showed a large-cell carcinoma which was poorly differentiated, favoring metastatic disease likely from the lung. A positron emission tomography (PET) scan revealed multiple hypermetabolic lesions involving multiple organ systems, including the right scapular mass, and all were consistent with metabolically active neoplasms. There were also multiple hypermetabolic lytic bone lesions including the pelvic bones, left scapula and left proximal femur.

During the hospital course, the patient developed gradual left-sided hemiparesis. Magnetic resonance imaging (MRI) of the brain showed multiple metastatic brain masses and extensive vasogenic edema. Steroids were started, but the patient did not improve. Repeat chest X-ray showed right upper lobe atelectasis which was likely secondary to the endobronchial mass.

The patient received palliative radiation therapy to the left hip, right lung and brain. She completed 5 cycles in total at each site and 4 treatments to the brain before passing away 1 month after her diagnosis.

Case 2

A 54-year-old male presented with right shoulder pain and back pain for the past 9 months. He also complained of an increasing mass in his right scapula during this time. He also had dyspnea on exertion but denied any cough, orthopnea or paroxysmal nocturnal dyspnea. He denied any weight loss. He also had a 40-pack-year history of smoking. MRI of the right shoulder showed a scapular mass with internal necrosis, mediastinal adenopathy and a right upper lobe lung mass. A CT of the chest showed a right upper lobe mass of approximately 6.0 × 6.0 × 3.5 cm, small bilateral pulmonary nodules and a large ST mass (7.3 × 5.5 × 6.8 cm) associated with lytic destruction of the inferior margin of the right scapula (fig. 2).

Bronchoscopy and biopsy of the right upper lobe mass revealed moderately differentiated adenocarcinoma. A CT of the head showed a 3.9 × 3.0 cm right frontal lobulated mass with surrounding edema. A PET scan revealed a hypermetabolic right upper lobe lung mass with metastases to the left lower lung lobe, right frontal cerebral lobe, left adrenal gland, right hilar and multistation mediastinal lymph nodes, the skull base, sacrum and right scapula. A biopsy of the right scapular ST mass was positive for metastatic adenocarcinoma, favoring a primary carcinoma from the lung.

The patient completed radiation to the brain and the base of the skull. Unfortunately, he developed worsening neurological function with inability to ambulate. Repeat MRI of the

brain showed acute infarcts. He was started on erlotinib and was discharged to inpatient hospice care. He passed away 6 months after diagnosis.

Discussion

Lung cancer is the leading cause of cancer-related deaths [1]. Approximately 50% of cases are metastatic at the time of diagnosis, and 60% of patients have microscopic or clinically evident metastasis at the time of primary tumor treatment. Lung cancer can metastasize to any organ. Major sites of metastases include the liver (33–40%), adrenal glands (18–38%), brain (15–43%), bone (19–33%), kidney (16–23%) and abdominal lymph nodes (29%) [1]. A prospective study by Salvatierra et al. [4] found that patients with adenocarcinoma or large-cell carcinoma were at a significantly higher risk for extrathoracic metastases compared with patients with squamous cell carcinoma.

The lung is the most common primary carcinoma site leading to clinically recognized ST metastases, followed by the kidney and colon [1]. Only 2 cases of lung cancer with metastasis to the ST in females have been reported. Both were non-small-cell lung cancers, the smoking status was unknown, and neither had ST metastasis as the sole presenting complaint [3].

ST metastases are perceived as a sign of advanced disease and are regarded as a grave prognostic indicator. Metastases from lung cancer are macroscopically indistinguishable from metastases of other cancers. Usually, they present as fast-growing solitary or multiple nodules with a diameter of 5 mm to 10 cm and are firm, mobile and covered with normal skin. Sometimes, exudative or ulcerative lesions are also seen [5]. They usually present as painless nodules [6]. The most frequently reported locations for ST metastasis have been the back, chest wall and abdomen [2].

Since subcutaneous metastasis from a primary lung cancer is unusual and ominous, our cases demonstrate how even a single, new subcutaneous lesion can represent serious occult pathology, thus warranting a low threshold for biopsy. They also demonstrate the importance of a good physical examination. The detection of ST metastasis may have prognostic implications, provide more accessible biopsy sites and help avoid invasive procedures. If detected earlier, maybe earlier treatment would have offered a better survival probability.

Rapid growth of skin nodules is an alarming sign of metastasis. Additionally, the significant weight loss in our female patient indicated a possible malignancy, together with the history of being a chronic smoker. Timely biopsy of the nodule is important in establishing diagnosis and initiating therapy.

References

- 1 Perisano C, Spinelli MS, Graci C, Scaramuzzo L, Marzetti E, Barone C, Fabbriani C, Maccauro G: Soft tissue metastases in lung cancer: a review of the literature. *Eur Rev Med Pharmacol Sci* 2012;16:1908–1914.
- 2 Nguyen NC, Chaar BT, Osman MM: Prevalence and patterns of soft tissue metastasis: detection with true whole-body F-18 FDG PET/CT. *BMC Med Imaging* 2007;7:8.
- 3 Sinha N, Niazi M, Diaz-Fuentes G, Duncalf R: An innocent appearing subcutaneous nodule diagnoses a small cell lung cancer in a never-smoker female. *Case Rep Oncol Med* 2014;2014:268404.
- 4 Salvatierra A, Baamonde C, Llamas JM, Cruz F, Lopez-Pujol J: Extrathoracic staging of bronchogenic carcinoma. *Chest* 1990;97:1053–1058.
- 5 Pathak S, Joshi SR, Jaison J, Kendre D: Cutaneous metastasis from carcinoma of lung. *Indian Dermatol Online J* 2013;4:185–187.
- 6 Hu S-S, Chen G-S, Lu Y-W, Wu C-S, Lan C-C: Cutaneous metastases from different internal malignancies: a clinical and prognostic appraisal. *J Eur Acad Dermatol Venereol* 2008;22:735–740.

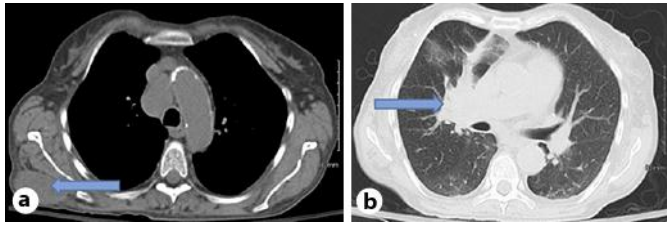


Fig. 1. a CT of the chest revealing the right ST mass. b CT of the chest with right suprahilar mass.

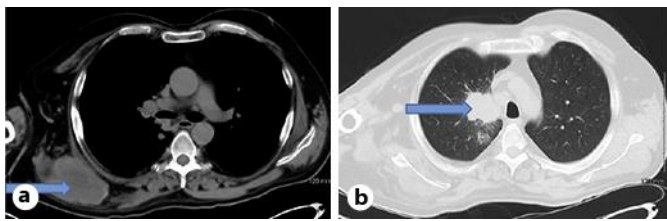


Fig. 2. a CT of the chest showing ST mass with lytic destruction of the inferior margin of the right scapula. b CT of the chest showing right upper lobe lung mass.