



Arthroscopic Subcoracoid Decompression, Coracoplasty, and Subscapularis Repair for Subscapularis Tears in the Setting of Subcoracoid Impingement

Stephanie S. Pearce, M.D., Joseph J. Ruzbarsky, M.D., Justin J. Ernat, M.D., M.H.A., Dylan R. Rakowski, B.S., Jared A. Hanson, B.A., and Peter J. Millett, M.D., M.Sc.

Abstract: Subscapularis tears have been found to occur in the setting of subcoracoid impingement and are related to the narrowing of the coracohumeral interval. The advancement of arthroscopic techniques has allowed for improved identification and treatment of this historically overlooked pathology. Challenges of arthroscopic subscapularis treatment include nearby neurovascular structures, tendon retraction, and adhesions, which are further complicated by diminished arthroscopic visualization, resulting from the concomitant subcoracoid impingement. The purpose of this Technical Note is to describe our preferred technique for arthroscopic management of subscapularis tears in the setting of subcoracoid impingement that is simple and reproducible, as well as cost-effective and efficient with limited additional morbidity to that of a standard diagnostic shoulder arthroscopy.

Introduction

Partial and complete subscapularis tears have been found to occur in the setting of subcoracoid impingement.¹⁻³ The normal value of the

coracohumeral distance has been estimated to range between 8.7 and 11 mm and the narrowing of this interval has been implemented in the development of subscapularis pathology and anterior shoulder pain.³⁻⁵ Historically, limited attention was paid to the subscapularis and its associated pathology. As arthroscopic techniques have progressed over the last 30 years, the identification and treatment of subscapularis injuries have become more common. Some challenges that have presented in the evolution of the treatment of subscapularis tears include its proximity to neurovascular structures, particularly when mobilization is required due to retraction and adhesion formation; and limited viewing within the subcoracoid space, especially when there is subcoracoid impingement present.⁶

Herein, we present a technique for arthroscopic management of subscapularis tears in the setting of subcoracoid impingement that is simple and reproducible in addressing the above historical concerns of treating subscapularis pathology in the coracohumeral interval. Research was performed at the Steadman Philippon Research Institute (Vail, CO).

The Steadman Clinic, Vail, Colorado, U.S.A. (S.S.P., J.J.R., P.J.M.); Steadman Philippon Research Institute, Vail, Colorado, U.S.A. (S.S.P., J.J.R., J.J.E., D.R.R., J.A.H., P.J.M.); and University of Utah Health, Salt Lake City, Utah, U.S.A. (J.J.E.).

The authors report the following potential conflicts of interest or sources of funding: D.R.R. reports personal fees from Steadman Philippon Research Institute, outside the submitted work. J.A.H. reports personal fees from Steadman Philippon Research Institute, outside the submitted work. S.S.P. is a consultant for Johnson & Johnson and received grant funding from Arthrex, Inc. J.J.E. is a consultant for Johnson & Johnson, Depuy Mitek Sports Medicine.

P.J.M. is a consultant for and receives royalties from Arthrex, Medbridge, and Springer; he owns stock in VuMedi, receives support from the Steadman Philippon Research Institute and Vail Valley Medical Center, and has corporate sponsorship from the Steadman Philippon Research Institute, Smith & Nephew, Arthrex, Siemens, and Össur. Full ICMJE author disclosure forms are available for this article online, as [supplementary material](#).

Received September 17, 2021; accepted October 28, 2021.

Address correspondence to Peter J. Millett, M.D., M.Sc., Steadman Philippon Research Institute, The Steadman Clinic, 181 W. Meadow Dr., Ste. 400, Vail, CO, 81657, U.S.A. E-mail: drmillett@thesteadmanclinic.com

© 2021 THE AUTHORS. Published by Elsevier Inc. on behalf of the Arthroscopy Association of North America. This is an open access article under the CC BY-NC-ND license (<http://creativecommons.org/licenses/by-nc-nd/4.0/>).

2212-6287/211336

<https://doi.org/10.1016/j.eats.2021.10.026>

Surgical Technique

A narrated video with demonstration of the surgical technique described may be reviewed ([Video 1](#)).

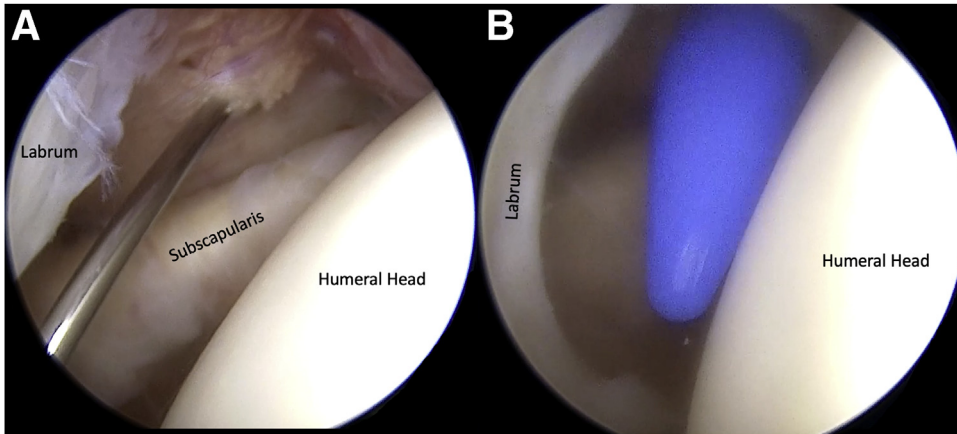


Fig 1. View of right shoulder from posterolateral portal with the patient in the beach chair position. (A) An 18-gauge spinal needle is used to establish the rotator interval portal and confirm appropriate trajectory and access to the coracoid tip. (B) A 5-mm cannula (Arthrex, Naples, FL) is then placed after a 5-mm skin incision is made with a #11 blade.

Patient Positioning and Anesthesia

In the preoperative holding area, an indwelling interscalene catheter is placed for postoperative pain control by the anesthesia pain service. After transfer to the operating room and induction of general anesthesia, the patient is positioned in the beach chair position with the head of the bed elevated to approximately 60°. A pneumatic arm positioner is used throughout the procedure.

Diagnostic Arthroscopy and Subcoracoid Space Debridement

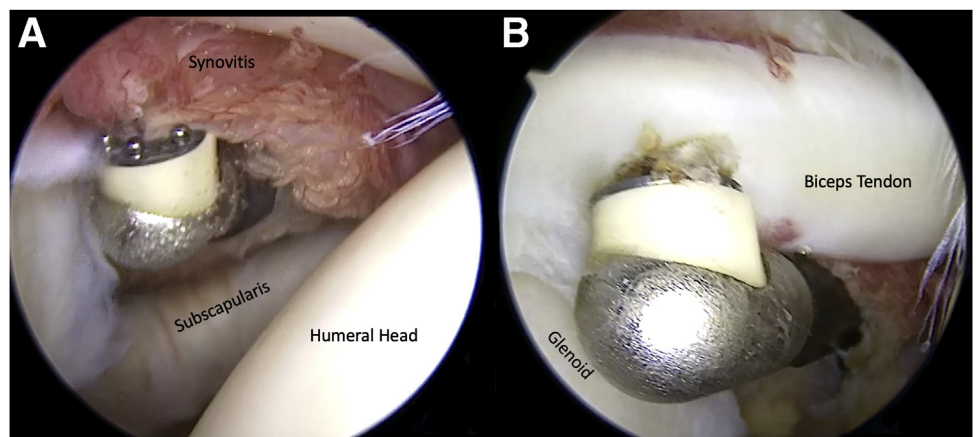
Following a surgical safety timeout, administration of antibiotics, and a preoperative examination under anesthesia, a posterior portal is established, and a comprehensive diagnostic arthroscopy is completed. Next, a rotator interval portal is established using an outside-in needle localization technique. This portal is purposely positioned both superiorly and laterally in the rotator interval to allow for ease of access to the subcoracoid space and coracoid. Prior to making a skin incision, an 18-gauge spinal needle is used in order to

confirm appropriate trajectory and access to the coracoid tip (Fig 1). A 5-mm cannula (Arthrex, Naples, FL) is then placed after a 7-mm skin incision is made with a #11 blade (Fig 1). A diagnostic arthroscopy is performed, and the pathoanatomy is identified in the upper border of the subscapularis tendon and long head biceps tendon. Next, using a combination of a 4.0-mm shaver and radiofrequency device, adhesions, thickened anterior capsule, and bursal tissue are carefully removed until the anterior border of the subscapularis tendon, as well as the entirety of the coracoid and conjoint tendon are completely visible (Fig 2). Additionally, a biceps tenotomy is carried out at this time using the radiofrequency device (Fig 2).

Subcoracoid Decompression and Coracoplasty

Next, a radiofrequency wand is used to skeletonize the posterior surface of the coracoid. Care is taken not to disturb the conjoint tendon. A 4.0-mm arthroscopic shaver is then used to perform a coracoplasty to create a space of at least 8 mm (Fig 3).

Fig 2. View of right shoulder from posterolateral portal with the patient in the beach chair position. (A) A bipolar radiofrequency device is introduced into the glenohumeral joint and used to ablate the synovitis around the subscapularis in the rotator interval and subcoracoid space. (B) A long head biceps tenotomy is performed utilizing the radiofrequency device.



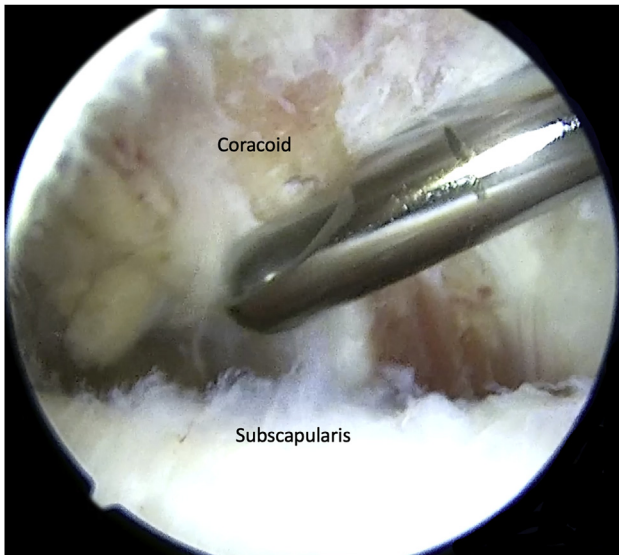


Fig 3. View of right shoulder from posterolateral portal with the patient in the beach chair position. A 4.0-mm arthroscopic shaver is then used to perform a coracoplasty.

Subscapularis Tendon Repair

While viewing the subscapularis tendon tear from the posterior portal using a 30-degree arthroscope, a 4.0-mm shaver is used on burr mode to lightly decorticate the superior portion of the lesser tuberosity in the region where the upper rolled border of the subscapularis tendon is torn to create a bleeding bone recipient site for tendon repair (Fig 4). Next, an 18-gauge spinal needle is placed percutaneously in a low anterior position and identified anterior to the subscapularis tendon. It is then passed through the subscapularis tendon in the desired location and identified intra-articularly. Next, the spinal needle stylet is removed and a #0 PDS suture is fed through the needle and retrieved using a grasping device through the anterior cannula after the spinal needle is carefully withdrawn (Fig 5). Next, the PDS suture is used to shuttle a

FiberTape suture (Arthrex, Naples, FL) through the subscapularis tendon (Fig 5). A 4.75-mm awl (Arthrex, Naples, FL) is then used to create a socket for an anchor in the previously decorticated subscapularis footprint in the lesser tuberosity (Fig 6). Both limbs of the previously passed FiberTape are then fed through the eyelet of a 4.75-mm polyetheretherketone SwiveLock anchor (Arthrex, Naples, FL). The SwiveLock anchor is then passed through the anterior portal into the piloted hole, each limb of the FiberTape is individually tensioned, and the anchor is inserted to restore the subscapularis tendon back to the lesser tuberosity (Fig 6). The FiberTape ends are then cut flush. Secure reduction and fixation are tested with an arthroscopic probe and during arm range of motion (Fig 7).

Procedure Completion and Closure

Next, the remaining intraarticular pathology of the rotator cuff and long head of the biceps tendon is addressed as needed. The biceps is tenodesed using a subpectoral technique, as described elsewhere.⁷ After copious irrigation, meticulous hemostasis is achieved, and the portals are closed using interrupted, buried absorbable sutures.

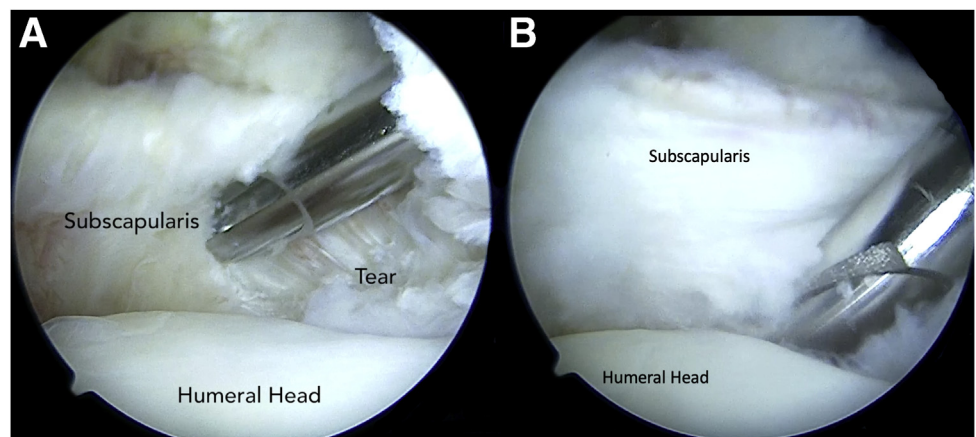
Postoperative Rehabilitation

A sling is used for 3 weeks. Physical therapy and passive range of motion with a 30-degree external rotation limit is started immediately. Full active range of motion commences at 3 weeks.⁸

Discussion

The presented technique allows the surgeon to perform a subcoracoid decompression and subscapularis repair using the standard portals for a diagnostic shoulder arthroscopy, a single knotless suture anchor, and percutaneous access with a spinal needle resulting in a safe, efficient, and cost-effective method for this historically challenging pathology. There have

Fig 4. View of right shoulder from posterolateral portal with patient in the beach chair position. The subscapularis tendon is visualized (A) and a 4.0-mm shaver is used to lightly decorticate the superior portion of the lesser tuberosity to create a bleeding bone recipient site for tendon repair (B).



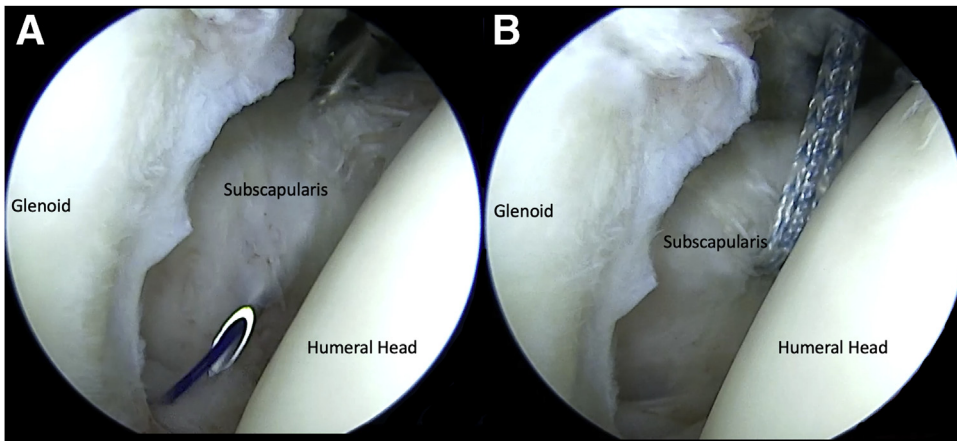


Fig 5. View of right shoulder from posterolateral portal with the patient in the beach chair position. (A) An 18-gauge spinal needle is placed percutaneously through the subscapularis tendon, and a #0 PDS suture is fed through the needle. (B) The PDS suture is used to shuttle a FiberTape suture (Arthrex, Naples, FL) through the subscapularis tendon.

been numerous techniques published regarding arthroscopic treatment of subscapularis pathology; however, we believe that this technique is both simple and reproducible with excellent results, as reported by Katthagen et al. and others.⁹⁻¹⁸ Additionally, our stepwise approach with decompression of the subcoracoid space allows for safe manipulation of the subscapularis tendon in proximity to the neurovascular structures medially and inferiorly.

Barlow et al. have also described a single portal technique; however, their usage of a 25° QuickPass SutureLasso (Arthrex, Naples, FL) device is not as cost-effective, and more user-dependent than simply introducing a spinal needle into the location of the tendon, where suture-passage is desired.¹⁰ The spinal needle method avoids the cost of other high-end suture passing devices that some authors have advocated, and it also negates the need for establishment of an anterosuperolateral portal, as is described by Howlett et al.¹³ Although most subscapularis tears associated with subcoracoid impingement can be treated with the technique described in this article, the same methods can be applied to larger tears, for which a double-row

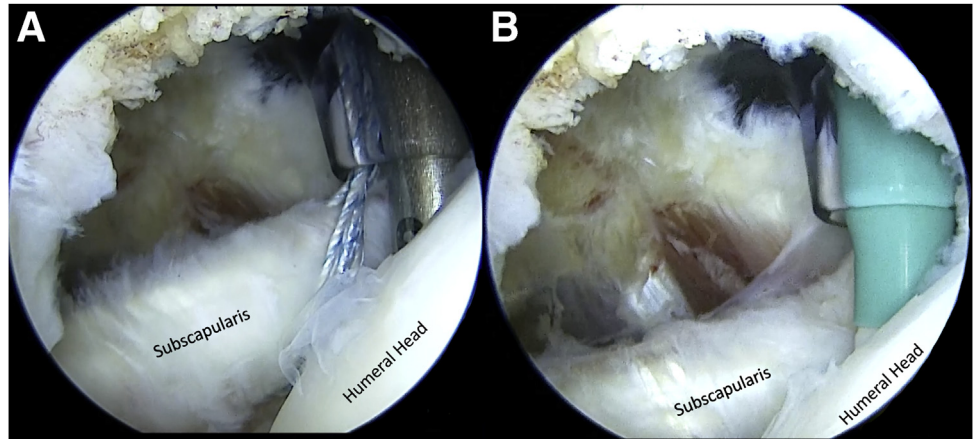
technique and multiple rows of linked anchors can be used.¹¹ Lastly, there is no need for knot-tying, which creates more consistency,¹⁹ decreases the risk for soft tissue irritation, and reduces the risk for loss of repair tension.¹⁷ Several other techniques have been presented; however, they have similar pitfalls as mentioned above.^{12,15}

While the benefits of our presented technique are evident as discussed above, there are also technical pitfalls that, if not avoided, can potentially make decompression and repair very challenging (Table 1). If the anterosuperior portal is established in a too medial or too superior of a position, it can be challenging to perform an adequate decompression and coracoplasty. Therefore, a midlateral placement of this portal is warranted. Medial and/or inferior placement may also prohibit appropriate angulation of the suture anchor insertion. Additionally, if attention is not paid to the coracohumeral distance, the inadequate coracoplasty or failure to perform a coracoplasty can make instrumentation difficult within the space anteriorly. If visualization or instrumentation is still difficult, we have a low threshold to employ a 70° arthroscope to view the

Table 1. Pearls and Pitfalls

Pearls	Pitfalls
When a coracoplasty is considered based upon preoperative imaging, the anterior portal should be positioned more laterally to provide an appropriate trajectory for instruments to reach the posterior aspect of the coracoid.	Placement of the anterior portal in a medial position will make both the debridement of tissue anterior to the subscapularis and the coracoplasty difficult.
A gentle posterior force on the proximal humerus by an assistant is helpful to increase the working space for anterior capsular debridement, subscapularis repair, and coracoplasty. A 70° scope can also be helpful to improve visualization.	When placing the anterior cannula, resistance may be encountered if penetrating the coracoacromial ligament (CAL). If encountered, the cannula tip should be redirected inferiorly to avoid CAL penetration.
A thorough debridement of the anterior rotator interval, scar, and capsule anterior to the subscapularis tendon is necessary prior to suture passage through the subscapularis tendon.	Subcoracoid impingement is considered a space between the coracoid tip and the subscapularis of less than 8 mm. Failure to increase this distance can make placing instrumentation difficult within the space anteriorly.
A 70° arthroscope can be used from the posterior portal if visualization of the subcoracoid space is impaired or difficult.	

Fig 6. View of right shoulder from posterolateral portal with the patient in the beach chair position. (A) A 4.75-mm awl (Arthrex, Naples, FL) is used to pilot a hole in the previously decorticated subscapularis footprint in the lesser tuberosity. (B) The FiberTape suture is then fed through the eyelet of a 4.75-mm polyetheretherketone SwiveLock anchor (Arthrex, Naples, FL), and the anchor is deployed for repair of the subscapularis tendon back to the insertional footprint.



subscapularis tendon insertional footprint on the lesser tuberosity, and we use an assistant to apply a posterior-directed force on the humerus to improve our working field.

Although this is a comparatively safe technique to address subscapularis pathology, the procedure is not without risk. Risks associated with this technique align with other approaches to arthroscopic management of subscapularis tears and include the potential for neurovascular injury with inferior and/or medial release of the subscapularis tendon, as well as instrumentation of these regions.⁶ There is also a low risk of proximal humerus fracture with anchor placement. Additionally, if the tear is at the musculotendinous junction or the tendon is severely retracted, addressing the pathology may require an open approach rather than the arthroscopic technique described in this Technical Note.

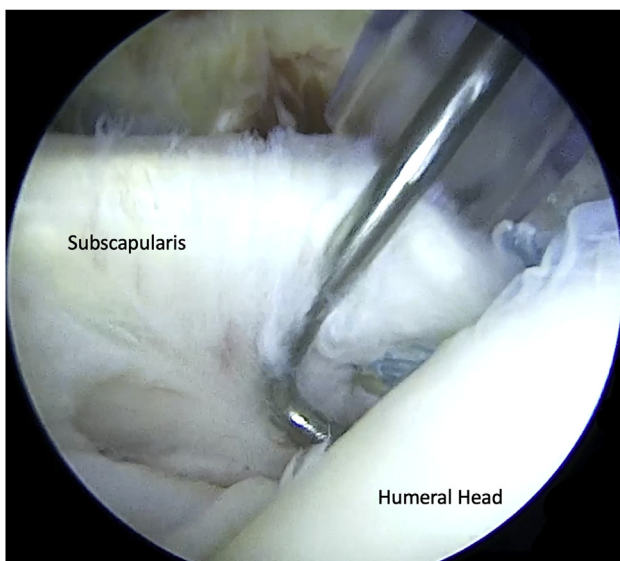


Fig 7. View of right shoulder from posterolateral portal with the patient in the beach chair position. Secure reduction and fixation are tested with an arthroscopic probe.

Pathology of the rotator interval structures is often interconnected.²⁰ Impingement between the coracoid and the lesser tuberosity can be a source of shoulder pain as well as cause injury to the subscapularis and anterosuperior rotator cuff. Other rotator interval structures can also become involved, including biceps pulley lesions or subscapularis tears that lead to biceps instability and tendonitis or tearing.²⁰ Our described technique aims to address all of these concomitant pathologies. Clinical outcomes using this technique have been previously reported with excellent results at a minimum of 2-year follow-up.¹⁴ Single-anchor repair of the subscapularis with biceps tenodesis resulted in American Shoulder and Elbow Surgeons (ASES) scores of 93.7 in Lafosse type II tears, and 86.7 in Lafosse type I tears. In a series by Vap et al., 14 patients with biceps reflection pulley lesions treated with subpectoral biceps tenodesis achieved excellent outcomes, including improvements in ASES, Quick Disabilities of the Arm Shoulder and Hand, and Short-Form-12 Physical Component Scores.²¹

In conclusion, we present a technique for arthroscopic management of subscapularis tears in the setting of subcoracoid impingement that is simple and reproducible, as well as cost-effective and efficient with limited additional morbidity to that of a standard diagnostic shoulder arthroscopy.

References

1. Lo IK, Burkhart SS. The etiology and assessment of subscapularis tendon tears: A case for subcoracoid impingement, the roller-wringer effect, and TUFF lesions of the subscapularis. *Arthroscopy* 2003;19:1142-1150. <https://doi.org/10.1016/j.arthro.2003.10.024>.
2. Lo IK, Parten PM, Burkhart SS. Combined subcoracoid and subacromial impingement in association with anterosuperior rotator cuff tears: An arthroscopic approach. *Arthroscopy* 2003;19:1068-1078. <https://doi.org/10.1016/j.arthro.2003.10.016>.

3. Richards DP, Burkhart SS, Campbell SE. Relation between narrowed coracohumeral distance and subscapularis tears. *Arthroscopy Oct* 2005;21:1223-1228. <https://doi.org/10.1016/j.arthro.2005.06.015>.
4. Friedman RJ, Bonutti PM, Genz B. Cine magnetic resonance imaging of the subcoracoid region. *Orthopedics* 1998;21:545-548.
5. Gerber C, Terrier F, Zehnder R, Ganz R. The subcoracoid space. An anatomic study. *Clin Orthop Relat Res* 1987;(215):132-138.
6. Kuntz AF, Raphael I, Dougherty MP, Abboud JA. Arthroscopic subscapularis repair. *J Am Acad Orthop Surg Feb* 2014;22:80-89. <https://doi.org/10.5435/jaaos-22-02-80>.
7. Pogorzelski J, Horan MP, Hussain ZB, Vap A, Fritz EM, Millett PJ. Subpectoral biceps tenodesis for treatment of isolated type II SLAP lesions in a young and active population. *Arthroscopy* 2018;34:371-376. <https://doi.org/10.1016/j.arthro.2017.07.021>.
8. Altintas B, Bradley H, Logan C, Delvecchio B, Anderson N, Millett PJ. Rehabilitation following subscapularis tendon repair. *Int J Sports Phys Ther* 2019;14:318-332.
9. Arun GR, Kumar P, Patnaik S, et al. Outcome of arthroscopic subscapularis tendon repair: Are the results improving with improved techniques and equipment?: A retrospective case series. *Indian J Orthop* 2016;50:297-302. <https://doi.org/10.4103/0019-5413.181788>.
10. Barlow JD, Everhart JS. Arthroscopic subscapularis repair through a single anterior portal. *Arthrosc Tech* 2017;6:e1593-e1598. <https://doi.org/10.1016/j.eats.2017.06.014>.
11. Cabarcas BC, Garcia GH, Liu JN, Gowd AK, Romeo AA. Double-row arthroscopic subscapularis repair: A surgical technique. *Arthrosc Tech* 2018;7:e805-e809. <https://doi.org/10.1016/j.eats.2018.03.020>.
12. Gilmer BB, Crall TS, Guttmann D. Knotless arthroscopic repair of subscapularis tendon tears using looped suture. *Arthrosc Tech* 2015;4:e267-e271. <https://doi.org/10.1016/j.eats.2015.02.009>.
13. Howlett N, Parisien RL, Son SJ, Li X. Arthroscopic subscapularis repair using a clever hook and lasso loop technique in the beach chair position: A simple and reproducible guide. *Arthrosc Tech* 2021;10:e199-e208. <https://doi.org/10.1016/j.eats.2020.09.030>.
14. Katthagen JC, Vap AR, Tahal DS, Horan MP, Millett PJ. Arthroscopic repair of isolated partial- and full-thickness upper third subscapularis tendon tears: Minimum 2-year outcomes after single-anchor repair and biceps tenodesis. *Arthroscopy* 2017;33:1286-1293. <https://doi.org/10.1016/j.arthro.2017.01.027>.
15. Nelson CG, Field LD. Arthroscopic subscapularis repair using a subacromial view. *Arthrosc Tech May* 2020;9:e599-e602. <https://doi.org/10.1016/j.eats.2020.01.011>.
16. Nystrom S, Fagan P, Vedder K, Heming J. Subscapularis repair with the suture shuttle loop technique. *Arthrosc Tech* 2013;2:e31-e33. <https://doi.org/10.1016/j.eats.2012.10.006>.
17. You JS, Monroe EJ, Friedman JM, et al. Arthroscopic single-portal subscapularis tendon repair. *Arthrosc Tech* 2020;9:e1447-e1452. <https://doi.org/10.1016/j.eats.2020.06.005>.
18. Monroe EJ, Flores SE, Chambers CC, et al. Patient-reported outcomes after isolated and combined arthroscopic subscapularis tendon repairs. *Arthroscopy* 2019;35:1779-1784. <https://doi.org/10.1016/j.arthro.2019.01.034>.
19. Hanypsiak BT, DeLong JM, Simmons L, Lowe W, Burkhart S. Knot strength varies widely among expert arthroscopists. *Am J Sports Med* 2014;42:1978-1984. <https://doi.org/10.1177/0363546514535554>.
20. Gaskill TR, Braun S, Millett PJ. The rotator interval: Pathology and management. *Arthroscopy Apr* 2011;27:556-567. <https://doi.org/10.1016/j.arthro.2010.10.004>.
21. Vap AR, Katthagen JC, Tahal DS, et al. Isolated biceps reflection pulley tears treated with subpectoral biceps tenodesis: Minimum 2-year outcomes. *Arthroscopy* 2017;33:1788-1794. <https://doi.org/10.1016/j.arthro.2017.04.021>.