

The Pink Pad: A Method of Post-Free Distraction During Hip Arthroscopy



Allison K. Perry, B.S., Safa Gursoy, M.D., Ph.D., Harsh Singh, B.A., Amar S. Vadhera, B.S.,
Nabil Mehta, M.D., and Jorge Chahla, M.D., Ph.D.

Abstract: Distraction is essential during hip arthroscopy to allow for adequate working space during central and peripheral compartment procedures. Pudendal posts are frequently used with traction boots to achieve distraction, but use of these posts is believed to be associated with the iatrogenic pudendal area and perineal nerve injuries seen with hip arthroscopy. Current post-free distraction tables are costly and cumbersome. The pink pad positioning device allows for post-free distraction through the creation of friction between the patient, the pad, and the bed. This device can be used with a standard hip arthroscopy table, is easy to learn, allows for adequate distraction, and allows for greater access to the femoral neck during osteochondroplasty, as there is less restriction of the patient's range of motion without a post present. The purpose of this Technical Note is to describe a method of post-free distraction using the pink pad positioning device.

The use of hip arthroscopy has increased dramatically in the past 2 decades, with studies showing as much as 495% increase in the procedure from 2004 to 2016.¹⁻³ During hip arthroscopy, a pudendal post is routinely used between the patient's legs to aid in distraction and to keep the patient securely positioned throughout the duration of the procedure. Use of these posts has been associated with complications, however, such as perineal and pudendal nerve injury, which can lead to sexual and urinary dysfunction.⁴ Other reported perineal injuries in hip arthroscopy include scrotal and vulvar tears, hematomas, and skin necrosis, all of which can be avoided through proper padding of the post or not using the post.⁵ Although

post-free options have begun to gain popularity, they come with their own set of challenges—the equipment is often costly and requires surgeons and operating room staff to adopt a new and different setup from what is typically used.⁶ Despite these drawbacks, previous studies have found post-free distraction to be a safe alternative to use of a pudendal post.^{5,7-9}

To avoid the high cost and learning curve of currently available post-free distraction systems, the same effect can be achieved through use of a pink pad positioning device, which prevents movement of the patient during surgery through friction between the pad and the patient's skin and the pad and a standard hip arthroscopy table. In this Technical Note, we present our technique of using a cost-conscious, user-friendly pink pad positioning device (Xodus Medical Pink Hip Kit; Smith & Nephew, Andover, MD) for post-free distraction during hip arthroscopy.

Technique (With Video Illustration)

Patient Positioning

This technique is compatible with any currently used hip-distraction table used for hip arthroscopy. The pink pad is placed on top of bed and is first secured to a distractor system table (Smith & Nephew) using a wide Velcro strap attached to the underside of the pad (Video 1). The rest of the pad is secured to the Bucky arms of the bed using thin Velcro straps that are attached to the underside of the pad (Fig 1). A draw sheet is placed on top of the pad, and separate safety

From the Division of Sports Medicine, Midwest Orthopaedics at Rush, Rush University Medical Center, Chicago, Illinois, U.S.A.

The authors report the following potential conflicts of interest or sources of funding: J.C. reports other from Arthrex and Smith & Nephew, outside the submitted work; board or committee member: American Orthopaedic Society for Sports Medicine, Arthroscopy Association of North America, International Society of Arthroscopy, Knee Surgery, and Orthopaedic Sports Medicine; paid consultant: Arthrex, CONMED Linvatec, Smith & Nephew, and Ossur. Full ICMJE author disclosure forms are available for this article online, as supplementary material.

Received February 23, 2021; accepted April 3, 2021.

Address correspondence to Allison K. Perry, B.S., 1611 W Harrison St., Chicago, IL 60612. E-mail: akperry13@gmail.com

© 2021 THE AUTHORS. Published by Elsevier Inc. on behalf of the Arthroscopy Association of North America. This is an open access article under the CC BY-NC-ND license (<http://creativecommons.org/licenses/by-nc-nd/4.0/>).

2212-6287/21306

<https://doi.org/10.1016/j.eats.2021.04.013>

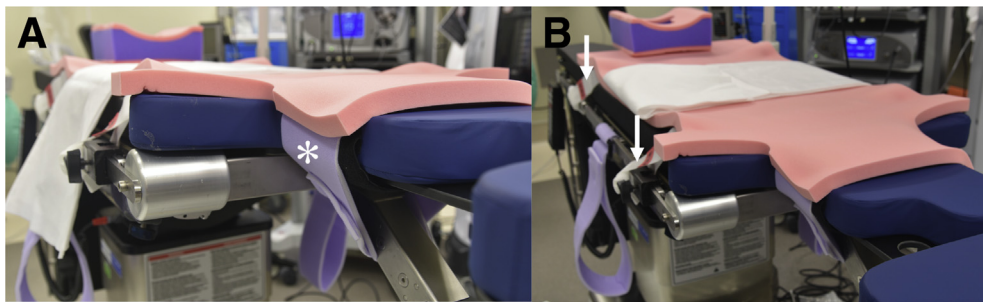


Fig 1. Pink pad bed attachments. The pink pad is first secured to the Smith & Nephew bed attachment with the wide purple Velcro strap (*) that is attached to the underside of the pad (A). The remainder of the pad is then attached to the Bucky arms of the bed using thin white Velcro straps (arrows) that are also attached to the underside of the pad (B).

straps are attached to the Bucky arms. The patient is then moved onto the operating bed, is prepared under general anesthesia in a supine position, and moved distally so that the anterior superior iliac spine is in line with the widest portion of the Smith & Nephew attachment (Fig 2). With this position, the patient is in the same location as he or she would be when a post is present. The patient is moved as necessary by lifting the patient off the pad as the patient cannot be slid while on the pad. The draw sheet is then removed from under the patient to maximize contact with the pink pad (Fig 3, Video 1).

After the patient has been appropriately positioned, the patient's arms may be folded across the chest and secured with safety straps and tape. The surgeon may also choose to have the patient's arm on the surgical side secured across the chest while the contralateral arm rests on an arm board. When positioning the arm, special care must be taken to protect the ulnar nerve and bony prominences, which can be accomplished with ulnar nerve pads (Video 1). The patient's feet are then placed in traction boots, and the boot on the operative side is

secured with Coban. After positioning the patient in 10 to 15° Trendelenburg position with the leg adducted and the foot internally rotated to create initial traction, a C-arm is used to ensure no artifact is present in the fluoroscopy field, and the patient is prepped and draped in standard fashion (Fig 4, Video 1). After marking the greater trochanter outline and the location of the anterior superior iliac spine using a skin marker, portal locations (modified mid-anterior, anterolateral, and distal anterolateral) are marked.

Maintaining the Joint Traction and Hip Arthroscopy of the Compartments

Under fluoroscopy, the suction seal is disrupted using an air arthrogram (60 cc) with an 18-gauge needle (Fig 5, Video 1). Maximum traction of at least 1 cm is then achieved by adjusting the distal traction arm

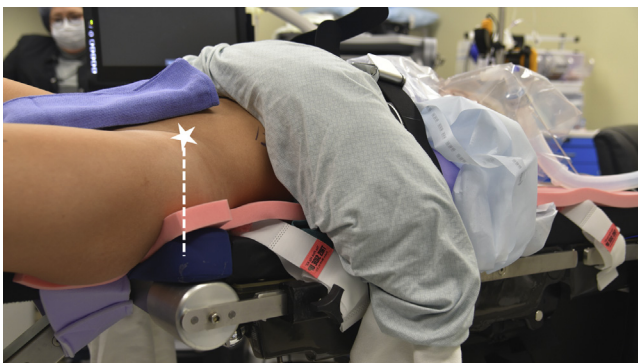

Fig 2. Alignment of the ASIS with the Smith & Nephew bed attachment. The patient is moved in the caudad direction on the bed until the ASIS (star) is aligned with the widest part of the Smith & Nephew bed attachment, as shown with the left hip of this patient in the supine position. (ASIS, anterior superior iliac spine.)

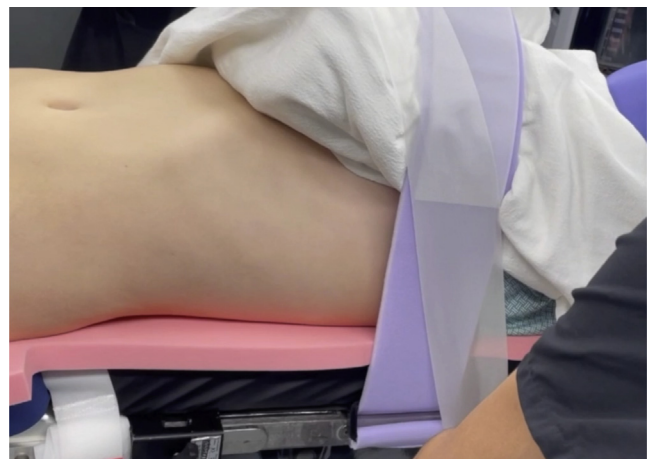

Fig 3. Maximized patient contact with pink pad. After removal of the draw sheet, the patient's skin should have as much contact with the pink pad as possible to create friction and to prevent movement throughout the procedure, as shown with this patient in the supine position prior to left-sided hip arthroscopy. This can be accomplished by removing the draw sheet and pulling the patient's gown out to the side.

Fig 4. Lower-limb traction positioning. To achieve adequate distraction of the hip joint, the foot on the surgical side is secured in a traction boot with Coban (*), adducted, and internally rotated, as demonstrated for this patient prior to left-sided hip arthroscopy. A C-arm can then be used to ensure distraction.

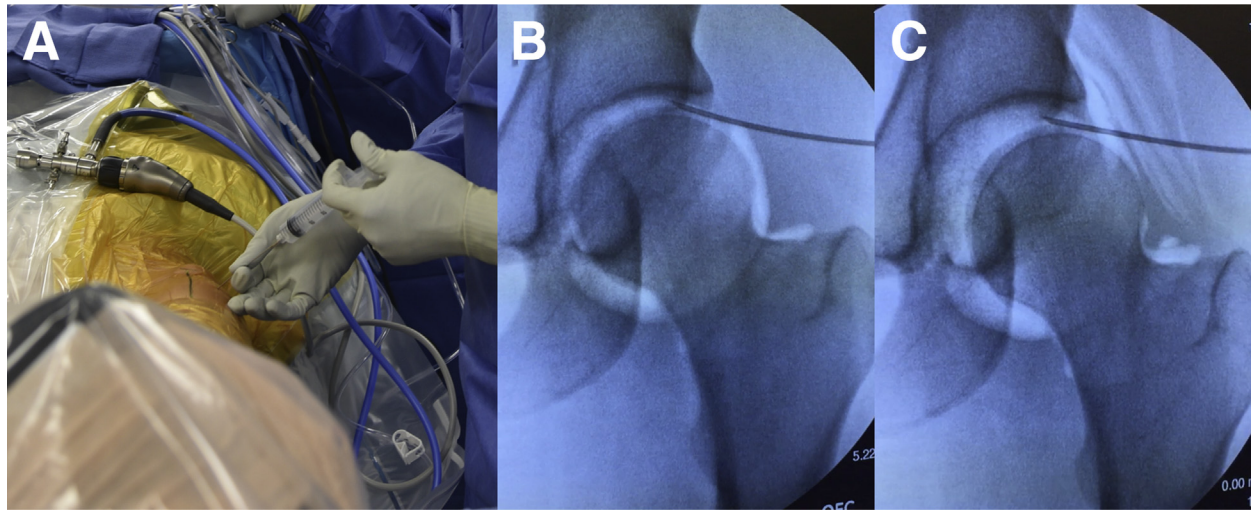
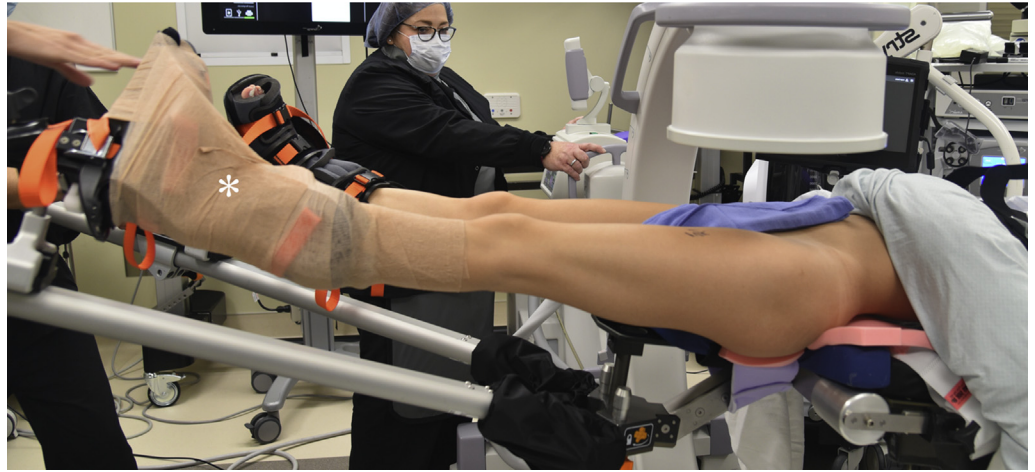

Fig 5. Disruption of the suction seal. After initial distraction is achieved, an air arthrogram is performed to disrupt the suction seal using a 60-cc syringe with an 18-gauge needle (A), as shown in this patient's left hip. This process is performed under fluoroscopy to ensure successful disruption comparing (B) before and (C) after air arthrogram.

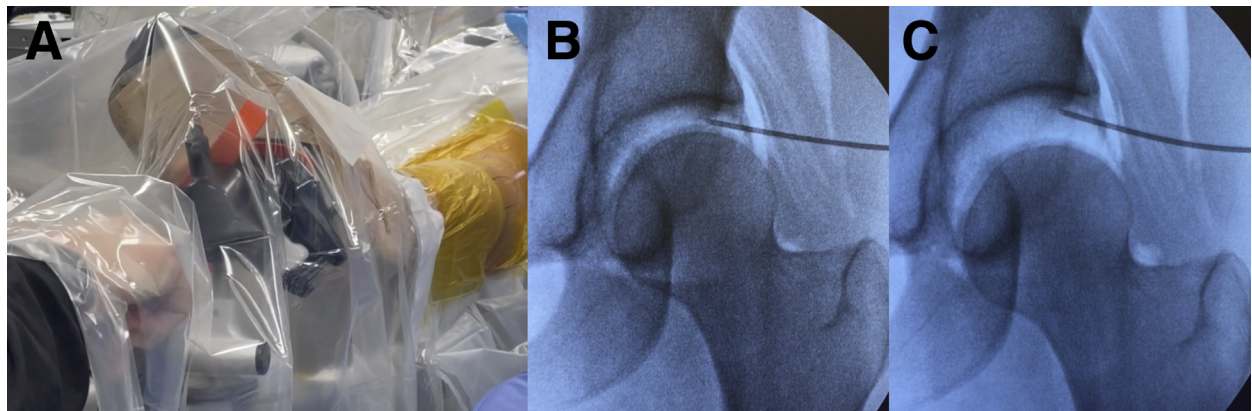


Fig 6. Ensuring proper joint traction. Manual traction is applied through the distal traction arm (A) and fluoroscopically confirmed by comparing before (B) and after (C) rotating the distal traction arm, as shown in this patient's left hip.

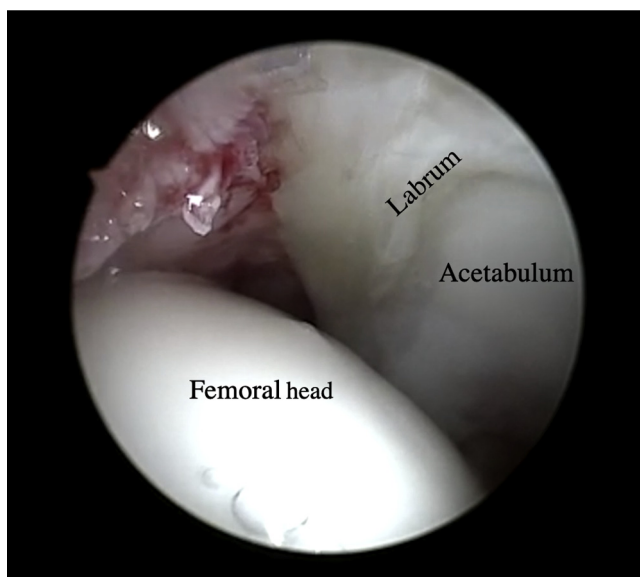


Fig 7. Arthroscopic view of the hip joint with adequate joint distraction. Adequate joint distraction allows for proper viewing of the central compartment for diagnostic arthroscopy, rim trimming, labral repair, and other indicated procedures, as demonstrated through the anterolateral viewing portal in this left hip.

(Fig 6). At this point, the C-arm should be in proper position to take anteroposterior views of the hip throughout the procedure, with the center of the fluoroscopic image being the ischium. To ensure proper visualization throughout the procedure, the AL portal is made just anterior to the greater trochanter, either at the same level in the sagittal plane or slightly superior to the greater trochanter. The modified mid-anterior portal is then created at the 2-o'clock position. After obtaining access to the hip joint (Fig 7), diagnostic evaluation of the central compartment is made using a 70° arthroscope (Arthrex, Naples, FL). The distal anterolateral accessory portal is then created. Arthroscopy of the central compartment is completed after conducting any other indicated procedures, such as anchor placement, labral repair, or synovial debridement per the surgeon's standard technique (Video 1). The procedure continues with the peripheral compartment after releasing traction. Osteochondroplasty is performed to recontour the femoral neck through gentle movements using a 5.5-mm arthroscopic burr (Arthrex) in different hip flexion and rotation degrees (Video 1). Adequate cam resection is ensured through internally rotating the leg (Fig 8), which can easily be performed with use of the pink pad, as no post is present to prevent full range of motion. At the end of the procedure, the bed is taken out of Trendelenburg. Care must be taken when moving the patient as the pink pad will prevent the patient from easily being slid in the cephalad or caudad directions.

Discussion

This post-free distraction technique for hip arthroscopy is a simple, cost-friendly alternative to conventional methods that eliminates the possibility of iatrogenic groin and perineal injuries caused by distraction through a post. Perineal and pudendal nerve complications are reported to occur in up to 4.3% of cases, and while most injuries are transient (perineal anesthesia/dysesthesia), others can be devastating (perineal skin injury).^{4,10} Despite the challenge that comes with familiarizing oneself with new equipment, the pink pad is easy for the surgeon and operating room staff to learn while preventing post-related injuries from occurring. In addition, surgeons that choose to use the pink pad may continue to use their preferred table, as the pad is compatible with all standard hip arthroscopy tables (Table 1). The learning curve associated with hip arthroscopy has been associated with the rate of major complications (0.58%) and the reoperation rate (6.8%) following the procedure.¹⁰ Incomplete resection of cam and/or pincer lesions is associated with up to 81% of revision hip arthroscopy cases.¹¹ The ability to more freely internally rotate the leg while using the pink pad allows for easy assessment of whether adequate cam resection has been performed. Although use of the pink pad for post-free distraction cannot prevent all complications following hip arthroscopy, it can aid in proper positioning and improved visualization for surgeons early in the learning curve, which may prevent other complications throughout the procedure.

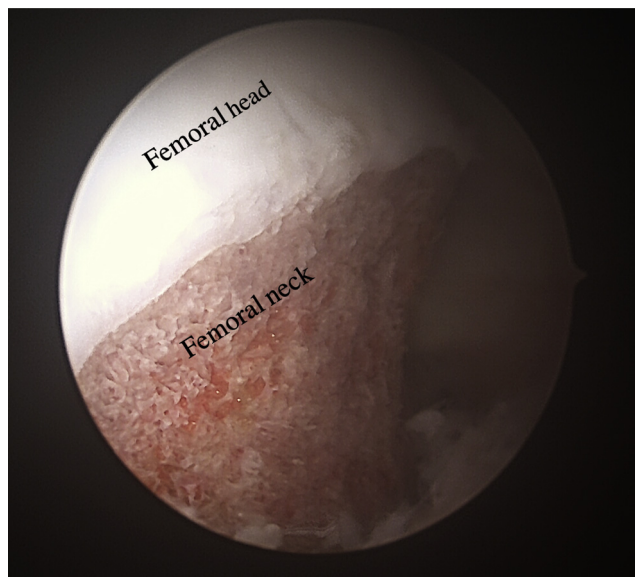


Fig 8. Arthroscopic view of cam resection. Without a pudendal post, a greater degree of internal rotation is able to be achieved, allowing for greater visualization of the anterior portion of the femoral neck following cam lesion resection, as demonstrated through the modified mid-anterior viewing portal for this left-sided hip.

Table 1. Advantages and Disadvantages

Advantages	Disadvantages
Elimination of iatrogenic perineal injuries caused by the post Inexpensive item that is easily stored and is disposable	Learning for nontraditional hip arthroscopy set-up Patients must be to be lifted off the bed to be moved; cannot slide patients up and down on the pad
Does not affect the preferred surgical technique	Lighter patients may require increased Trendelenburg to maintain adequate distraction Possible anterior tilt of the pelvis during the procedure
Compatibility with all conventional hip arthroscopy tables; does not require purchase or storage of specialized equipment	
Provides strong distraction force via gravity and friction	
Lack of a post allows for the C-arm to be moved freely, allowing for improved imaging of the hip throughout the case	
Adequate hip joint post-free distraction that allows central compartment procedures	
Post-free peripheral compartment arthroscopy allows for greater degree of range of motion for better evaluation and resection of the cam deformity	

Table 2. Pearls and Pitfalls

Pearls	Pitfalls
Ensure that all straps are fastened to the table appropriately Place the patient where they would normally be on a table with a post Initial supervision of surgical team is necessary until they learn the new set-up Lift the patient on the draw sheet to move cephalad/caudad	Overtightening straps can cause the pad to tear Ensure that pad does not shift during patient transfer
Since lighter patients may move more distally during traction, they should be positioned 1-2 inches more proximally before the initial traction	Improper patient positioning can lead to suboptimal imaging of the hip and risk patient safety if the patient is too far distal Improper technique while moving the patient or aggressive pulling of the drawsheet can cause the pad to tear Neglecting to remove the draw sheet can result in unwanted and dangerous movement of the patient during the case

Surgeons considering use of the pink pad must take into account the associated limitations and differences from standard distraction methods using during hip arthroscopy (Table 2). Higher degrees of Trendelenburg may be necessary in patients who weigh less than 120 pounds, which may be challenging for the surgeon as the fluoroscopic view may vary from what he or she is familiar with.⁶ In addition, although the pink pad prevents the patient from sliding on the table throughout the procedure, the patient's pelvis may tilt anteriorly when adjusting the level of traction during the surgery, which should be corrected if recognized to maintain a consistent fluoroscopic view and to prevent lumbar strain on the patient (Table 2).⁶ Moreover, care must be taken when moving the patient to ensure the pad does not move or tear. Despite these challenges, the pink pad allows for the elimination of post-related complications during hip arthroscopy while functioning as a cost- and user-friendly positioning device.

References

- Maradit Kremers H, Schilz SR, Van Houten HK, et al. trends in utilization and outcomes of hip arthroscopy in the United States between 2005 and 2013. *J Arthroplasty* 2017;32:750-755.
- Degen RM, Bernard JA, Pan TJ, et al. Hip arthroscopy utilization and associated complications: A population-based analysis. *J Hip Preserv Surg* 2017;4: 240-249.
- Schäirer WW, Nwachukwu BU, Suryavanshi JR, Yen YM, Kelly BT, Fabricant PD. A shift in hip arthroscopy use by patient age and surgeon volume: A New York State-based population analysis 2004 to 2016. *Arthroscopy* 2019;35: 2847-2854.e1.
- Habib A, Haldane CE, Ekhtiari S, et al. Pudendal nerve injury is a relatively common but transient complication of hip arthroscopy. *Knee Surg Sports Traumatol Arthrosc* 2018;26:969-975.
- Welton KL, Garabekyan T, Kraeutler MJ, et al. Effects of hip arthroscopy without a perineal post on venous blood flow, muscle damage, peripheral nerve conduction, and perineal injury: A prospective study. *Am J Sports Med* 2019;47:1931-1938.
- Kollmorgen RC, Ellis T, Lewis BD, Harris JD. Achieving post-free distraction in hip arthroscopy with a pink pad patient positioning device using standard hip distraction tables. *Arthrosc Tech* 2019;8:e363-e368.
- Mei-Dan O, McConkey MO, Young DA. Hip arthroscopy distraction without the use of a perineal post: Prospective study. *Orthopedics* 2013;36:e1-e5.
- Kollmorgen RC, Ellis T, Lewis B, Harris J. Effect of post-free distraction hip arthroscopy on acute pain, discharge time and narcotic use. *Arthroscopy* 2021;37:e7-e8.

9. Jimenez ML, Haneda M, Pascual-Garrido C. The hip arthroscopy post-less procedure impingement (HAPPI) technique: Achieving distraction with standard hip tables at zero additional cost. *Arthrosc Tech* 2020;9:e1697-e1701.
10. Harris JD, McCormick FM, Abrams GD, et al. Complications and reoperations during and after hip arthroscopy: a systematic review of 92 studies and more than 6,000 patients. *Arthroscopy* 2013;29:589-595.
11. Cvetanovich GL, Harris JD, Erickson BJ, Bach BR Jr, Bush-Joseph CA, Nho SJ. Revision hip arthroscopy: A systematic review of diagnoses, operative findings, and outcomes. *Arthroscopy* 2015;31:1382-1390.