

H3K27M and *TERT* promoter mutations are poor prognostic factors in surgical cases of adult thalamic high-grade glioma

Yoshinari Osada, Ryuta Saito, Ichiyo Shibahara, Keisuke Sasaki, Takuhiro Shoji, Masayuki Kanamori, Yukihiro Sonoda, Toshihiro Kumabe, Mika Watanabe, and Teiji Tominaga

Department of Neurosurgery, Tohoku University Graduate School of Medicine, Sendai, Japan (Y.O., R.S., K.S., T.S., M.K., T.T.); Department of Neurosurgery, Kitasato University Graduate School of Medicine, Kanagawa, Japan (I.S., T.K.); Department of Neurosurgery, Yamagata University Graduate School of Medicine, Yamagata, Japan (Y.S.); Department of Pathology, Tohoku University Hospital, Sendai, Japan (M.W.)

Corresponding Author: Ryuta Saito, MD, PhD, Department of Neurosurgery, Tohoku University Graduate School of Medicine, 1-1 Seiryō-machi, Aoba-ku, Sendai 980-8575, Miyagi, Japan (ryuta@nsg.med.tohoku.ac.jp).

Abstract

Background. Thalamic high-grade gliomas (HGGs) are rare tumors with a dismal prognosis. H3K27M and telomerase reverse transcriptase promoter (*TERTp*) mutations reportedly contribute to poor prognoses in HGG cases. We investigated the outcomes of surgically treated adult thalamic HGGs to evaluate the prognostic significance of H3K27M and *TERTp* mutations.

Methods. We retrospectively analyzed 25 adult patients with thalamic HGG who underwent maximum surgical resection from January 1997 to March 2020. The histological and molecular characteristics, progression-free survival (PFS), and overall survival (OS) of the patients were compared. For molecular characteristics, target sequencing was used to determine the *H3F3A*, *HIST1H3B*, and *TERTp* mutations.

Results. H3K27M mutations were detected in 12/25 (48.0%) patients. *TERTp* mutations were not detected in H3K27M-mutant gliomas but were detected in 8/13 (61.5%) of H3 wild-type gliomas. Although it was not significant, H3K27M-mutant gliomas tended to have a shorter PFS (6.7 vs 13.1 months; $P = .2928$) and OS (22.8 vs 24.4 months; $P = .2875$) than H3 wild-type gliomas. Moreover, the prognosis of *TERTp*-mutant gliomas was as poor as that of H3K27M-mutant gliomas. Contrary, 5 gliomas harboring both H3 and *TERTp* wild-type showed a better median PFS (59.2 vs 6.4 months; $P = .0456$) and OS (71.8 vs 24.4 months; $P = .1168$) than those harboring H3K27M or *TERTp* mutations.

Conclusions. *TERTp*-mutant gliomas included in the H3 wild-type glioma group limited patient survival as they exhibited an aggressive course similar to H3K27M-mutant gliomas. Comprehensive molecular work-up for the H3 wild-type cases may further confirm this finding.

Key Points

- H3K27M-mutant gliomas had a statistically nonsignificantly shorter PFS and OS than H3 wild-type gliomas.
- *TERTp* and H3K27M mutations were mutually exclusive in thalamic high-grade gliomas in this series.
- The prognosis of *TERTp*-mutant gliomas was as poor as that of H3K27M-mutant gliomas.

Importance of the Study

Adult thalamic high-grade gliomas (HGGs) are rare tumors with a dismal prognosis. Approximately 50% of gliomas harbor an H3K27M mutation and correspond to the World Health Organization grade IV. Although H3K27M mutations are associated with poor prognosis in pediatric gliomas, the relationship between H3K27M mutations and clinical course in adult thalamic HGGs remains unclear. We retrospectively analyzed the clinical course of 25 adult patients with thalamic HGG who underwent surgical resection, emphasizing on the H3K27M status. The prognosis of patients with H3K27M

mutations was statistically nonsignificantly worse than those with H3 wild-type. Moreover, ~60% of H3 wild-type gliomas harbored telomerase reverse transcriptase promoter (*TERTp*) mutations; *TERTp*-mutant gliomas shared an aggressive clinical course similar to H3K27M-mutant gliomas. Our analysis revealed that in young adults with thalamic HGGs, the prognosis of H3 wild-type gliomas was as poor as those with H3K27M mutations owing to the substantial proportion of patients with *TERTp* mutations.

Thalamic gliomas are rare and account for ~1%–5% of all brain tumors,^{1,2} affecting any age from childhood to adulthood. Approximately 88% of primary thalamic tumors comprise astrocytomas, with up to 50% showing evidence of histological malignancy.^{1,3,4} Owing to improved surgical techniques and supportive equipment,^{5,6} maximal resection has become a possible treatment option even for deep-seated tumors, including thalamic gliomas. However, malignant thalamic gliomas remain associated with a poor prognosis.^{5,7,8}

Recently, heterozygous mutations at the codon 27 of the *H3F3A* or *HIST1H3B/C* genes encoding the histone variants H3.3 or H3.1, respectively, were identified in patients with malignant thalamic gliomas. This type of glioma is classified as a diffuse midline glioma according to the 2016 World Health Organization (WHO) classification of tumors of the central nervous system. These mutations are frequently detected in the brainstem, thalamus, and spinal gliomas.⁹ In patients of pediatric gliomas, H3K27M mutations are associated with aggressive clinical courses, independent of their anatomical location.¹⁰ However, several reports have indicated that the H3K27M mutation in the thalamic gliomas of young adult patients is not necessarily associated with poor prognosis.^{11–13} These reports mainly included nonresected cases, and information on surgically resected cases is limited. In this study, we investigated the clinical course of surgically resected thalamic high-grade gliomas (HGGs), emphasizing on the H3K27M status. Moreover, we studied the telomerase reverse transcriptase promoter (*TERTp*) mutation, which has been reported as the poor prognostic factor in the adult diffuse gliomas of midline lesion,¹⁴ in patients with surgically resected thalamic HGGs.

III or IV diffuse gliomas were enrolled. All patients were treated at Tohoku University Hospital or Kitasato University Hospital. Patients were excluded if (i) only a biopsy was performed ($n = 6$), (ii) fresh-frozen sample was unavailable ($n = 2$), (iii) they died of a non-tumor-related cause ($n = 1$), or (iv) survival data were unavailable ($n = 1$). We retrospectively analyzed 25 patients who underwent tumor resection. Molecular analysis was performed in these patients and reclassified based on the 2016 WHO classification. The study was approved by the ethics committees of the Tohoku University Hospital and Kitasato University Hospital.

DNA Extraction and Molecular Analysis

The QIAamp DNA Mini Kit (Qiagen) was used to extract genomic DNA from freshly frozen tumor tissues, according to the manufacturer's instructions. The isocitrate dehydrogenase 1 (*IDH1*) mutation status was determined via real-time polymerase chain reaction (PCR) for the *IDH1* mutation using hybridization probes, as previously described.¹⁵ *IDH2*, *H3F3A*, *HIST1H3B*, and C228T or C250T *TERT* promoter (*TERTp*) mutations were assessed using Sanger sequencing following PCR amplification. Primers used in this study are presented in [Supplementary Table 1](#). Sanger sequencing was performed using the 3500xL Genetic Analyzer (Thermo Fisher Scientific), according to the manufacturer's instructions. Sequence data analyses were performed using Sequencing Analysis software v5.4 (Thermo Fisher Scientific). Using this method, cases with H3K27M mutation were defined as cases harboring the mutation in either *H3F3A* K27 or *HIST1H3B* K27. Cases wherein *H3F3A* K27 or *HIST1H3B* K27 mutation was not found were defined as cases with H3 wild-type. Moreover, BRAF mutational status was assessed in 3 long-term survivors. *BRAF* V600E mutation was tested using Sanger sequencing.

Materials and Methods

Patients and Samples

From January 1997 to March 2020, 35 adult patients aged ≥18 years old (median age, 48 years old; range 23–75 years) with histologically diagnosed primary thalamic WHO grade

Neuropathological Analyses

The formalin-fixed/paraffin-embedded thalamic HGG tumor samples were subjected to routine neuropathological evaluation using hematoxylin and eosin staining and

immunohistochemical staining. Immunohistochemical analyses included staining for p53 protein (mouse monoclonal antibody, Roche, cat. no. 790–2912), alpha-thalassemia/mental retardation syndrome X-linked protein (mouse monoclonal antibody, Abcam, cat. no. ab188027), O6-methylguanine-DNA methyltransferase (MGMT) (mouse monoclonal antibody, Millipore, cat. no. MAB16200), and MIB-1 labeling index (mouse monoclonal antibody, Agilent, cat. no. IR626). Further, p53 protein expression was defined as positive if the staining was observed in >10% of the nuclei, which reportedly suggests an underlying *TP53* missense mutation.¹⁶ In the evaluation of ATRX staining, loss of nuclear ATRX was scored specific if tumor cell nuclei were unstained while nuclei of non-neoplastic cells such as endothelia and reactive astrocytes stained strongly positive.¹⁷ MGMT protein immunoreactivity was semiquantitatively evaluated by estimating the fraction of positive cells and defining <20% as low (1+), 20%–50% as moderate (2+), and >50% as high (3+) reactivity.¹⁸

Outcome Assessment

Basic demographics included the age at diagnosis, sex, WHO grade, histopathological results, and molecular analyses as well as the laterality of the tumor, presence of initial metastases, and patterns of recurrence. In this study, the distant recurrence was identified with the recurrence in the remote lesion, and the leptomeningeal dissemination was radiographically identified with abnormal enhancement or nodular deposits at the cerebral ventricular wall or at the subarachnoid spaces of the brain and spinal cord. Treatment demographics included the extent of surgical resection, surgical approaches performed for tumor removal, postoperative adjuvant therapy, and preoperative and postoperative KPS scores. In 24 patients with preoperative contrast enhancement on T1-weighted sequences, the gross total resection and subtotal resection was defined as complete or >95% resection of contrast enhancement on T1-weighted sequences, respectively. In one patient without contrast enhancement, it was evaluated using high intensity with T2-weighted sequences. We evaluated progression-free survival (PFS) and overall survival (OS). PFS and OS were defined as the time from the surgery to detection of radiological deterioration following resection (as assessed with RANO criteria) and to death, respectively.¹⁹

Statistical Analysis

For statistical analysis of differences between the mean values of two groups, Fisher's exact test and Welch's *t*-test were applied. Survival analysis was performed using the Kaplan–Meier method. Statistical significance was calculated using the log-rank test. PFS and OS were assessed using Cox proportional hazards regression in univariate and multivariate models. Statistical significance was assumed at $P < .05$. SAS (version 9.4; SAS Institute Inc.) was used for all statistical analyses.

Results

Frequency of Histone Mutations and Clinical Characteristics

The baseline patient characteristics are given in Table 1. Among the 25 thalamic HGGs, 12 (48.0%) tumors had an *H3F3A* mutation at K27, whereas none of the 25 tumors harbored an *H3F3A* mutation at G34 or *HIST1H3B* mutation at K27. The mean age at diagnosis in the H3K27M-mutant glioma group was younger (39.8 ± 10.4 years) than that in the H3 wild-type group (39.8 ± 10.4 years vs 52.5 ± 14.5 years; $P = .0184$). Moreover, patients with H3K27M-mutant gliomas were all aged <55 years. Of the patients with H3K27M mutations, 9/12 (75.0%) were male. There were no bilateral cases in this series, considering that only patients subjected to surgical resection were analyzed. Initial metastases were detected in 1 patient in each group. The incidence of distant recurrence and dissemination: 12 including 11 leptomeningeal dissemination and one distant recurrence, was 7/12 (58.5%) and 5/13 (38.5%) in H3K27M-mutant and H3 wild-type patients, respectively. Patients with H3K27M mutation showed higher MGMT protein immunoreactivity than those with H3 wild-type ($P = .0090$).

Furthermore, treatment characteristics are given in Table 1. Gross total or subtotal resection was achieved in 9/12 (75.0%) patients with H3K27M-mutant gliomas and all patients with H3 wild-type gliomas. All patients received postoperative chemoradiotherapy with nimustine hydrochloride or temozolomide. Radiation dose for each patient is demonstrated in Figures 1 and 2. There were no statistically significant difference in pre- ($P = .1152$) or postoperative KPS score ($P = .2377$) between the two groups.

Molecular and Histological Characteristics

Molecular and histological characteristics were investigated in H3K27M mutant and wild-type gliomas (Figures 1 and 2). No cases with H3K27M mutations harbored *IDH* or *TERTp* mutations. By contrast, *TERTp* mutations were identified in 8/13 (61.5%) H3 wild-type gliomas. Further, one patient with H3K27M-mutant glioma was histologically diagnosed with anaplastic oligodendroglioma; however, the 1p/19q codeletion was not detected in this patient. The median MIB-1 indices of the H3K27M-mutant and wild-type gliomas were 24.5% and 21.5%, respectively.

Prognosis of H3K27M-Mutant Thalamic HGGs

PFS and OS are shown in Figure 3. The median PFS was 6.7 and 13.1 months for patients with H3K27M-mutant and H3 wild-type gliomas, respectively ($P = .2928$; Figure 3A). The median OS was 22.8 and 24.4 months for H3K27M-mutant and H3 wild-type patients, respectively ($P = .2875$; Figure 3B). Subsequently, we performed a survival analysis of patients with H3K27M-mutant and H3 wild-type glioblastomas. A similar tendency was observed, but was statistically not significant (Supplementary Figure 1A,B).

Table 1. Comparisons of the Clinical and Treatment Characteristics Between H3K27M and Wild-type High-grade Thalamic Glioma Patients

Characteristics	H3K27M N = 12	Wild-type N = 13	P-value
Basic demographics			
Age at diagnosis, years			
Mean age (years ± SD)	39.8 ± 10.4	52.5 ± 14.5	.0184*
Range	23–52	23–74	
<55 years	12 (100)	6 (46.2)	
≥55 years	0	7 (53.8)	
Sex			
Female	3 (25.0)	6 (46.2)	.4110**
Male	9 (75.0)	7 (53.8)	
Histological diagnosis			
Anaplastic astrocytoma	3 (25.0)	4 (29.8)	1.0000**
Anaplastic oligodendroglioma	1 (8.3)	0	
Glioblastoma	8 (66.7)	9 (69.2)	
MGMT immunohistochemical staining			
Negative or +1	0	8 (61.5)	.0090**
+2 or +3	6 (50.0)	3 (25.0)	
Laterality			
Left	8 (66.7)	8 (61.5)	1.0000**
Right	4 (33.3)	5 (38.5)	
Bilateral	0	0	
Initial metastasis			
Yes	1 (8.3)	1 (7.7)	1.0000**
No	11 (91.7)	12 (92.3)	
Preoperative KPS score			
≥80	8 (66.7)	4 (30.8)	.1152**
≤70	4 (33.3)	9 (69.2)	
Treatment demographics			
Surgical approach			
High parietal	11 (91.7)	13 (100)	.4800**
Occipital transventricular	1 (8.3)	0	
Extent of surgical resection			
Gross total/subtotal	2/7 (75.0)	4/9 (100)	.0957**
Partial	3 (25.0)	0	
Postoperative KPS score			
≥ 80	7 (58.3)	4 (30.8)	.2377**
≤ 70	5 (41.7)	9 (69.2)	
Adjuvant therapy			
ACNU + RT	7 (58.3)	4 (30.8)	.2377**
TMZ + RT	5 (41.7)	9 (69.2)	
Recurrence			
Local only	5 (41.7)	5 (38.5)	1.0000**
Distant recurrence/dissemination	7 (58.3)	5 (38.5)	.4338**
Survival data			
Median PFS (months)	6.7	13.1	.2928***
Median OS (months)	22.8	24.4	.2875***

Data expressed as the number (%) of patients unless otherwise indicated.

ACNU, 1-(4-amino-2-methyl-5-pyrimidinyl)methyl-3-(2-chloroethyl)-3-nitrosourea hydrochloride; OS, overall survival; PFS, progression-free survival; RT, radiation therapy; TMZ, temozolomide.

*Welch's *t*-test. **Fisher's exact test. ***Log-rank test.

Patient	ATG 1	ATG 2	ATG 3	ATG 4	ATG 5	ATG 6	ATG 7	ATG 8	ATG 9	ATG 10	ATG 11	ATG 12
Sex	F	F	M	M	M	M	M	M	M	F	M	M
Age at diagnosis (yrs)	23	26	29	32	37	40	42	43	50	51	52	52
Histological diagnosis	GBM	GBM	GBM	AA	GBM	AA	GBM	GBM	AA	GBM	GBM	AO
Initial WHO tumor grading	IV	IV	IV	III	IV	III	IV	IV	III	IV	IV	III
Radiation therapy	60Gy	60Gy	60Gy	72Gy	60Gy	72Gy	60Gy	60Gy	57.2Gy	60Gy	60Gy	66Gy
Molecular analysis												
<i>IDH1</i>	Wild-type	Wild-type	Wild-type	Wild-type	Wild-type	Wild-type	Wild-type	Wild-type	Wild-type	Wild-type	Wild-type	Wild-type
<i>IDH2</i>	Wild-type	Wild-type	Wild-type	Wild-type	Wild-type	Wild-type	Wild-type	Wild-type	Wild-type	Wild-type	Wild-type	Wild-type
<i>H3F3A K27</i>	Mutated	Mutated	Mutated	Mutated	Mutated	Mutated	Mutated	Mutated	Mutated	Mutated	Mutated	Mutated
<i>H3F3A G34</i>	Wild-type	Wild-type	Wild-type	Wild-type	Wild-type	Wild-type	Wild-type	Wild-type	Wild-type	Wild-type	Wild-type	Wild-type
<i>HIST1H3B K27</i>	Wild-type	Wild-type	Wild-type	Wild-type	Wild-type	Wild-type	Wild-type	Wild-type	Wild-type	Wild-type	Wild-type	Wild-type
<i>TERT</i> promotor	Wild-type	Wild-type	Wild-type	Wild-type	Wild-type	Wild-type	Wild-type	Wild-type	Wild-type	Wild-type	Wild-type	Wild-type
Histological analysis												
p53-IHC	Unknown	Positive	Unknown	Unknown	Negative	Unknown	Positive	Negative	Unknown	Positive	Unknown	Negative
ATRX-IHC	Unknown	Loss	Unknown	Unknown	Unknown	Unknown	Unknown	Loss	Unknown	Unknown	Unknown	Loss
MGMT-IHC	Unknown	2+	Unknown	Unknown	3+	Unknown	2+	3+	Unknown	2+	Unknown	2+
MIB-1-IHC	44%	26%	30%	20%	20%	8%	30%	65%	7%	23%	20%	29%








Wild-type  Retained  Positive  Unkown 
 Mutated  Loss  Negative 

Figure 1. Histological and molecular characteristics of adult thalamic high-grade gliomas with H3K27M mutations. AA, anaplastic astrocytoma; AO, anaplastic oligodendroglioma; GBM, glioblastoma.

Moreover, 3 patients survived longer than 60 months, including 1 with an H3K27M-mutant glioma and 2 with H3 wild-type gliomas. *BRAFV600E* mutation was not detected in these patients.

Impact of *TERTp* Status in Thalamic HGGs on Patient Survival

The baseline patient characteristics including age at diagnosis, sex, histological diagnosis, MGMT immunohistochemical stainings, laterality, existence of initial metastasis, and preoperative KPS score, and treatment details including surgical approach, extent of surgical resection, postoperative KPS score, adjuvant therapy, pattern of recurrence, and survival are given in [Table 2](#). The incidence of distant recurrence or dissemination was 7/12 (58.5%) and 3/8 (37.5%) in patients with H3K27M-mutant and *TERTp*-mutant gliomas, respectively. The patients with H3K27M mutation tended to have higher MGMT protein immunoreactivity than those with *TERTp* mutation ($P = .0699$). We compared the survival of patients with *TERTp* and H3K27M-mutant gliomas. The median PFS in the *TERTp*-mutant glioma group and H3K27M-mutant glioma group were 12.5 and 6.7 months ($P = .7858$; [Figure 4A](#)), and the median OS were 24.4 and 22.8 months ($P = .8678$; [Figure 4B](#)), respectively. Finally, we examined whether the *TERTp* mutation status affected the survival of patients with thalamic HGGs. The median PFS for H3K27M- or *TERTp*-mutant gliomas was 6.4 months compared with 59.2 months for both H3 and

TERTp wild-type gliomas ($P = .0456$; [Figure 4C](#)). The median OS for H3K27M- or *TERTp*-mutant gliomas was 24.4 months compared with 71.8 months for both H3 and *TERTp* wild-type gliomas ($P = .1168$; [Figure 4D](#)). Further, 2 patients in the H3 and *TERTp* wild-type glioma group survived longer than 80 months (ATG16 and ATG23) with no recurrence.

The factors included in the multivariate analysis of PFS and OS were distance recurrence or dissemination, H3K27M mutation, *TERTp* mutation, MGMT protein immunoreactivity, MIB-1 index, extent of surgical resection, and pre- and post-operative KPS scores. The result of the PFS and OS analysis using Cox hazards regression is given in [Supplementary Tables 2 and 3](#), respectively. In the multivariate analysis, factors associated with PFS or OS were not identified.

Discussion

Recently, it was reported that thalamic gliomas in pediatric and young adults exhibit H3K27M mutations.^{9-13,20-23} Although it was reported that 50%–67% of adult thalamic gliomas harbor H3K27M mutations,^{9,11-13} information on adult thalamic gliomas is scarce. Accordingly, the surgical outcomes for adult thalamic gliomas harboring H3K27M-mutant and H3 wild-type status remain unclear. Because thalamic gliomas are rare tumors, no large clinical trials have been conducted to date. Consequently, no guidelines for their treatment have been established. Previous studies have indicated that thalamic gliomas have a poor

Patient	ATG 13	ATG 14	ATG 15	ATG 16	ATG 17	ATG 18	ATG 19	ATG 20	ATG 21	ATG 22	ATG 23	ATG 24	ATG 25
Sex	M	F	M	M	M	M	M	M	F	F	F	F	F
Age at diagnosis (yrs)	23	39	40	42	44	48	58	59	60	62	67	67	74
Histological diagnosis	AA	AA	GBM	GBM	GBM	GBM	GBM	AA	GBM	GBM	GBM	GBM	AA
Initial WHO tumor grading	III	III	IV	IV	IV	IV	IV	III	IV	IV	IV	IV	III
Radiation therapy	72Gy	72Gy	60Gy	60Gy	60Gy	60Gy	60Gy	72Gy	60Gy	60Gy	54Gy	60Gy	72Gy
Molecular analysis													
<i>IDH1</i>													
<i>IDH2</i>													
<i>H3F3A</i> K27													
<i>H3F3A</i> G34													
<i>HIST1H3B</i> K27													
<i>TERT</i> promoter	C250T		C228T		C250T	C228T	C228T		C228T	C250T			C228T
Histological analysis													
p53-IHC	Blue	Blue	Blue	Red	Blue	White	Blue	White	Blue	Blue	Red	Red	Blue
ATRX-IHC	Orange	Orange	White	Orange	Orange	White	Orange	White	Orange	Orange	Orange	Orange	Orange
MGMT-IHC	2+	1+	3+	1+	1+		3+		1+	1+	1+	1+	1+
MIB-1-IHC	23%	18%	50%	34%	37%		18%	18%	35%	20%	15%	25%	16%

Wild-type Retained Positive Unknown
 Mutated Loss Negative

Figure 2. Histological and molecular characteristics of adult thalamic high-grade gliomas with H3 wild-type status. AA, anaplastic astrocytoma; GBM, glioblastoma.

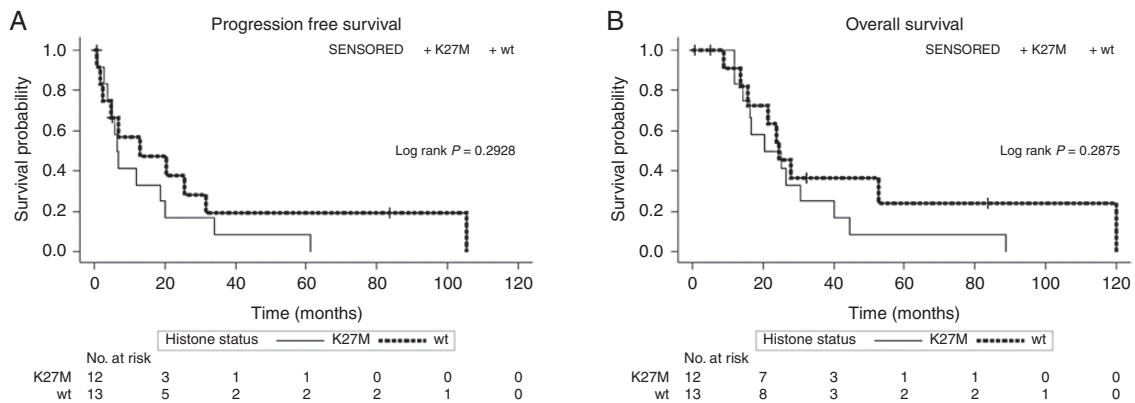


Figure 3. Kaplan–Meier PFS (A) and OS (B) curves of patients with adult thalamic high-grade glioma stratified by the H3 mutational status.

prognosis and that H3 status was not associated with patient survival.^{11–13} Aihara et al. reported that the median PFS and OS of thalamic HGGs were 5.3 and 9.9 months, respectively; however, few cases received surgical resection.¹²

In this study, we investigated whether there is any difference in survival between H3K27M-mutant and H3 wild-type thalamic gliomas in patients who underwent surgical resection. H3K27M mutations were detected in 48% of adult thalamic HGGs, which was consistent with other previous studies.^{11–13} In the literature, some studies have reported the survival benefits of surgical resection for patients with thalamic gliomas.^{5,7,8,24} A recent relatively large study involving 102 patients with adult thalamic

gliomas reported by Niu et al. showed that gross total resection plus chemoradiotherapy provided a significant benefit in terms of OS compared with other treatment regimens.⁸ There was selection bias in our study because we only analyzed the surgical cases; nonetheless, the PFS and OS were longer than those previously reported for both H3K27M-mutant and H3 wild-type gliomas.^{8,11–13} In the present series, the patients with the survival of >60 months were found in both the H3K27M-mutant and wild-type groups. Therefore, our results suggest that surgical resection has improved the survival outcome of adult thalamic HGGs harboring H3K27M-mutant and H3 wild-type status.

Table 2. Comparison of the Clinical Characteristics of High-grade Thalamic Glioma Patients With H3K27M and *TERT*_p Mutation

Characteristics	H3K27M N = 12	<i>TERT</i> _p mut N = 8	P-value
Basic demographics			
Age at diagnosis, years			
Mean age (years ± SD)	39.8 ± 10.4	51.1 ± 15.8	.1002*
Range	23–52	23–74	
<55 years	12 (100)	4 (50.0)	
≥55 years	0	4 (50.0)	
Sex			
Female	3 (25.0)	3 (37.5)	.6424**
Male	9 (75.0)	5 (62.5)	
Histological diagnosis			
Anaplastic astrocytoma	3 (25.0)	2 (25.0)	.2384**
Anaplastic oligodendroglioma	1 (8.3)	0	
Glioblastoma	8 (66.7)	6 (75.0)	
MGMT immunohistochemical staining			
Negative or +1	0	4 (50.0)	.0699**
+2 or +3	6 (50.0)	3 (37.5)	
Laterality			
Left	8 (66.7)	4 (50.0)	.6479**
Right	4 (33.3)	4 (50.0)	
Bilateral	0	0	
Initial metastasis			
Yes	1 (8.3)	0	1.0000**
No	11 (91.7)	8 (100)	
Recurrence			
Local only	5 (41.7)	2 (25.0)	.6424**
Distance or dissemination	7 (58.3)	3 (37.5)	.6499**
Preoperative KPS score			
≥80	8 (66.7)	3 (37.5)	.3618**
≤70	4 (33.3)	5 (62.5)	
Treatment demographics			
Surgical approach			
High parietal	11 (91.7)	8 (100)	1.0000**
Occipital transventricular	1 (8.3)	0	
Extent of surgical resection			
Gross total/subtotal	2/7 (75.0)	1/7 (100)	.2421**
Partial	3 (25.0)	0	
Postoperative KPS score			
≥80	7 (58.3)	2 (25.0)	.1968**
≤70	5 (41.7)	6 (75.0)	
Adjuvant therapy			
ACNU + RT	7 (58.3)	2 (25.0)	.1968**
TMZ + RT	5 (41.7)	6 (75.0)	
Recurrence			
Local only	5 (41.7)	2 (25.0)	.6424**
Distant recurrence/dissemination	7 (58.3)	3 (37.5)	.6499**
Survival data			
Median PFS (months)	6.7	12.5	.7858***
Median OS (months)	22.8	24.4	.8678***

Data expressed as number (%) of patients, unless otherwise indicated.

ACNU, 1-(4-amino-2-methyl-5-pyrimidinyl)methyl-3-(2-chloroethyl)-3-nitrosourea hydrochloride; mut, mutation; OS, overall survival; PFS, progression-free survival; RT, radiation therapy; *TERT*_p, *TERT* promotor; TMZ, temozolomide.

*Welch's t-test. **Fisher's exact test. ***Log-rank test.

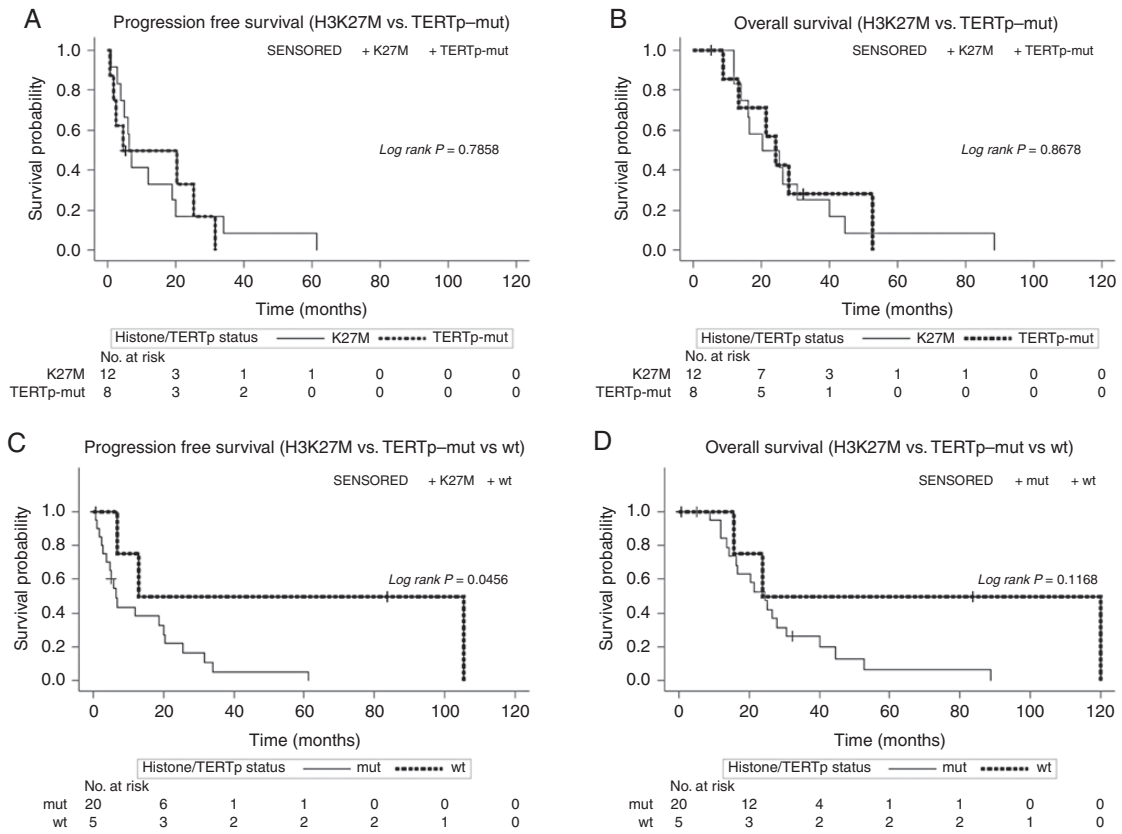


Figure 4. Kaplan–Meier progression-free survival (PFS) (A) and overall survival (OS) (B) curves of patients with H3K27M-mutant gliomas and *TERT* promoter-mutant gliomas. Kaplan–Meier estimates of PFS (C) and OS (D) in H3K27M or *TERT* promoter-mutant gliomas and both wild-type gliomas.

We investigated the pattern of recurrence of adult thalamic HGGs. Approximately 60% of the patients with H3K27M mutations and 40% with wild-type gliomas developed distant recurrence/leptomeningeal dissemination. Although not significantly different, the incidence of distant recurrence/dissemination was high in both groups. Mistry et al. investigated the relationship between leptomeningeal dissemination and ventricular entry during primary HGG surgery, and their meta-analysis indicated that the incidence of tumor dissemination was 20.5% in the ventricular entry group.²⁵ Compared with their study, both of our groups exhibited higher incidences of distant recurrence. We previously reported a high incidence of distant recurrence/dissemination following successful resection of thalamic HGGs.⁵ Consistent with this, distant recurrence/dissemination appeared to limit the survival outcomes in both groups.

In adult thalamic gliomas, the co-occurrence of H3K27M and *TERTp* mutations is rare.^{14,26} Picca et al. reported that the frequency of co-occurrence of these mutations was 2/57 (3.5%) in adult thalamic gliomas.¹⁴ In this study, we detected *TERTp* mutations in 61.5% of H3 wild-type gliomas, whereas these mutations were observed in none of H3K27M-mutant gliomas. *TERTp* mutations are a hallmark of adult *IDH* wild-type HGGs and occur in 60% of *IDH* wild-type astrocytomas and 80% of glioblastomas.²⁷ In our population, the prevalence of *TERTp* mutations was

consistent with previous reports. Recent studies have reported *TERTp* mutations as poor prognostic factors in both low-grade gliomas and HGGs.^{28–30} It is considered that the clinical courses of grade II and III astrocytomas with *IDH* wild-type and *TERTp* mutation status are similar to those of glioblastomas.^{30,31} Therefore, we performed a survival analysis comparing H3K27M-mutant and *TERTp*-mutant gliomas. Consequently, the prognosis of *TERTp*-mutant gliomas was as poor as H3K27M-mutant gliomas. The H3K27M mutation is indicated as a poor prognostic factor in pediatric populations.¹⁰ However, our results did not show significant differences in survival between H3K27M-mutant and H3 wild-type gliomas in adult thalamic HGGs. It can be presumed that this discrepancy may be due to the population of patients harboring *TERTp* mutations. A recent integrated molecular analysis showed that this population was relatively rare in pediatric patients.^{20,21} Therefore, it is possible that *TERTp* mutations were a factor affecting the prognosis of adult thalamic HGGs.

In this study, among the cases that immunohistochemical evaluation of the MGMT protein was possible, MGMT protein expression was low (negative or 1+) in 0/6 (0%) of H3K27M-mutant gliomas and in 4/7 (57%) of *TERTp*-mutant gliomas. Furthermore, H3K27M-mutant gliomas showed higher MGMT protein expression than H3 wild-type gliomas ($P = .0090$). Accordingly, previous studies have revealed that adult H3K27M-mutant gliomas were associated

with less frequent methylated MGMT.^{12,14,26} Considering that MGMT methylation is well known as the factor associated with better survival prognosis in gliomas,^{18,32} MGMT methylation status may be related with the poor prognosis in H3K27M-mutant gliomas.

Interestingly, we found 2 long-term survivors (ATG16 and ATG23) with a PFS of >80 months in the H3 wild-type group in this study. These patients were diagnosed with glioblastoma, which was completely resected and negative for the *TERTp* mutation. We compared the survival of patients with H3K27M or *TERTp* mutations with that of patients with both wild-type statuses. Patients with both wild-type status showed better PFS and OS than patients with either H3K27M or *TERTp* mutations. Consequently, patients with *TERTp* wild-type gliomas and not harboring the H3K27M mutation may gain further survival benefit from surgical resection.

There are several limitations to our study. First, the sample size was small; thus, the surgical outcomes for adult thalamic HGGs must be further examined in larger case series. Second, we investigated only a few molecular markers. The identification of additional molecular profiles associated with patient prognosis, such as *EGFR*, chromosome 7, and chromosome 10,^{30,32} may assist in further elucidating the molecular characteristics of the thalamic HGGs in this cohort. In addition, *IDH* wild-type astrocytoma diagnosed as histological grade III will be classified as “Not Otherwise Specified” without testing these molecular markers if the cIMPACT-NOW update 3 is formally applied.³⁰

In conclusion, we described the surgical outcomes of adult thalamic HGGs with or without H3K27M mutations. Surgical resection may improve survival outcomes, considering that long-term survivors were found in both groups. Moreover, we indicated that there is a population of adult patients with thalamic HGG harboring *TERTp* mutations experiencing an aggressive clinical course similar to that in patients harboring H3K27M mutations. Surgical resection is one of the treatment options that should be considered when deciding the treatment strategy in adult thalamic HGG gliomas. Because our study sample was small, more large-scale studies are required to confirm our conclusion.

Supplementary Material

Supplementary material is available at *Neuro-Oncology Advances* online.

Keywords

adult thalamic glioma | high-grade glioma | H3K27M | surgical resection | *TERT* promoter mutation

Acknowledgments

We would like to thank Enago (<http://www.enago.jp>) for the English language review.

Funding

This research was supported in part by AMED under Grant Number JP19lk0201070, JP20lm0203119.

Authorship Statement. Conceptualization and design: R.S. Acquisition of data: Y.O., I.S., K.S., and M.W. Manuscript writing: Y.O., R.S., and M.K. Final editing and approval of the manuscript: Y.S., T.K., and T.T.

Conflict of interest statement. All of the authors declare no conflicts of interest pertaining to this work.

References

- Cheek WR, Taveras JM. Thalamic tumors. *J Neurosurg.* 1966;24(2):505–513.
- Mckissock W, Paine KW. Primary tumours of the thalamus. *Brain.* 1958;81(1):41–63.
- Greenwood J Jr. Radical surgery of tumors of the thalamus, hypothalamus, and third ventricle area. *Surg Neurol.* 1973;1(1):29–33.
- Nishio S, Morioka T, Suzuki S, Takeshita I, Fukui M. Thalamic gliomas: a clinicopathologic analysis of 20 cases with reference to patient age. *Acta Neurochir (Wien).* 1997;139(4):336–342.
- Saito R, Kumabe T, Kanamori M, Sonoda Y, Tominaga T. Distant recurrences limit the survival of patients with thalamic high-grade gliomas after successful resection. *Neurosurg Rev.* 2017;40(3):469–477.
- Zheng X, Xu X, Zhang H, et al. A preliminary experience with use of intraoperative magnetic resonance imaging in thalamic glioma surgery: a case series of 38 patients. *World Neurosurg.* 2016;89:434–441.
- Zhang P, Wang X, Ji N, et al. Clinical, radiological, and pathological features of 33 adult unilateral thalamic gliomas. *World J Surg Oncol.* 2016;14:78.
- Niu X, Wang T, Zhou X, et al. Surgical treatment and survival outcome of patients with adult thalamic glioma: a single institution experience of 8 years. *J Neurooncol.* 2020;147(2):377–386.
- Hawkins C ED, Sturm D. Diffuse midline gliomas, H3 K27M mutant. In: Louis D, Ohgaki H, Wiestler O, Cavenee W, eds. *WHO Classification of Tumours of the Central Nervous System.* Lyon: IARC Press. 2016:57–59.
- Karremann M, Gielen GH, Hoffmann M, et al. Diffuse high-grade gliomas with H3 K27M mutations carry a dismal prognosis independent of tumor location. *Neuro Oncol.* 2018;20(1):123–131.
- Feng J, Hao S, Pan C, et al. The H3.3 K27M mutation results in a poorer prognosis in brainstem gliomas than thalamic gliomas in adults. *Hum Pathol.* 2015;46(11):1626–1632.
- Aihara K, Mukasa A, Gotoh K, et al. H3F3A K27M mutations in thalamic gliomas from young adult patients. *Neuro Oncol.* 2014;16(1):140–146.
- Wang L, Li Z, Zhang M, et al. H3 K27M-mutant diffuse midline gliomas in different anatomical locations. *Hum Pathol.* 2018;78:89–96.
- Picca A, Berzero G, Bielle F, et al. FGFR1 actionable mutations, molecular specificities, and outcome of adult midline gliomas. *Neurology.* 2018;90(23):e2086–e2094.

15. Kanamori M, Kikuchi A, Watanabe M, et al. Rapid and sensitive intraoperative detection of mutations in the isocitrate dehydrogenase 1 and 2 genes during surgery for glioma. *J Neurosurg*. 2014;120(6):1288–1297.
16. Takami H, Yoshida A, Fukushima S, et al. Revisiting TP53 mutations and immunohistochemistry—a comparative study in 157 diffuse gliomas. *Brain Pathol*. 2015;25(3):256–265.
17. Reuss DE, Sahm F, Schrimpf D, et al. ATRX and IDH1-R132H immunohistochemistry with subsequent copy number analysis and IDH sequencing as a basis for an “integrated” diagnostic approach for adult astrocytoma, oligodendroglioma and glioblastoma. *Acta Neuropathol*. 2015;129(1):133–146.
18. Sonoda Y, Yokosawa M, Saito R, et al. O(6)-Methylguanine DNA methyltransferase determined by promoter hypermethylation and immunohistochemical expression is correlated with progression-free survival in patients with glioblastoma. *Int J Clin Oncol*. 2010;15(4):352–358.
19. Vogelbaum MA, Jost S, Aghi MK, et al. Application of novel response/progression measures for surgically delivered therapies for gliomas: Response Assessment in Neuro-Oncology (RANO) Working Group. *Neurosurgery*. 2012;70(1):234–243; discussion 243-234.
20. Mackay A, Burford A, Carvalho D, et al. Integrated molecular meta-analysis of 1,000 pediatric high-grade and diffuse intrinsic Pontine Glioma. *Cancer Cell*. 2017;32(4):520–537 e525.
21. Mackay A, Burford A, Molinari V, et al. Molecular, pathological, radiological, and immune profiling of non-brainstem pediatric high-grade glioma from the HERBY Phase II randomized trial. *Cancer Cell*. 2018;33(5):829–842 e825.
22. Schwartzenuber J, Korshunov A, Liu XY, et al. Driver mutations in histone H3.3 and chromatin remodelling genes in paediatric glioblastoma. *Nature*. 2012;482(7384):226–231.
23. Wu G, Broniscer A, McEachron TA, et al.; St. Jude Children’s Research Hospital–Washington University Pediatric Cancer Genome Project. Somatic histone H3 alterations in pediatric diffuse intrinsic pontine gliomas and non-brainstem glioblastomas. *Nat Genet*. 2012;44(3):251–253.
24. Cinalli G, Aguirre DT, Mirone G, et al. Surgical treatment of thalamic tumors in children. *J Neurosurg Pediatr*. 2018;21(3):247–257.
25. Mistry AM, Kelly PD, Thompson RC, Chambless LB. Cancer dissemination, hydrocephalus, and survival after cerebral ventricular entry during high-grade glioma surgery: a meta-analysis. *Neurosurgery*. 2018;83(6):1119–1127.
26. Meyronet D, Esteban-Mader M, Bonnet C, et al. Characteristics of H3 K27M-mutant gliomas in adults. *Neuro Oncol*. 2017;19(8):1127–1134.
27. Pekmezci M, Rice T, Molinaro AM, et al. Adult infiltrating gliomas with WHO 2016 integrated diagnosis: additional prognostic roles of ATRX and TERT. *Acta Neuropathol*. 2017;133(6):1001–1016.
28. Simon M, Hosen I, Gousias K, et al. TERT promoter mutations: a novel independent prognostic factor in primary glioblastomas. *Neuro Oncol*. 2015;17(1):45–52.
29. Izquierdo C, Barritault M, Poncet D, et al. Radiological characteristics and natural history of adult IDH-wildtype astrocytomas with TERT promoter mutations. *Neurosurgery*. 2019;85(3):E448–E456.
30. Brat DJ, Aldape K, Colman H, et al. cIMPACT-NOW update 3: recommended diagnostic criteria for “Diffuse astrocytic glioma, IDH-wildtype, with molecular features of glioblastoma, WHO grade IV”. *Acta Neuropathol*. 2018;136(5):805–810.
31. Stichel D, Ebrahimi A, Reuss D, et al. Distribution of EGFR amplification, combined chromosome 7 gain and chromosome 10 loss, and TERT promoter mutation in brain tumors and their potential for the reclassification of IDHwt astrocytoma to glioblastoma. *Acta Neuropathol*. 2018;136(5):793–803.
32. Labussière M, Boisselier B, Mokhtari K, et al. Combined analysis of TERT, EGFR, and IDH status defines distinct prognostic glioblastoma classes. *Neurology*. 2014;83(13):1200–1206.