



## Case Report

## Hybrid management of aneurysmal vascular ring and a Kommerell's diverticulum in an adult: Case report

Dambuza Nyamande<sup>\*</sup>, Siphosenkosi M. Mazibuko

Department of Cardiothoracic Surgery, Sefako Makgatho Health Sciences University, South Africa

## ARTICLE INFO

## Keywords:

Case report  
Vascular ring  
Kommerell's diverticulum  
Hybrid endovascular

## ABSTRACT

**Introduction and importance:** Congenital vascular rings are rare in adults. The management is challenging when vascular rings present with concomitant aortic aneurysm and Kommerell's diverticulum.

**Case presentation:** We present a 68year old patient with a congenital vascular ring in the form of right sided aortic arch, with a retroesophageal left subclavian artery arising from an aneurysmal Kommerell's diverticulum. In addition, the patient had aneurysmal distal aortic arch and proximal descending aorta, causing severe symptomatic tracheal compression. The patient was successfully managed by debranching and reimplantation of head neck vessels to the ascending aorta through a median sternotomy, and concurrent endovascular stenting of the aneurysmal aorta.

**Clinical discussion:** A combination of complete vascular rings and aortic arch aneurysm poses a potentially higher surgical risk. The use of the less invasive endovascular stenting of the aorta as well as a limited open surgical approach offers a lesser risk, especially in poor pre-operative states.

**Conclusion:** A multidisciplinary team effort is key. Hybrid management of aneurysmal congenital vascular rings in high risk adults offers an attractive management alternative to conventional surgery.

## 1. Introduction

This work has been reported in line with the SCARE criteria [1]. Vascular rings are rare malformations of the aortic arch and its branches, with potential airway and esophageal symptoms [2]. The majority of presentations of vascular rings occur in pediatric population and are rare above 50years of age [2]. One rare type of vascular rings is a right sided arch with aberrant left subclavian artery arising from a Kommerell's diverticulum. An aberrant subclavian artery arising from a Kommerell's diverticulum has a prevalence of 0.4–2.3% [3]. Our case report adds to this variant, an aortic aneurysm involving the distal arch, descending aorta and also the Kommerell's diverticulum.

## 2. Presentation of case

68year old female with poorly controlled hypertension and obesity who presented with severe shortness of breath, with inspiratory and expiratory stridor. After intubation, the patient stabilized with acceptable blood gasses. The patient had no surgical, genetic or family history related to cardiovascular diseases. She had defaulted antihypertensive

medication and was previously lost to follow up. A chest x-ray showed hyperinflation, a wide mediastinum, increased convexity of the right heart border. A CT angiogram showed a right sided aortic arch, with an aberrant retroesophageal left subclavian artery arising from an aneurysmal Kommerell's diverticulum. The arch and proximal descending aorta were also aneurysmal and without dissection (Figs. 1 and 2). The four aortic arch branches were left common carotid, right common carotid, right subclavian and left subclavian artery in that order. The distal trachea, carina and esophagus were significantly compressed by the aneurysmal proximal aorta (Fig. 1). Echocardiography showed normal cardiac anatomy, good systolic function, normal valve function and left ventricular wall hypertrophy.

Considering her clinical condition, a single stage hybrid procedure was done by cardiothoracic and vascular surgeons. Off pump debranching of head and neck vessels was done by cardiothoracic surgeons via median sternotomy, reimplanting them to the ascending aorta using a branched 10mm Dacron<sup>R</sup> conduit. Thoracic endovascular aneurysm repair was done by vascular surgeons, deploying a stent graft in the distal ascending aorta, arch and proximal descending aorta via a right femoral artery access (Fig. 3). Endovascular left subclavian artery

<sup>\*</sup> Corresponding author. Sefako Makgatho Health Sciences University, 0102, Pretoria, South Africa.

E-mail address: [dnyamande7@gmail.com](mailto:dnyamande7@gmail.com) (D. Nyamande).

device closure was also done distal to the diverticulum. Bronchoscopy revealed minimal airway compromise and the patient was extubated on post-operative day 3. The airway symptoms gradually improved over 2 weeks without need of any further attention to the ligamentum arteriosus. The patient was eventually lost to follow-up for routine yearly serial follow up CT angiography, most likely due to financial constrains.

### 3. Discussion

Vascular rings can be complete or incomplete, with the former causing more symptoms [4]. They are an embryological malformation of the aortic arch and its branches resulting from abnormal persistence or regression of segments of the 4th arch [2,4]. Various types of vascular rings are hypothesized to originate from the double arch, which has both left and right arches, early during embryological development [4]. Four types of right sided arch rings can originate from the double arch, depending on which part of the double arch disappears [4]. Our case is a type 3 with right sided aortic arch, from which left common carotid, right common carotid, right subclavian and an aberrant retroesophageal left subclavian artery originate from the arch in that sequence. This represents interruption of the double arch between the left subclavian and left common carotid arteries [4]. The ligamentum arteriosus completes the ring, although often not visible on CT scan. The variable position of the descending aorta is not well emphasized in literature when right sided arch is described. However, others have described that either a right or left sided descending aorta can occur with right a sided arch [2]. Surgical access to such an aorta therefore needs carefully consideration.

Open surgical management of vascular rings has been well established and with good outcomes. However, the majority of these patients are in the pediatric population. In adults with commodities and concurrent aortic aneurysms, hybrid procedures have been described in isolated cases [2]. An aneurysmal Kommerell's diverticulum giving rise to the subclavian artery is an indication of intervention even without

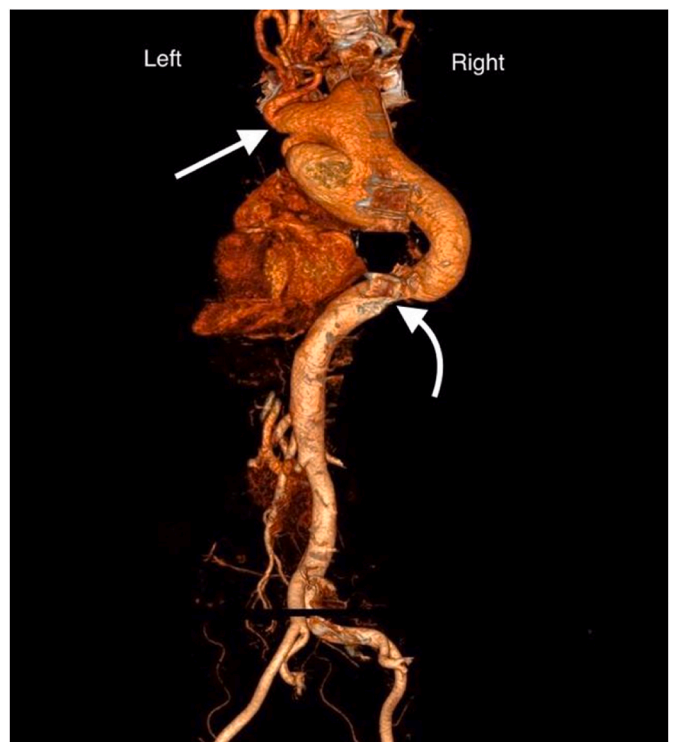


Fig. 2. Reconstruction of the aorta viewed from behind, showing retroesophageal left subclavian artery originating from a Kommerell's diverticulum (straight arrow). Transition of the aneurysmal aorta to normal dimensions (curved arrow).

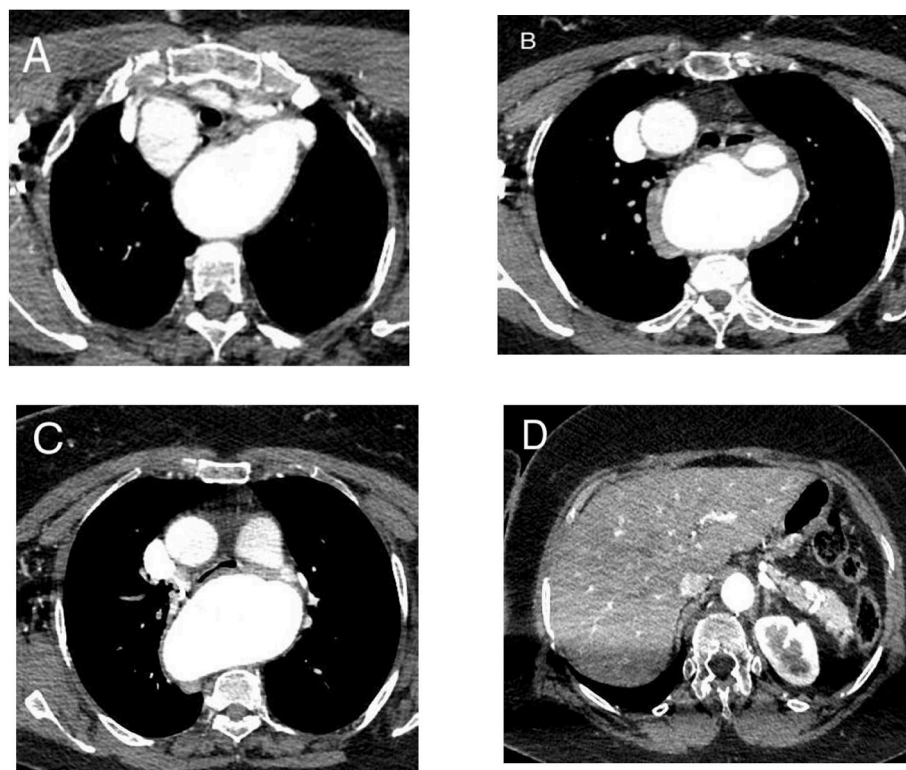
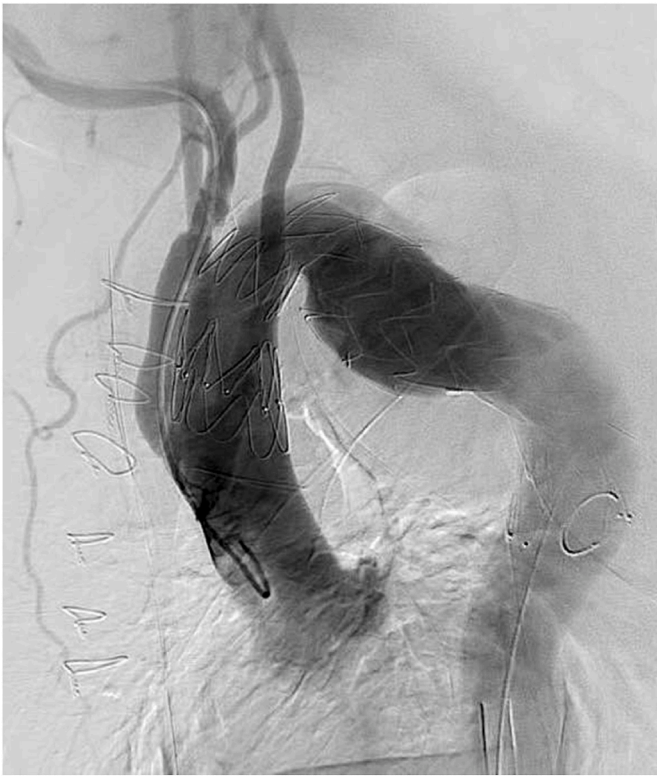

Fig. 1. CT angiogram showing aneurysmal Kommerell's diverticulum (A). Aneurysmal isthmus anterior to the vertebral body (B). Proximal descending aorta, compressing the esophagus and carina (C). Normal sized abdominal aorta (D).



**Fig. 3.** Post-operative angiography showing stent in the distal ascending aorta, arch and proximal descending aorta. Debranched head and neck vessels were reimplanted to the ascending aorta via median sternotomy.

aerodigestive symptoms [3]. Three scenarios can be considered for surgical management of a Kommerell's diverticulum, depending on extension onto the aorta [5]. Extension into the distal arch, requiring total arch replacement and ligation of the diverticulum. The aneurysmal diverticulum may also extend into the descending aorta, requiring descending aortic replacement via thoracotomy [5]. Lastly, involvement of ascending aorta, arch and descending aortic aneurysmal extension requires extensive graft replacement of involved aorta and diverticulum. Total arch and proximal aortic aneurysm repair is extensive and has higher morbidity when done open compared to hybrid procedure [6]. Type one hybrid procedure with open debranching of arch vessels to the ascending aorta and stent placement in the distal ascending aorta, arch and proximal descending aorta was done (Fig. 3). Factors considered against open repair included the expected morbidity in such a critical patient, anticipated difficulty in accessing the distal arch in a right sided arch, as well as the position of the descending aorta. So more than just one surgical access site would be needed for adequate exposure of the affected vessels. Such complex cases are best managed using a multi-disciplinary approach. However, potential pitfalls include poor judgement of position of proximal landing zone as opposed to left sided arch during endovascular repair.

#### 4. Conclusion

Single stage hybrid management of aneurysmal vascular rings and aneurysmal Kommerell's diverticulum in adults can safely be considered in high risk patients. A multidisciplinary team approach involving intensivists, radiologists, nursing staff, anesthesiologists, cardiothoracic and vascular surgeons is the key to the management.

#### 5. Consent statement

Written informed consent was obtained from the patient for

publication of this case report and accompanying images. A copy of the written consent is available for review by the Editor-in-Chief of this journal on request.

#### Ethical approval

N/A.

#### Sources of funding

None.

#### Author contribution

Dambuza Nyamande: writing the paper. Siphosenkosi Mazibuko: writing the paper.

#### Registration of research studies

Name of the registry: N/A.

Unique Identifying number or registration ID: N/A.

Hyperlink to your specific registration (must be publicly accessible and will be checked): N/A.

#### Guarantor

Dambuza Nyamande.

#### Provenance and peer review

Not commissioned, externally peer-reviewed.

#### Declaration of competing interest

This case was presented at Society of Cardiothoracic Surgeons of South Africa 2019 congress DURBAN.

There are no financial disclosures. The authors are accountable for all aspects of the work in ensuring that questions related to the accuracy or integrity of any part of the work are appropriately investigated and resolved.

#### Acknowledgements

1. 2019 organizing committee of Society of Cardiothoracic Surgery South Africa including Dr Darshan Reddy and Prof Rob Kinsley.

#### Appendix A. Supplementary data

Supplementary data to this article can be found online at <https://doi.org/10.1016/j.amsu.2021.102778>.

#### References

- [1] R.A. Agha, T. Franchi, C. Sohrabi, G. Mathew, for the SCARE Group, The SCARE 2020 guideline: updating consensus surgical CASE REport (SCARE) guidelines, *Int. J. Surg.* 84 (2020) 226–230.
- [2] Rosemarie E. Hardin, Gregory R. Brevetti, Michael Sanusi, et al., Treatment of symptomatic vascular rings in adults, *Texas heart institution journal* 32 (2003) 411–415.
- [3] Czerny Martin, Jürg Schmidli, Sabine Adler, et al., Recommendations for the treatment of thoracic aortic pathologies involving the aortic arch, *Eur. J. Vasc. Endovasc. Surg.* (2018) 1–13.
- [4] Nicholas T. Kouchoukos, Eugene H. Blackstone, et al., *Kirklin/Barratt-Boyes Cardiac Surgery*, fourth ed., Elsevier Saunders, Philadelphia, 2013.
- [5] Yuki Ikeno, Yojiro Koda, Koki Yokawa, et al., Graft replacement of Kommerell diverticulum and in situ aberrant subclavian artery reconstruction, *Ann. Thorac. Surg.* 107 (2019) 770–779.
- [6] P. Vallabhajosyula, W. Szeto, N. Desai, J.E. Bavaria, Type 1 and Type 2 hybrid aortic arch replacement: postoperative and mid-term outcome analysis, *Ann Cardiothoracic surgery* 2 (3) (2013) 280–287.