

Arthroscopic Screw Fixation Technique for Transverse Glenoid Fractures



Arasch Wafaisade, M.D., Paola Kappel, M.D., Thomas R. Pfeiffer, M.D.,
Christophe Lambert, M.D., and Marc Banerjee, M.D.

Abstract: Transverse glenoid fractures with a cranial coracoglenoidal fragment (Ideberg type III) can lead to detrimental post-traumatic sequelae. Open surgery requires an extensive surgical approach. Arthroscopic procedures are highly challenging with respect to both fracture reduction and screw osteosynthesis. We present a reproducible arthroscopic technique for a dislocated transverse glenoid fracture using 5 standard portals. Grasping the coracoid with a small, serrated reduction clamp through the anterior portal allows simple and sufficient reduction. Safe screw osteosynthesis can then be performed from cranially without the need to create a Neviaser portal.

Introduction (With Video Illustration)

Surgical treatment of glenoid fractures is challenging, especially for transverse fractures (Ideberg type III).^{1,2} This fracture type is characterized by a transverse fracture line through the glenoid cavity resulting in a separation of the cranial coracoglenoidal unit from the inferior aspect of the glenoid and the scapula.^{1,3}

Open reduction with screw osteosynthesis has been the standard of care. However, this is associated with a high complication rate due to the extensive surgical approach.^{4,5} Since 2011, arthroscopic methods have been described in few cases, mostly with very good results.^{6,7} However, these procedures are highly demanding, since

fracture reduction is technically challenging. Furthermore, screw osteosynthesis through the Neviaser portal is associated with increased risk for a lesion of the suprascapular nerve.⁸ The presented arthroscopic technique for dislocated transverse glenoid fractures (Fig 1) allows a simple and sufficient reduction with safe screw osteosynthesis from cranially using 5 standard portals without the need to create a Neviaser portal (Video 1).

Surgical Technique

The patient is placed in the beach chair position (Fig 2). A standard posterior portal and an anterior portal through the rotator interval are established. Hematoma

From the Department of Trauma and Orthopedic Surgery, University of Witten/Herdecke, Cologne-Merheim Medical Center (A.W., P.K., T.R.P., C.L.); and Department of Orthopedic Surgery and Sports Traumatology, Atos MediaPark Clinic (M.B.), Cologne, Germany.

The authors report the following potential conflicts of interest or sources of funding: A.W. is a consultant for Stryker; received travel costs from Arthrex and DePuy-Synthes; and is a consultant for and received travel costs from Smith & Nephew. Full ICMJE author disclosure forms are available for this article online, as [supplementary material](#).

Received May 9, 2021; accepted July 18, 2021.

Address correspondence to Arasch Wafaisade, M.D., Department of Trauma and Orthopedic Surgery, University of Witten/Herdecke, Cologne-Merheim Medical Center, Ostmerheimer Str. 200, D-51109 Cologne, Germany. E-mail: wafaisadea@kliniken-koeln.de

© 2021 THE AUTHORS. Published by Elsevier Inc. on behalf of the Arthroscopy Association of North America. This is an open access article under the CC BY-NC-ND license (<http://creativecommons.org/licenses/by-nc-nd/4.0/>). 2212-6287/21749

<https://doi.org/10.1016/j.eats.2021.07.034>

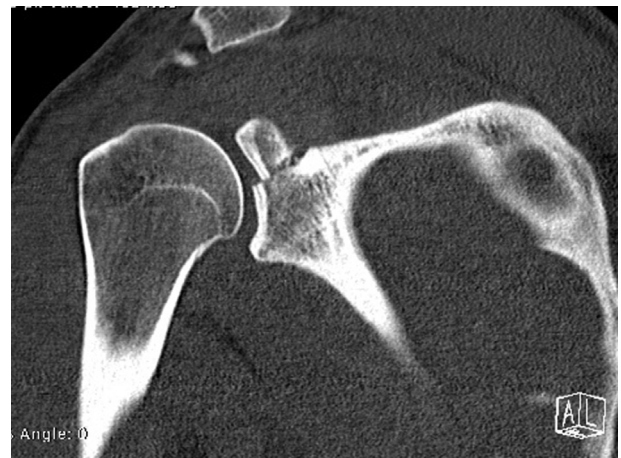

Fig 1. Preoperative computed tomography of the right shoulder (coronal view), showing the glenoid fracture Ideberg type III, characterized by a transverse fracture line through the glenoid cavity.

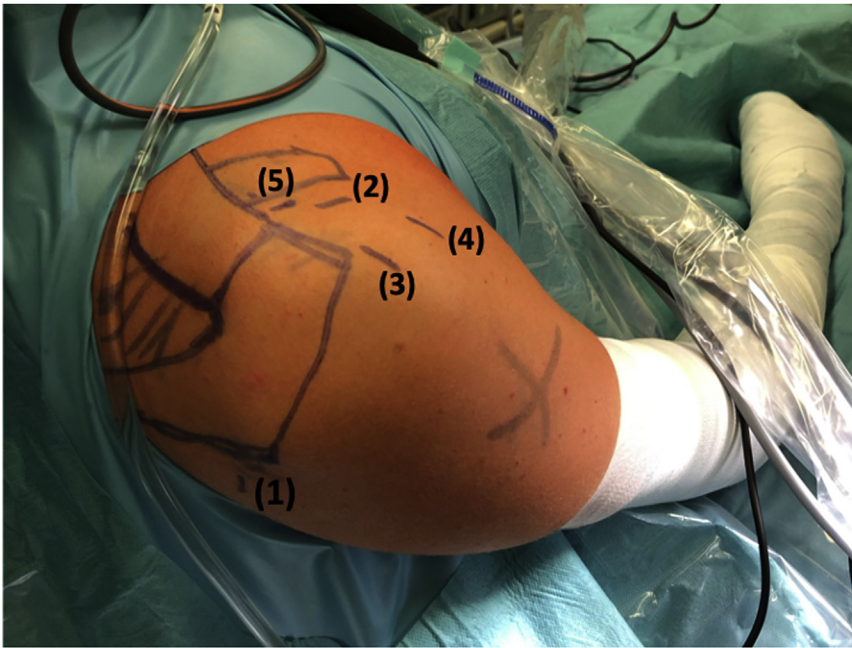


Fig 2. View of the right shoulder with the patient in the beach-chair position. Five portals are required: a standard posterior portal (1) for the initial diagnostic arthroscopy; an anterior portal (2) in the rotator interval; a high anterolateral portal (3) perpendicular to the glenoid used as the main viewing portal; a low anterolateral portal (4); and a high anteromedial portal (5) just anterior to the lateral clavicle for introduction of the screw.

is removed using a shaver. In the presented case, diagnostic arthroscopy showed a SLAP lesion (Snyder type II) (Fig 3). Thus, tenotomy of the long biceps head with suprpectoral tenodesis was performed.

First, the impacted transverse glenoid fracture is mobilized applying an elevatorium. Then, the rotator interval is released thoroughly to expose the conjoint tendon and the coracoid process. Also, the coracoacromial ligament is released from the lateral aspect of the coracoid, enabling placement of a small, serrated

reduction clamp (“lobster claw”) through the anterior portal (Fig 4). The coracoid can be grasped firmly with the clamp (Fig 5). The manipulation of the clamp allows easy mobilization and reduction of the coracoglenoid fragment, just like using an extracorporeal “joystick” (Fig 6).

The arthroscope is then switched from the posterior to the high anterolateral portal, where it remains for the rest of the procedure. The reduction clamp remains in the anterior portal, clamped to the coracoid, sustaining fracture reduction.

As the rotator interval has been released, the position of the arthroscope in the high anterolateral portal

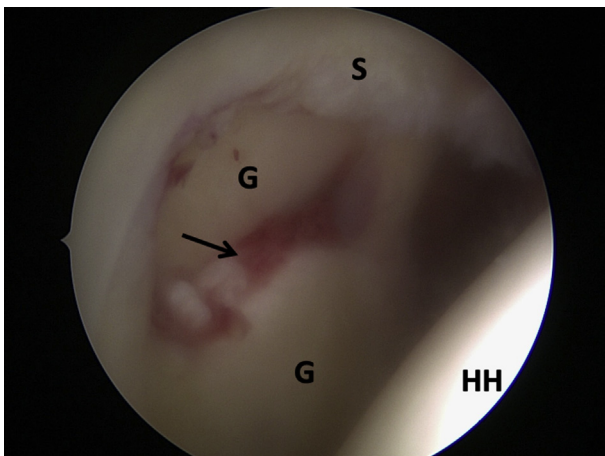


Fig 3. The patient is in the beach-chair position and arthroscopy of the right shoulder is performed. The arthroscope is introduced through the posterior portal showing the glenoid (G) and the humeral head (HH). After fracture hematoma has been removed, the dislocated fracture is identified (arrow). Furthermore, a lesion of the SLAP complex can be visualized (S).

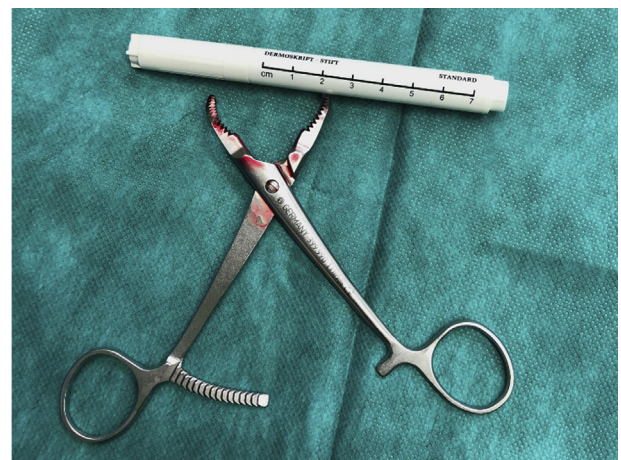

Fig 4. Small, serrated reduction clamp (“lobster claw”), which is introduced through the anterior portal to clamp the coracoid.

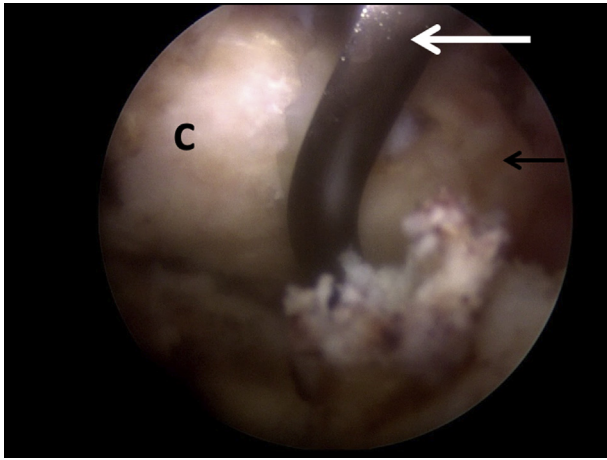


Fig 5. The patient is in the beach-chair position and arthroscopy of the right shoulder is performed. The arthroscope is still in the posterior portal viewing into the released rotator interval showing the serrated reduction clamp (white arrow) grasping the coracoid process (C). The black arrow marks the tip of the coracoid process.

allows to alternate between the glenohumeral and the pre-coracoidal/subacromial view.

Using a low anterolateral portal, the lateral aspect of the coracoid base can be released from residual soft tissue. Through the posterior portal, a small Langenbeck retractor can be introduced and used to retract the anterior border of the supraspinatus tendon posteriorly. Thus, the cranial aspect of the glenoid bone at the 12:00- to 12:30-o'clock position is exposed.

For the entry point of the cannulated screw, a high anteromedial portal is established lateral to the coracoid

base, just anterior to the distal clavicle. Through this portal, the K-wire of a cannulated small-fragment osteosynthesis system (ASNIS 4.0 mm; Stryker, Warsaw, IN) is introduced and drilled into the cranial glenoid fragment at the 12:30-o'clock position (Fig 7). Still, the arthroscope remains in the high anterolateral portal to enable to change repeatedly between the 2 perspectives: first, the glenohumeral view on the glenoid fracture line, and second, viewing cranially toward the lateral base of the coracoid to control the entry point of the K-wire.

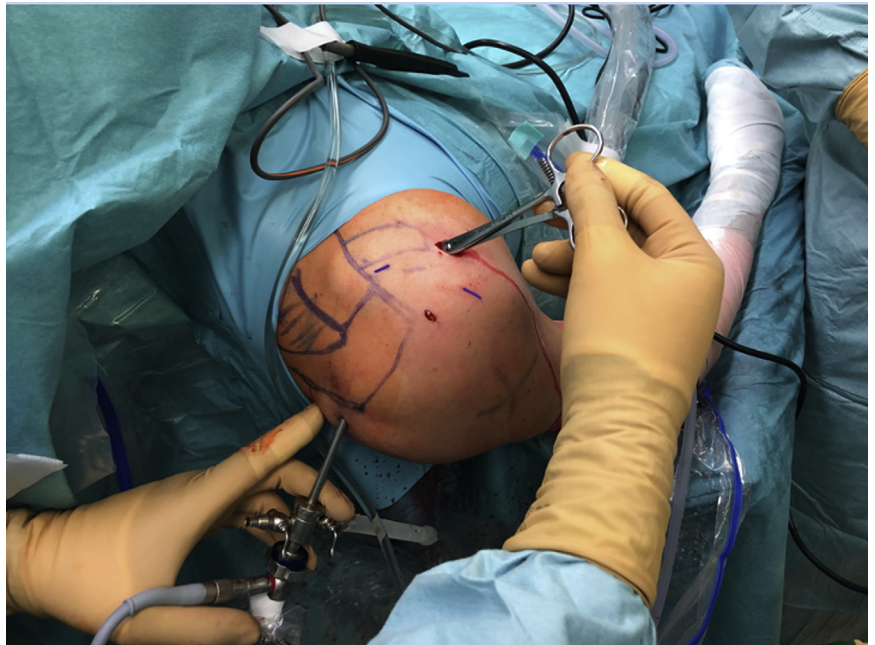
With the cranial fragment held in the correct reduction, the K-wire is further advanced under power into the caudal fragment. During this step preliminary retention is controlled arthroscopically, to avoid penetration of the glenoid surface with the K-wire (Table 1). According to the arthroscopic view, fluoroscopy in the anteroposterior plane shows adequate fracture reduction with the K-wire parallel to the joint line (Fig 8).

Next, the entry point of the K-wire is predrilled using a cannulated 2.7-mm drill. Then, a cannulated, self-cutting 4.0-mm screw is inserted via the K-wire. As the screw is advanced tight, adaptation of the fracture line can be appreciated (Fig 9). The K-wire and the clamp are removed. Finally, portals are closed, a sterile dressing is applied, and the shoulder is immobilized in a sling.

Postoperative Care

Postoperative computed tomography of the right shoulder is obtained with 3-dimensional reconstruction,⁹ which in this case showed excellent fracture

Fig 6. View of the right shoulder with the patient in the beach-chair position. The reduction clamp has been inserted through the anterior portal and clamped onto the coracoid process. This allows extracorporeal manipulation and reduction of the cranial coracoglenoid fragment, visualized with the arthroscope in the posterior portal.



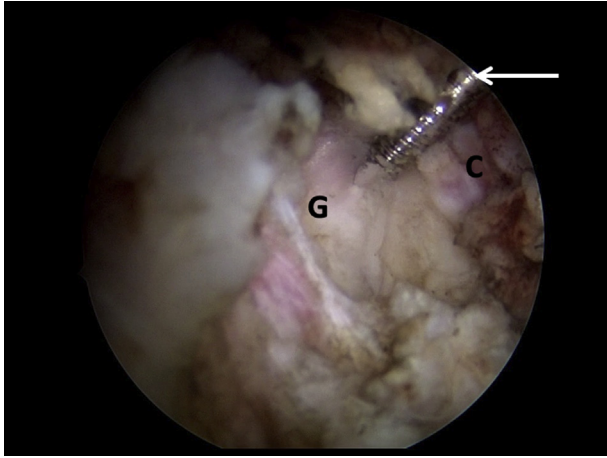


Fig 7. The patient is in the beach-chair position and arthroscopy of the right shoulder is performed. The arthroscope is now in the high anterolateral portal visualizing the cranial aspect of glenoid (G) and the lateral aspect of the base of the coracoid process (C). The white arrow marks the K-wire introduced through the high anteromedial portal anterior to the distal clavicle.

reduction (Fig 10). The shoulder is immobilized with a sling for 6 weeks and passive motion is limited to 90° of flexion and abduction. As radiograph controls shows bony healing, active mobilization with free range of motion can be initiated after 6 weeks.

Discussion

Scapula fractures involving the glenoid are rare, and treatment strategies are discussed controversially, since post-traumatic sequelae can be detrimental. A step in the joint line larger than 4 mm has been proposed as a critical threshold in favor of surgical therapy.^{3,4} In the presented case, surgery was indicated, as the injury resulted in both a transverse glenoid fracture (Ideberg type III) and a traumatic SLAP lesion, as demonstrated on magnetic resonance imaging.

It has to be discussed critically that the described technique requires a thorough and extensive release of

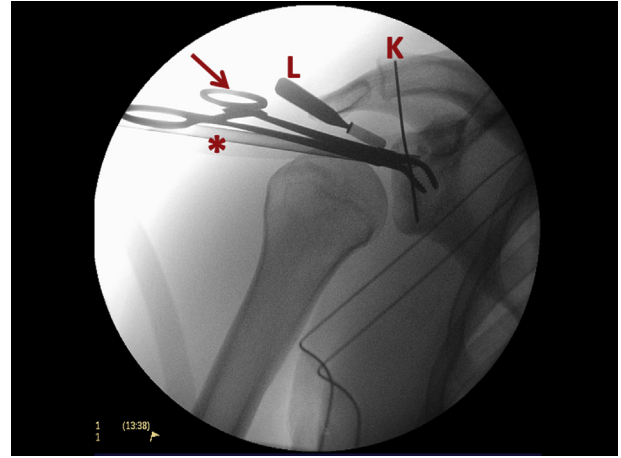


Fig 8. Intraoperative anteroposterior fluoroscopy of the right shoulder obtained after placement of the cranial K-wire (K) from a high anteromedial portal. Also shown are the serrated reduction clamp (arrow) in the anterior portal grasping the coracoid process, a small Langenbeck retractor (L) introduced via the posterior portal to retract the anterior border of the supraspinatus tendon posteriorly, and the trocar of the arthroscope (asterisk), which is left in the high anterolateral portal during fluoroscopy.

the coracoacromial ligament with exposure of the lateral aspect of the coracoid. However, this release facilitates both defining the correct entry point of the screw and placement of the reduction clamp via the anterior portal according to the maneuver described by Tao and Garrigues.⁶ Furthermore, there is no evidence from the literature or from our own experience that this release might have any negative consequences, e.g., a “superior escape” of the humeral head.

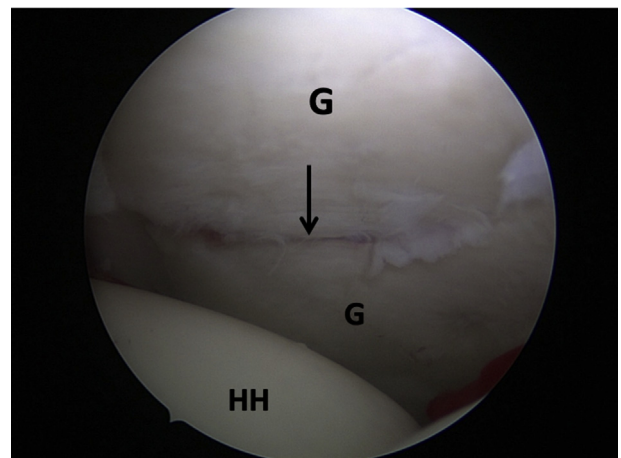


Fig 9. Arthroscopic view of the right shoulder with the patient in the beach-chair position. The arthroscope is in the high anterolateral portal allowing an en face view of the glenoid (G) and the humeral head (HH). The picture shows the final result at the end of the procedure, with anatomic reduction of the fracture (black arrow).

Table 1. Pearls and Pitfalls of the Arthroscopic Screw Fixation Technique

Pearls

- A small serrated reduction clamp grasping the coracoid facilitates reduction from extracorporeal
- A high anteromedial portal anterior to the distal clavicle allows placement of a screw from the cranial glenoid
- Anteroposterior fluoroscopy helps in screw placement
- Thorough release of the rotator interval allows simultaneous visualization of the coracoid and the glenoid fracture line

Pitfalls

- Penetration of the glenoid surface with the K-wire might lead to additional injury of the cartilage
- As the cranial coracoglenoidal fragment is displaced, the coracoid dissection must be carried out carefully to avoid injury to the conjoint tendon

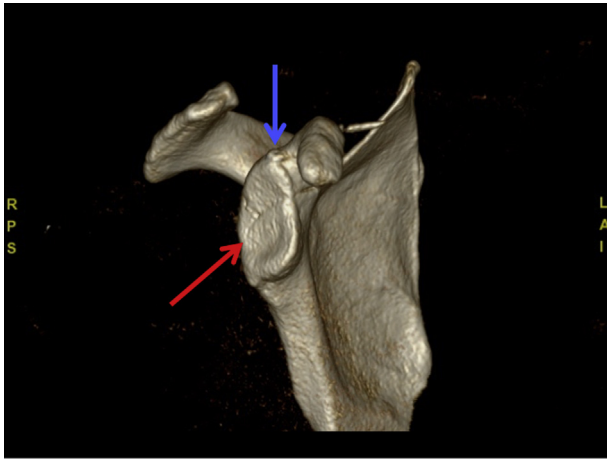


Fig 10. Computed tomography of the right shoulder with 3-dimensional reconstruction and subtraction of the humerus 2 days postoperatively after screw osteosynthesis of the displaced transverse glenoid fracture (Ideberg type III). Fracture reduction is excellent, displaying no step of the joint surface. The red arrow marks the fracture line. The blue arrow marks the head of the cannulated screw.

The entry point of the K-wire through the high anteromedial portal might result in a screw trajectory not completely perpendicular to the fracture line.¹⁰ However, it spares the creation of a Nevasier portal, thus minimizing the risk of suprascapular nerve lesion or of penetration of the supraspinatus tendon.⁸

The arthroscopic procedure substantially diminishes the extensive soft-tissue trauma as compared with open surgery, thus reducing the risk of potential complications.^{2,5} In addition, further intra-articular pathologies can be treated simultaneously, such as the SLAP lesion in the current case (Table 2). Also, due to the location of the fracture line deep in the glenohumeral joint, a much better visualization and control of fracture reduction is possible using the arthroscopic technique.

The small, serrated reduction clamp on the coracoid placed via the anterior portal allows manipulation and reduction of the whole cranial coracoglenoid

fragment like an extracorporeal “joystick,” with much less effort than in other described techniques that apply combinations of multiple K-wires and intra-articular instrumentation.⁷

Furthermore, due to a thorough release of the rotator interval, the arthroscope in the high anterolateral portal allows to constantly alternate the perspective between (1) the glenohumeral view with the fracture line and (2) the cranial glenoid at the lateral aspect of the coracoid base for the entry point of the screw.

Transverse glenoid fractures with a coracoglenoid fragment (Ideberg type III) can result in detrimental post-traumatic sequelae. Surgical treatment using arthroscopic techniques is challenging but effective and reproducible. Thorough knowledge of arthroscopic shoulder anatomy is crucial.

References

1. Ideberg R, Grevsten S, Larsson S. Epidemiology of scapular fractures. Incidence and classification of 338 fractures. *Acta Orthop Scand* 1995;66:395-397.
2. Mayo KA, Benirschke SK, Mast JW. Displaced fractures of the glenoid fossa. Results of open reduction and internal fixation. *Clin Orthop Relat Res* 1998;347:122-130.
3. Krüger D, Kraus N, Gerhardt C, Scheibel M. Technik und Grenzen arthroscopischer Versorgung von Glenoid- und Skapulafrakturen. *Obere Extrem* 2013;8:78-86.
4. Königshausen M, Coulibaly O, Nicolas V, Schildhauer TA, Seybold D. Results of non-operative treatment of fractures of the glenoid fossa. *Bone Joint J* 2016;98-B:1074-1079.
5. Kavanagh BF, Bradway JK, Cofield RH. Open reduction and internal fixation of displaced intra-articular fractures of the glenoid fossa. *J Bone Joint Surg Am* 1993;75:479-484.
6. Tao MA, Garrigues GE. Arthroscopic-assisted fixation of Ideberg type III glenoid fractures. *Arthrosc Tech* 2015;4:e119-e125.
7. Yang HB, Wang D, He XJ. Arthroscopic-assisted reduction and percutaneous cannulated screw fixation for Ideberg type III glenoid fractures: A minimum 2-year follow-up of 18 cases. *Am J Sports Med* 2011;39:1923-1928.
8. Haughton BA, Serrano-Pedraza I, Boada E, Candal-Couto JJ. The Nevasier portal for superior glenoid anchor insertion: An anatomic study. *J Orthop Surg (Hong Kong)* 2015;23:301-303.
9. Zhang H, Zhu Y, Lu Y, Li F, Jiang C. Establishment of a true en face view in the evaluation of glenoid morphology for treatment of traumatic anterior shoulder instability. *Arthroscopy* 2020;36:668-679.
10. Rabinowitz J, Lin JJ, Greenhouse A, Rao MV, Provencher M, Parada S, Friedman RJ, Eichinger JK. The effect of screw design and cortical augmentation on insertional torque and compression in coracoid-glenoid fixation in a sawbones model. *Arthroscopy* 2020;36:689-695.

Table 2. Advantages and Disadvantages of the Arthroscopic Screw Fixation Technique

Advantages
Completely arthroscopic technique, just requiring standard portals
Concomitant intra-articular injuries can be addressed
No need for Nevasier portal
Disadvantages
Technically challenging
Not applicable in multifragmentary scapula fractures with concomitant coracoid fracture