


Massive Upper Gastrointestinal Bleeding Following LAMS (Lumen-Apposing Metal Stent) Placement

Journal of Investigative Medicine High
Impact Case Reports
Volume 8: 1–4
© 2020 American Federation for
Medical Research
DOI: 10.1177/2324709620965800
journals.sagepub.com/home/hic


Bhavesh Gajjar, MD¹ , Tyler Aasen, DO¹,
Puneet Goenka, MD¹, and Vijay Gayam, MD, FACP²

Abstract

Pancreatic pseudocyst is a common complication of pancreatitis. Pseudocysts may require decompression when they become painful, infected, or start compressing surrounding organs. Decompression is achieved by endoscopic cystogastrostomy. Recently, the use of lumen-apposing metal stent (LAMS) for cystogastrostomy has gained popularity due to ease of use and high technical success. LAMS has a wider lumen, which allows for direct endoscopic necrosectomy in the cases of walled-off necrosis. Our patient is a 30-year-old male who presented with massive hematemesis and dizziness. He had a history of chronic alcohol-induced pancreatitis. Three weeks before the presentation, he underwent a cystogastrostomy with LAMS placement to treat a 10-cm walled-off necrosis. Urgent computed tomography (CT) scan did not reveal any acute finding suggestive of bleeding. Esophagogastroduodenoscopy showed blood protruding from the LAMS with a large clot formation. Attempts to stop bleeding were unsuccessful. He underwent CT angiography of the abdomen. CT angiography showed a bleeding pseudoaneurysm (PA) believed to be a complication of the LAMS. Subsequently, multiple coils were placed in the splenic artery near the PA. The patient continued to improve without a further drop in hemoglobin and was eventually discharged. PA formation and subsequent rupture is a rare delayed complication of LAMS. It may lead to massive gastrointestinal bleeding with a high mortality rate. Diagnostic delays have resulted in increased mortality by 60%. In this article, we present a case of massive gastrointestinal bleeding due to a ruptured splenic artery PA presenting as a delayed complication of LAMS.

Keywords

complication of AXIOS stent, ruptured pseudoaneurysm, pancreatic fluid collection

Introduction

Pseudocyst formation is a common complication of pancreatitis. Pseudocysts may require decompression when they become symptomatic, infected, or start compressing surrounding organs. Decompression can be achieved endoscopically by cystogastrostomy. Recently, the use of lumen-apposing metal stent (LAMS) for cystogastrostomy has gained popularity due to ease of use and high technical and long-term success.¹

Pseudoaneurysm (PA) is a rare complication of pancreatitis. Ruptured PA may lead to massive gastrointestinal (GI) bleeding and has a high mortality rate.^{2,3} PA formation and rupture of PA is a rare complication of LAMS. Diagnostic delays have resulted in increased mortality by up to 60%.³ We present a case of massive GI bleeding due to a ruptured splenic artery PA presenting as a delayed complication of LAMS. To our knowledge, this represents a rare complication with only a few reported cases.

Case Presentation

A 30-year-old male was hospitalized for massive hematemesis and lightheadedness. He had a history of chronic alcohol-induced pancreatitis. Three weeks before the presentation, he underwent a cystogastrostomy with LAMS (AXIOS; Boston Scientific) placement to treat a 10-cm walled-off necrosis (WON). He presented to an outside facility with hemodynamic instability. Computed

¹East Tennessee State University, Johnson City, TN, USA

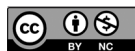²Interfaith Medical Center, Brooklyn, NY, USA

Received July 20, 2020. Revised August 30, 2020. Accepted September 5, 2020.

Corresponding Author:

Bhavesh Gajjar, MD, Department of Internal Medicine, Quillen College of Medicine, East Tennessee State University, VA Building I, Box 70622, Johnson City, TN 37614-0622, USA.

Email: gajjarb@etsu.edu



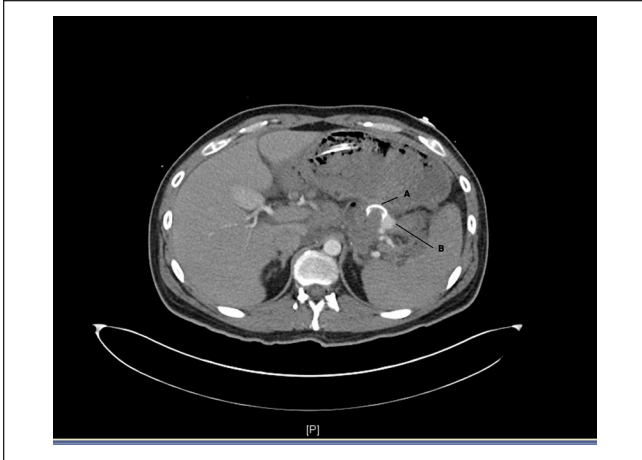

Figure 1. Computed tomography angiography for abdomen showing. (A) AXIOS stent connecting stomach and pseudocyst. (B) Bleeding from the posterior splenic artery.

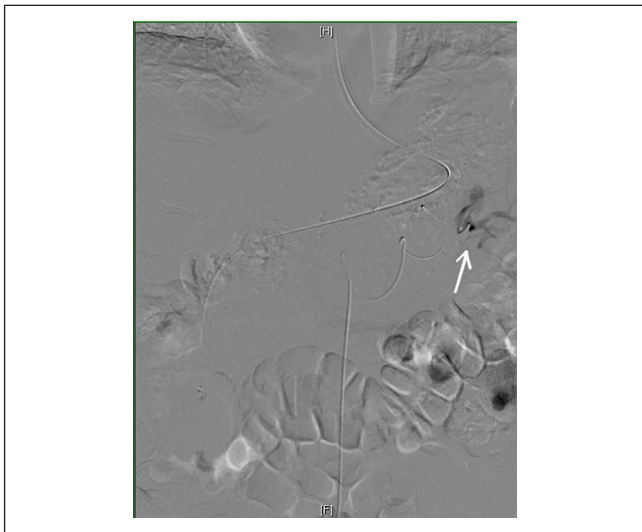


Figure 2. Mesenteric artery angiography performed by Interventional radiology. The black area secondary to extravasation of contrast represents bleeding from the pseudoaneurysm.

tomography (CT) scan did not reveal any acute finding suggestive of bleeding. Esophagogastroduodenoscopy (EGD) showed a large blood clot protruding from the LAMS in the stomach. After multiple attempts to control bleeding were unsuccessful, the patient was transferred to our center for a higher level of care.

On arrival, the patient was tachycardic and hypotensive. Laboratory data showed hemoglobin was 8.2 mg/dL, platelets were 177 000/ μ L, and international normalized ratio was 1.3. The patient received a blood transfusion. Subsequently, he underwent CT angiography (CTA) of the abdomen. CTA

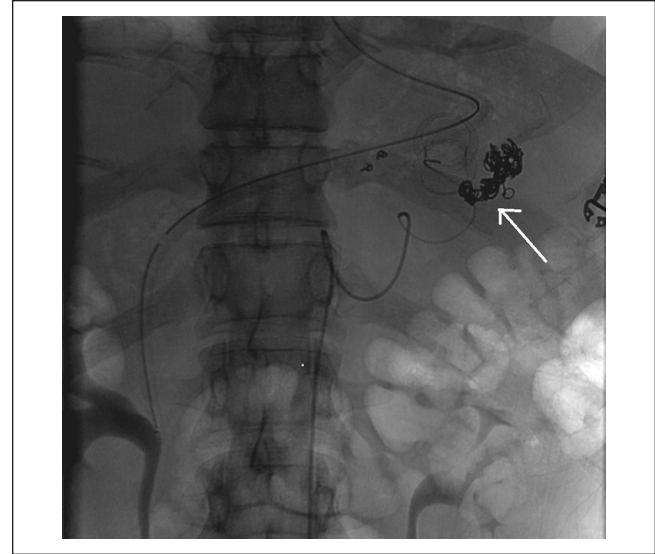


Figure 3. Successful embolization of the bleeding pseudoaneurysm with multiple coils performed a catheter through mesenteric.

showed a ruptured PA arising from the distal splenic artery. The PA was directly posterior to the LAMS, considered a complication of LAMS (Figure 1). The patient was sent for mesenteric angiography, and multiple coils were placed in the splenic artery near the PA (Figures 2 and 3). The patient continued to improve without a further drop in hemoglobin and was eventually discharged from the hospital. Subsequently, the LAMS was removed after the near resolution of the WON.

Discussion

Pancreatic fluid collections are a common complication of acute and chronic pancreatitis. Pseudocysts may require decompression when they become painful, infected, or start compressing surrounding organs. Decompression can be achieved by endoscopic cystogastrostomy, and this technique has been increasingly used in recent years. Endoscopic cystogastrostomy with LAMS is gaining acceptance due to the ease of use and better technical and long-term success rates. Also, the LAMS provides a wider lumen to perform direct endoscopic necrosectomy and thus has superior treatment efficacy.⁴ One of the rare but life-threatening side effects of LAMS is delayed bleeding due to ruptured PA.

Pseudoaneurysm formation and subsequent rupture could occur as a rare complication of the LAMS. Ruptured PA causes up to 60% of massive bleeding episodes following pancreatitis.² A delay in diagnosis has a mortality of 25% to 60%. Timely diagnosis and treatment can reduce mortality to <15%,^{2,5} while mortality in patients treated conservatively could be up 90%.³

Few case reports have confirmed delayed bleeding due to ruptured PA as a complication LAMS.^{6,7} A possible mechanism for bleeding in the LAMS is its bi-flanged design.⁶ Flanges keep the gastric and pseudocyst walls tightly opposed. After cystogastrostomy, the size of pseudocyst reduces due to drainage of fluid from the pseudocyst into the gastric cavity. The bi-flanged design does not allow mobility of walls or the stent. The lack of mobility may create tension over the wall and surrounding vasculature leading to PA formation or bleeding. Around 4 weeks after LAMS placement, cysts reduce in the size significantly, and the likelihood of delayed bleeding increases. Bang et al compared AXIOS and plastic stent used for cystogastrostomy, and found that delayed bleeding did not occur in patients who had plastic stents. They proposed that unlike LAMS, plastic stents gravitate freely into the stomach with the collapse of WON.⁶

Bleeding due to the rupture of PA may have a variety of presentations. The most common clinical presentation of ruptured PA is abdominal pain.^{2,8} The second common presentation is upper or lower GI bleeding in the form of hematochezia or melena. Rupture into pancreatic duct or bile duct presents as hemosuccus pancreaticus or hemobilia, respectively. The patient could have signs of hemodynamic instability as bleeding is severe in many cases.^{8,9}

Bleeding due to the rupture of PA is challenging to diagnose. Noncontrast CT scan and color Doppler have low predictivity of diagnosing a PA. As with our patient, initial CT scan and EGD were not diagnostic, which can happen if bleeding is occurring through the lumen of LAMS into the stomach. CTA is the best initial diagnostic test with excellent sensitivity and specificity.^{5,8,10} CTA also assists in planning therapeutic intervention. In the event of significant bleeding, ruptured PA is safely and successfully managed by angiography followed by transcatheter arterial embolization.¹¹ The success rate of transcatheter arterial embolization in recent studies is 95% to 97%.^{10,12} Even patients in critical condition can tolerate embolization better than surgery. Repeat embolization may be attempted in the event patient starts bleeding after initial hemostasis. Surgery is reserved for patients who remain unstable after a failed embolization attempt.^{5,10,12}

Conclusion

We present a case of massive GI bleeding due to ruptured PA believed to occur secondary to LAMS eroding into a PA. Bleeding from a PA may be very difficult to diagnose both clinically and radiographically. The provider should have a high suspicion of a ruptured PA once other causes of bleeding are ruled out by an EGD. Timely angiogram and embolization could reduce mortality significantly. Current literature review urges to perform a CT imaging 3 to 4 weeks after LAMS placement and plan early removal of the stent after cyst collapse is demonstrated.

Authors' Note

Prior submission to ACG 2019 as a poster. *The American Journal of Gastroenterology*. 2019;114:S1111. doi:10.14309/01.ajg.0000597480.74669.60.

Author Contributions

Dr Bhavesh Gajjar—literature search, complete write-up. Other authors edited the draft and performed critical review.

Declaration of Conflicting Interests

The author(s) declared no potential conflicts of interest with respect to the research, authorship, and/or publication of this article.

Funding

The author(s) received no financial support for the research, authorship, and/or publication of this article.

Ethics Approval

Our institution does not require ethical approval for reporting individual cases or case series.

Informed Consent

Written informed consent was obtained from the patient for anonymized patient information to be published in this article.

ORCID iD

Bhavesh Gajjar  <https://orcid.org/0000-0002-5306-3916>

References

- Siddiqui AA, Adler DG, Nieto J, et al. EUS-guided drainage of peripancreatic fluid collections and necrosis by using a novel lumen-apposing stent: a large retrospective, multicenter US experience (with videos). *Gastrointest Endosc*. 2016;83:699-707. doi:10.1016/j.gie.2015.10.020
- Balthazar EJ, Fisher LA. Hemorrhagic complications of pancreatitis: radiologic evaluation with emphasis on CT imaging. *Pancreatol*. 2001;1:306-313. doi:10.1159/000055829
- Stabile BE, Wilson SE, Debas HT. Reduced mortality from bleeding pseudocysts and pseudoaneurysms caused by pancreatitis. *Arch Surg*. 1983;118:45-51.
- Siddiqui AA, Kowalski TE, Loren DE, et al. Fully covered self-expanding metal stents versus lumen-apposing fully covered self-expanding metal stent versus plastic stents for endoscopic drainage of pancreatic walled-off necrosis: clinical outcomes and success. *Gastrointest Endosc*. 2017;85:758-765. doi:10.1016/j.gie.2016.08.014
- Chiang KC, Chen TH, Hsu JT. Management of chronic pancreatitis complicated with a bleeding pseudoaneurysm. *World J Gastroenterol*. 2014;20:16132-16137. doi:10.3748/wjg.v20.i43.16132
- Bang JY, Hasan M, Navaneethan U, Hawes R, Varadarajulu S. Lumen-apposing metal stents (LAMS) for pancreatic fluid collection (PFC) drainage: may not be business as usual. *Gut*. 2017;66:2054-2056.
- Lang GD, Fritz C, Bhat T, et al. EUS-guided drainage of peripancreatic fluid collections with lumen-apposing metal stents

- and plastic double-pigtail stents: comparison of efficacy and adverse event rates. *Gastrointest Endosc.* 2018;87:150-157. doi:10.1016/j.gie.2017.06.029
8. Tessier DJ, Stone WM, Fowl RJ, et al. Clinical features and management of splenic artery pseudoaneurysm: case series and cumulative review of literature. *J Vasc Surg.* 2003;38:969-974. doi:10.1016/S0741
 9. Gabrielli D, Tagliatalata F, Mantini C, Giammarino A, Modestino F, Cotroneo AR. Endovascular treatment of visceral artery pseudoaneurysms in patients with chronic pancreatitis: our single-center experience. *Ann Vasc Surg.* 2017;45:112-116. doi:10.1016/j.avsg.2017.05.035
 10. Udd M, Leppäniemi AK, Bidel S, Keto P, Roth WD, Haapiainen RK. Treatment of bleeding pseudoaneurysms in patients with chronic pancreatitis. *World J Surg.* 2007;31:504-510. doi:10.1007/s00268-006-0209-z
 11. Phillip V, Braren R, Lukas N, Schmid RM, Geisler F. Arterial pseudoaneurysm within a pancreatic pseudocyst. *Case Rep Gastroenterol.* 2018;12:513-518. doi:10.1159/000492459
 12. Nykänen T, Udd M, Peltola EK, Leppäniemi A, Kylänpää L. Bleeding pancreatic pseudoaneurysms: management by angio-embolization combined with therapeutic endoscopy. *Surg Endosc.* 2017;31:692-703. doi:10.1007/s00464-016-5023-6
 13. DeSimone ML, Asombang AW, Berzin TM. Lumen apposing metal stents for pancreatic fluid collections: recognition and management of complications. *World J Gastrointest Endosc.* 2017;9:456-463. doi:10.4253/wjge.v9.i9.456
 14. Parsa N, Nieto JM, Powers P, et al. Endoscopic ultrasound-guided drainage of pancreatic walled-off necrosis using 20-mm versus 15-mm lumen-apposing metal stents: an international, multicenter, case-matched study. *Endoscopy.* 2020;52:211-219. doi:10.1055/a-1096-3299