

## Ocular chemical burns from accidental exposure to topical dermatological medicinal agent

Jitender Jinagal, Parul C Gupta, Gaurav Gupta,  
Kamal K Sahu<sup>1</sup>, Jagat Ram

We report a case of accidental ocular chemical injury by self-medication with a single application of a topical ayurvedic medication containing salicylic acid, phenol, and tincture iodine, which is being used in developing countries for treatment of various dermatological conditions.

**Key words:** Accidental exposure to topical drops, corneal epithelial defect, ocular chemical burns

Chemical ocular burns comprise 5.5–15.5% of all ocular trauma cases in various parts of the world.<sup>[1-3]</sup> They are a significant problem, as they may destroy the entire corneal epithelium and may extend into the limbus and fornices,<sup>[4]</sup> which subsequently leads to nonhealing epithelial defects and sometimes complete corneal melts. Therefore, such injuries should be taken seriously. Chemical injuries may be caused by acidic or alkaline agents. Chemical agents commonly causing it are hydrochloric acid, sulfuric acid, nitric acid, oxalic acid, acetic acid, ammonium hydroxide, sodium hydroxide, and calcium hydroxide.<sup>[5]</sup>

Salicylic acid (Organic formula:  $C_6H_4(OH)COOH$ ) is considered a weak acid. It is obtained from bark of willow tree.<sup>[6]</sup> Ocular injury with salicylic acid has not been frequently reported in ophthalmic literature. Overall there is only one report of ocular chemical injury with 20% salicylic acid.<sup>[7]</sup> We report a case of accidental ocular chemical injury by self-medication with a single application of a topical Ayurvedic medication (containing salicylic acid, phenol, and tincture iodine), which is being used in developing countries for treatment of various dermatological conditions.

Access this article online	
<b>Quick Response Code:</b>	<b>Website:</b> www.ijournal.in
	<b>DOI:</b> 10.4103/ijournal.IJO_365_18

Advanced Eye Centre, Post Graduate Institute of Medical Education and Research, Chandigarh, India, <sup>1</sup>Department of Internal Medicine, St. Vincent Hospital, Worcester, 123 Summer Street-01608, USA

**Correspondence to:** Dr. Jagat Ram, Post Graduate Institute of Medical Education and Research, Chandigarh, India. E-mail: drjagatram@gmail.com

Manuscript received: 26.03.18; Revision accepted: 14.06.18

## Case Report

A 38-year-old male presented to our outdoor patient clinic with right eye pain, redness, and diminution of vision for 2 weeks. He had ocular irritation 2 weeks back for which he accidentally instilled a drop of topical ayurvedic medication in his right eye considering it as artificial tears, which led to severe ocular pain, irritation, watering, and photophobia. After instillation, he realized that those drops were being used for the treatment of dermatomycosis of his son. Patient consulted a local ophthalmologist and was referred to our center. He presented to us with the container of the ayurvedic medication [Fig. 1a].

On ophthalmological examination, the best corrected visual acuity was counting fingers in the affected eye and 6/9 in the left eye. On slit lamp biomicroscopy, there was diffuse conjunctival congestion with a polygonal-shaped corneal epithelial defect of size 6 × 5.7 mm, in the lower half of cornea involving the central visual axis with swollen rounded edges and surrounding area of corneal edema extending 2 to 2.5 mm from the edges. The epithelial defect stained positively with fluorescein. Area of epithelial defect was associated with corneal stromal thinning up to 30–40% of total stromal depth [Fig. 1b]. However, no conjunctival staining or limbal scar were seen. After saline wash, the patient was started on topical moxifloxacin 0.5%, dexamethasone 0.5%, vitamin C drops, hydroxy propyl methyl cellulose 0.3%, and carboxymethylcellulose gel 1% along with oral doxycycline 100 mg BD and tablet vitamin C 500 mg TID. The patient was also started on autologous serum. In view of the nonhealing epithelial defect, amniotic membrane transplantation was performed [Fig. 2a]. It was repeated after a period of 2 weeks to fasten healing, as mechanical shredding of amniotic membrane transplant occurred spontaneously. Preserved human amnion has been previously successfully used as a biological bandage, promoter of epithelialization, inhibitor of inflammation, and angiogenesis in chemical burns of the ocular surface,<sup>[8]</sup> though early detachment of the patch remains a major problem despite the use of multiple sutures or a protective bandage contact lens.<sup>[9]</sup>

The defect healed leaving behind a nebulo-macular corneal opacity after a period of 10 weeks [Fig. 2b].

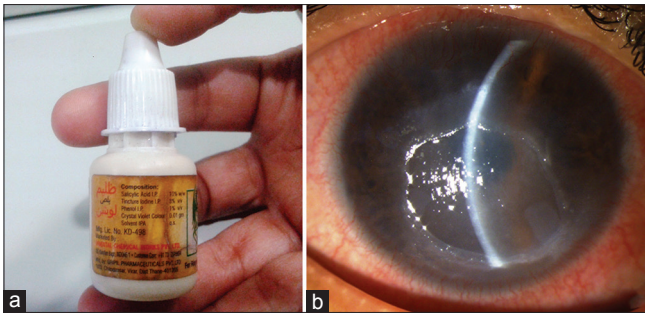
## Discussion

The chemical involved in our case that led to such severe ocular burns was an ayurvedic medicine used for the treatment of skin diseases such as ringworm, eczema, fungal infections of fingers/toes, and dermatitis. Its main constituents were 10% salicylic acid, phenol 1%, and tincture iodine (ethyl alcohol) 3%. Salicylic acid acts by quarantining the impacted region

This is an open access journal, and articles are distributed under the terms of the Creative Commons Attribution-NonCommercial-ShareAlike 4.0 License, which allows others to remix, tweak, and build upon the work non-commercially, as long as appropriate credit is given and the new creations are licensed under the identical terms.

**For reprints contact:** reprints@medknow.com

**Cite this article as:** Jinagal J, Gupta PC, Gupta G, Sahu KK, Ram J. Ocular chemical burns from accidental exposure to topical dermatological medicinal agent. Indian J Ophthalmol 2018;66:1476-7.



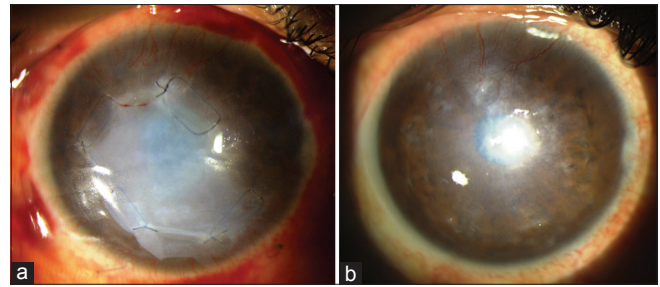
**Figure 1:** (a) Container of the ayurvedic dermatological medication showing the different constituents. (b) Slit lamp photograph of the affected eye (right) showing circumcorneal congestion, swollen corneal epithelial edges, and nonhealing epithelial defect of size  $6 \times 5.7$  mm. Corneal is hazy due to presence of stromal edema

from body moisture, thereby cutting the supply of moisture to the fungus and thus, the wound dries quickly. Salicylic acid has keratolytic properties and removes dead and infected cells, hereby removing fungus from that region. Phenol, also known as carbolic acid, is an aromatic hydrocarbon compound that acts as a mild acid. These compounds have corrosive and anesthetic properties. Tincture iodine (ethyl alcohol) is also an irritant to the ocular surface and can cause ocular surface injuries. Salicylic acid is common ingredient used in many dermatological drugs for various skin diseases and it comes in vials, which look very similar to the containers of eye drops and the patient can very easily confuse it with other eye drops, as happened in our case. Our patient instilled it accidentally, mistaking it to be lubricating eye drops and only a single application of it caused severe injuries. Severe ocular injuries with such ayurvedic medicines have not been reported earlier. Only one case of chemical injury has been reported with 20% salicylic acid.<sup>[7]</sup> Salicylic acid is a weak acid with a pH of 3.3, but still it caused extensive chemical burns and nonhealing epithelial defect. Salicylic acid solubilizes intercellular cement and causes desquamation when applied over skin.<sup>[10]</sup> In our case, it might have solubilized the tight junctions between the corneal epithelium, thereby causing de-epithelization of cornea immediately. Long-term effect can be explained by the damage caused to the limbal stem cells, leading to nonhealing ulcers.

It is best to prevent injury from this chemical and keep it away from the reach of children and elderly people. Avoid keeping it with other eye drop containers and instilling eye drops carefully only after ensuring that proper medicine is being instilled. Pharmaceutical drug companies should be guided by drug regulatory authorities regarding differential packaging and dispensing of different medicinal agents being used for altogether different body parts. The different container sizes and packaging colors should be used, so that even illiterate people can understand the difference between the commonly used drugs.

## Conclusion

In conclusion, salicylic acid, phenols, and tincture iodine are common constituents of many dermatological drugs and accidental ocular chemical injury is not uncommon and may lead to very severe chemical burns. Treatment of chemical



**Figure 2:** (a) Cornea post amniotic membrane transplantation. (b) Nebulomacular corneal opacity

burns with such agents is tedious and longstanding, so the best way to avoid ocular morbidity due to salicylic acid associated chemical burns is prevention. Similarity of these commercially available solutions with eye drop containers can make them susceptible to be used as eye drops and thus cause accidental ocular chemical burns.

## Declaration of patient consent

The authors certify that they have obtained all appropriate patient consent forms. In the form the patient(s) has/have given his/her/their consent for his/her/their images and other clinical information to be reported in the journal. The patients understand that their names and initials will not be published and due efforts will be made to conceal their identity, but anonymity cannot be guaranteed.

## Financial support and sponsorship

Nil.

## Conflicts of interest

There are no conflicts of interest.

## References

- Herr RD, White GL, Jr., Bernhisel K, Mamalis N, Swanson E. Clinical comparison of ocular irrigation fluids following chemical injury. *Am J Emerg Med* 1991;9:228-31
- Nicaeus T, Erb C, Rohrbach M, Thiel HJ. An analysis of 148 outpatient treated occupational accidents. *Klin Monbl Augenheilkd* 1996;209:A7-11
- Pegg SP, Miller PM, Sticklen EJ, Storie WJ. Epidemiology of industrial burns in Brisbane. *Burns Incl Therm Inj* 1986;12:484-90
- Pfister RR. The effects of chemical injury on the ocular surface. *Ophthalmology* 1983;90:601-9
- Saini JS, Sharma A. Ocular chemical burns—clinical and demographic profile. *Burns* 1993;19:67-9
- Mackowiak PA. Brief history of antipyretic therapy. *Clin Infect Dis* 2000;31(Suppl 5):S154-6
- Shazly TA. Ocular acid burn due to 20% concentrated salicylic acid. *Cutan Ocul Toxicol* 2011;30:84-6
- Sangwan VS, Tejwani S, Mahesh SP, Murthy R. Amniotic membrane transplantation: A review of current indications in the management of ophthalmic disorders. *Indian J Ophthalmol* 2007;55:251-60
- Letko E, Stechschulte SU, Kenyon KR, Sadeq N, Romero TR, Samson CM, *et al.* Amniotic membrane inlay and overlay grafting for corneal epithelial defects and stromal ulcers. *Arch Ophthalmol* 2001;119:659-63.
- Davies M, Marks R. Studies on the effect of salicylic acid on normal skin. *Br J Dermatol* 1976;95:187-92