

Cervical Esophageal Hemangioma Combined with Thyroid Cancer

Jong Cheol Lee, M.D.***, Jeong Won Kim, M.D.*, Yong Jik Lee, M.D.*,
Seong Rok Lee, M.D.***, Chang-Ryul Park, M.D.*, Jong-Pil Jung, M.D.*

Hemangiomas that arise in cervical esophagus are extremely rare, representing 3.3% of all benign esophageal tumors. Although endoscopic mucosal resection (EMR) and potassium titanyl phosphate/yttrium aluminum garnet (KTP/YAG) laser therapy have been used with success for small tumors, the safety and efficacy in the case of large tumors remains uncertain. We report the successful resection of cervical esophageal hemangioma through a cervical esophagotomy in a patient with thyroid cancer who needed a cervical collar incision.

Key words: 1. Esophageal neoplasms
2. Hemangioma
3. Thyroid neoplasm

CASE REPORT

A 41-year-old woman presented with intermittent pharyngeal obstruction and repeated vomiting after meals. Concerning her previous history, she had undergone the resection of a fibroma in the right side of her neck 7 years earlier, and complained of a voice change over the past 3 months. The family history was not contributory. The physical and nutritional status were good. There were no abnormal physical findings in the thoracic or abdominal regions. Palpation did not reveal any abnormalities in the superficial lymph nodes or neck. The blood biochemistry showed no abnormal findings. Neck and chest computed tomography (CT) revealed a 3.6 cm oval mass with slightly low attenuation in the upper esophagus, and a 7 mm nodule in the left lobe of the thyroid gland (Fig. 1A). Esophagogastroscope showed a 3.5 cm smooth, soft, dark purple, mobile mass which was located just beneath the upper esophageal sphinc-

ter with a possibility of airway obstruction (Fig. 1B). The thyroid nodule was diagnosed as thyroid papillary carcinoma through sonography guided fine-needle aspiration cytology. We decided to perform a combined operation for total thyroidectomy with dissection of the central neck nodes followed by resection of the esophageal tumor through cervical esophagotomy.

Under general anesthesia with a single lumen endotracheal tube, a 6 cm transverse neck skin incision just above the clavicle was performed. After meticulous dissection, total thyroidectomy with central neck node dissection was completed by a head and neck surgeon. Esophageal dissection was performed to the level of the hypopharynx. In palpation, there was no mass in the cervical esophagus even after direct visualization of the intraluminal space through cervical esophagotomy. With a laryngoscope, the mass was seen at the level of the arytenoid cartilage in the hypopharynx. After a gentle push of the mass with a long Kelly in the direction of the

*Department of Thoracic and Cardiovascular Surgery, Ulsan University Hospital, University of Ulsan College of Medicine

**Department of Otorhinolaryngology, Ulsan University Hospital, University of Ulsan College of Medicine

Received: May 19, 2011, Revised: June 1, 2011, Accepted: June 3, 2011

Corresponding author: Yong Jik Lee, Department of Thoracic and Cardiovascular Surgery, Ulsan University Hospital, University of Ulsan College of Medicine, Jeonha 1-dong, Dong-gu, Ulsan 682-714, Korea
(Tel) 82-52-250-7149 (Fax) 82-52-250-7147 (E-mail) rino2@hanmail.net

© The Korean Society for Thoracic and Cardiovascular Surgery. 2011. All rights reserved.

© This is an open access article distributed under the terms of the Creative Commons Attribution Non-Commercial License (<http://creativecommons.org/licenses/by-nc/3.0>) which permits unrestricted non-commercial use, distribution, and reproduction in any medium, provided the original work is properly cited.

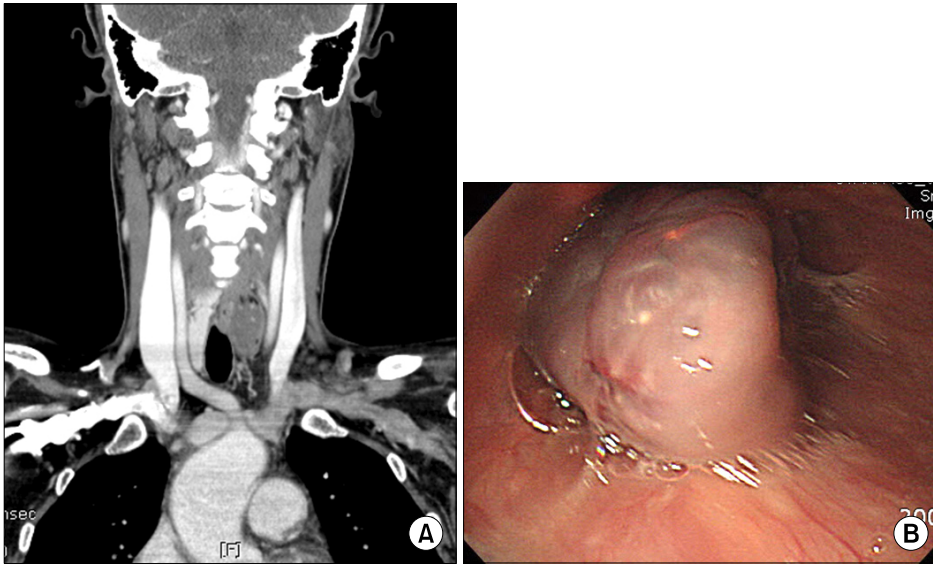


Fig. 1. (A) Neck and chest CT. 3.6 cm oval mass with slightly low attenuation in the upper esophagus and a 7 mm nodule in the left lobe of the thyroid gland. (B) Esophagogastroscopy. 3.5 cm smooth, soft, dark purple, mobile mass, which was located just beneath the upper esophageal sphincter.

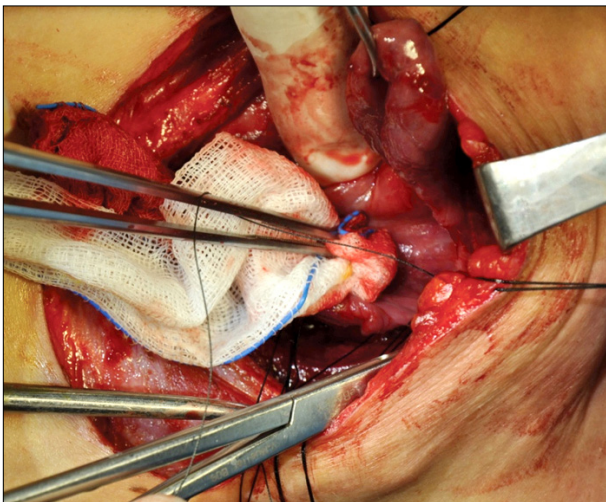


Fig. 2. Intraoperative finding. The hemangioma was pulled out of the esophagotomy opening with Allis tissue forceps.

esophagus, it could be extracted through the esophagotomy opening (Fig. 2). Mucosal resection was performed around the stalk, and the mass was removed without any complication such as hemorrhage or perforation. The esophageal mucosa and muscle were repaired with 4-0 vicryl interrupted sutures.

The histopathological findings showed irregularly dilated vascular lumens in the submucosa, suggesting cavernous hemangioma (Fig. 3). On the seventh post-operative day, an esophagogram was performed. There was no leakage or

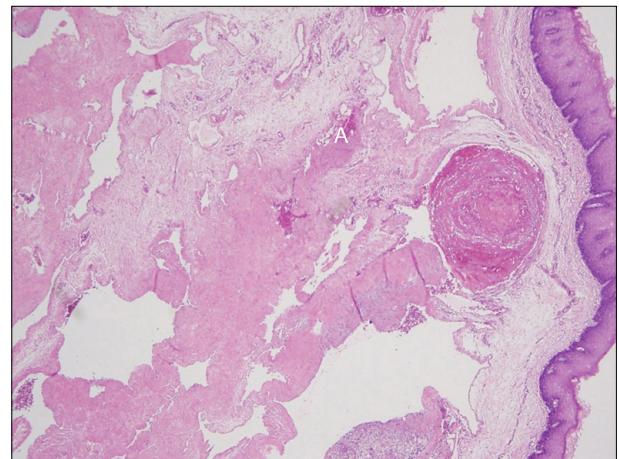


Fig. 3. Histologic findings show multiple dilated vascular channels with a focus of organizing thrombi (H&E stain, $\times 40$).

stricture. After 1 day of oral feeding, the neck drain tube was removed. The patient was discharged on the ninth post-operative day, and underwent follow-up care without incident for 1 month.

DISCUSSION

Hemangiomas are well known to arise from organs such as the skin, liver, kidney, and brain. However, esophageal hemangiomas are extremely rare, representing around 3% of all benign esophageal tumors [1]. Although the most common lo-

cation of this tumor is the lower esophagus, followed by the middle, then the upper esophagus, it may occur at any level within the esophagus [2]. It occurs in men between the fourth and seventh decades predominantly [3]. Histologically it can be grouped into cavernous, capillary, hamartomatous, and arteriovenous malformations (AVM) subtypes. A cavernous hemangioma is defined by having venous channels that are larger than the capillaries. The differential diagnosis includes leiomyoma, polyp, malignant hemangioma, Kaposi's sarcoma, benign metastasizing hemangioma, and angiosarcoma [2].

Generally, like other benign esophageal tumors, patients have no clinical symptoms or signs, but the symptoms of obstruction and hemorrhage, including dysphagia, dyspnea, hematemesis, and melena may occur [4,5]. In diagnosing the presence of esophageal hemangioma, esophagography facilitates visualization in most patients. However, the findings are non-specific, showing either a well-defined lobulated intramural mass, pedunculated intraluminal mass, or an infiltrating annular mass [2].

Endoscopic ultrasound is a more helpful method for assessing the location, depth, and size of the tumor. It enables vascular channels within the hemangioma to be demonstrated precisely, which will help the surgeons to decide whether endoscopic surgery is feasible or not [2]. Histological diagnosis by biopsy is also useful; however, hemorrhage may occur after biopsy. On a chest CT scan, esophageal hemangioma usually appears as a well-defined soft tissue mass, sometimes containing calcification, within the esophageal wall [6]. Further imaging may be carried out with the use of magnetic resonance imaging (MRI) or fluorodeoxyglucose-positron emission tomography (FDG-PET) [6].

Treatment options include esophagectomy or tumor enucleation by thoracotomy or an endoscopic approach. Recently, successful treatment has been reported with endoscopic sclerotherapy [7], and potassium titanyl phosphate/yttrium aluminum garnet (KTP/YAG) laser therapy [8]. The number of patients undergoing EMR or endoscopic polypectomy is increasing, especially when the tumor is pedunculated and small in size (<25 mm) [2]. A large tumor may predicate the need for surgical resection [6].

In this case, neck incision and central neck dissection were inevitable for the thyroidectomy. Furthermore, the location

and size of the esophageal tumor made the decision to perform EMR difficult. Therefore, we performed an esophagotomy instead of EMR. We could not identify the tumor mass in the esophagus because the redundant stalk caused it to move upward out of the upper esophageal sphincter during external palpation. Laryngoscopic visualization of the pharyngeal space revealed a mass located the posterior part of the arytenoid cartilage on the hypopharynx. Because of the risk of hemorrhage during instrumental mobilization of the tumor, we gently pushed the mass with a long Kelly, which made it possible to extract the mass out of the esophagotomy opening. After that, the mucosal resection and esophageal repair was completed easily.

Although many authors have recently reported the successful treatment of esophageal hemangioma with endoscopic mucosal resection or KTP/YAG laser therapy, surgical resection through esophagostomy is safe and technically simple, especially when the tumor is large or located in the cervical esophagus.

REFERENCES

1. Plachta A. *Benign tumors of the esophagus. Review of literature and report of 99 cases.* Am J Gastroenterol 1962;38: 639-52.
2. Rasalkar DD, Chiu PW, Teoh AY, Chu WC. *Oesophageal haemangioma: imaging characteristics of this rare condition.* Hong Kong Med J 2010;16:230-1.
3. Hanel K, Talley NA, Hunt DR. *Hemangioma of the esophagus: an unusual cause of upper gastrointestinal bleeding.* Dig Dis Sci 1981;26:257-63.
4. Lee HJ, Kim YT, Sung SW, Kim JH. *A case of long segment myomectomy for the treatment of esophageal hemangioma.* Korean J Thorac Cardiovasc Surg 2003;36:206-10.
5. Mok HK, Shin HS, Hong KW. *Cavernous hemangioma of the esophagus: one case report.* Korean J Thorac Cardiovasc Surg 1999;32:851-4.
6. Rajoriya N, D'costa H, Gupta P, Ellis AJ. *An unusual cause of dyspepsia: oesophageal cavernous haemangioma.* QJM 2010;103:791-3.
7. Nagata-Narumiya T, Nagai Y, Kashiwagi H, Hama M, Takifuji K, Tanimura H. *Endoscopic sclerotherapy for esophageal hemangioma.* Gastrointest Endosc 2000;52:285-7.
8. Shigemitsu K, Naomoto Y, Yamatsuji T, et al. *Esophageal hemangioma successfully treated by fulguration using potassium titanyl phosphate/yttrium aluminum garnet (KTP/YAG) laser: a case report.* Dis Esophagus 2000;13:161-4.