

Original Article

Estrogen receptor α expression in different stages of salivary gland mucoepidermoid carcinoma

Forooz Keshani¹, Hossein Yousefi², Neda Kargahi¹

¹Department of Oral and Maxillofacial Pathology, Dental Research Center, School of Dentistry, Dental Research Institute, Isfahan University of Medical Sciences, ²Department of Oral and Maxillofacial Pathology, Dental Research Institute, School of Dentistry, Isfahan University of Medical Sciences, Isfahan, Iran

ABSTRACT

Background: Since salivary and breast glands are both considered as a tubulo-acinar, exocrine glands, and they have a common neoplastic morphology, it is not surprising if they share a similar molecular mechanism responsible for their neoplastic transformation. From the first description of estrogen receptor- α (ER- α) in salivary tumors, tremendous attentions have been attracted to this receptor for evaluating its impact in mucoepidermoid carcinoma (MEC).

Materials and Methods: In this descriptive analytics, 28 samples of MEC (14 high grade and 14 low grade) were collected from the Oral and Maxillofacial Pathology Department of Isfahan Dental School and Isfahan Alzahra Hospital. All of these samples were stained with immunohistochemical technique with ER- α marker. The expression of the receptor was evaluated by two oral and maxillofacial pathologists. Statistical data were saved at SPSS and had been analyzed by Mann-Whitney U- and independent t-tests (significance level: $P \leq 0.05$).

Results: The high-grade MEC was more common in patients with a higher average age (55.9); on the other hand, low-grade MEC was mostly observed in those with a mean age of 39.2 years. Moreover, high-grade MEC was more prevalent in men rather than in women. The staining intensity distribution average in high-grade MEC and low-grade MEC was 2.4 and 0.8, respectively ($P = 0.48$).

Conclusion: The expression of ER- α in high-grade MEC was significantly more than low-grade MEC, indicating that targeting this receptor alongside surgery could bring more advantages for patients.

Key Words: Estrogen receptor- α , mucoepidermoid carcinoma, salivary gland neoplasm

Received: 12-Jan-2021
Revised: 28-Apr-2021
Accepted: 01-Jul-2021
Published: 28-Feb-2022

Address for correspondence:

Dr. Neda Kargahi,
Department of Oral and
Maxillofacial Pathology,
Dental Research Center,
School of Dentistry, Dental
Research Institute, Isfahan
University of Medical
Sciences, Isfahan, Iran.
E-mail: kargahi@dent.mui.
ac.ir

INTRODUCTION

The tumor of salivary glands (SGs) is one of the most common head-and-neck neoplasms worldwide. Although in general, 0.4% of all tumors are SG tumors, those consist of 5% of head-and-neck neoplasms.^[1,2] The most common site is the parotid gland and the most common benign tumor of SGs is pleomorphic adenoma. Malignant tumors are

more frequent in minor SGs, the highest percentage has been documented in the palate.^[2,3] However, the pace of malignant transformation in SG's tumor is significantly low, its metastasis to distant organs has still been considered as a challenge for the physicians. Given these and based on the poor response of patients to radiotherapy and chemotherapy,

This is an open access journal, and articles are distributed under the terms of the Creative Commons Attribution-NonCommercial-ShareAlike 4.0 License, which allows others to remix, tweak, and build upon the work non-commercially, as long as appropriate credit is given and the new creations are licensed under the identical terms.

For reprints contact: WKHLRPMedknow_reprints@wolterskluwer.com

How to cite this article: Keshani F, Yousefi H, Kargahi N. Estrogen receptor α expression in different stages of salivary gland mucoepidermoid carcinoma. Dent Res J 2022;19:16.

Access this article online	
	<p>Website: www.drj.ir www.drjjournal.net www.ncbi.nlm.nih.gov/pmc/journals/1480</p>

tremendous attentions have been recently devoted to the therapeutic approaches of this malignancy. Both salivary and the breast glands are considered as tubulo-acinar and exocrine glands; besides, they share a common neoplastic morphology. As a result, it is not surprising that there would be a resemblance between their pathogenesis. According to the importance of the estrogen receptor (ER) in the pathogenesis of mammary gland neoplasms, which opened up an opportunity for hormone therapy to be used in breast cancer therapeutic protocols, it is reasonable to assume that probably the expression of this receptor could be exploited as a diagnostic marker for SG tumors.^[4]

Mucoepidermoid carcinoma (MEC) is a malignant SG neoplasm with the source of epithelial cells, epidermoid cells, intermediate cells, and clear cells.^[5,6] According to histopathology, the amount of cystic spaces, cell differentiation, proportion of mucus cells, tumor progression pattern, invasion type, and unusual cytology data, this neoplasm is divided into three grades of low, intermediate, and high^[5-7] [Table 1]. This tumor with the size of <4 cm is commonly located at the corticated border and usually possesses a capsule; however, in some cases, it could invade to the lower tissues and be fixed in that area.^[8] The high-grade tumors show low cell differentiation and primarily consist of squamous cells and intermediate cells.^[8] On the contrary, the low-grade tumors represent higher cell differentiation and are primarily consisted of mucus cells and squamous cells. Noteworthy, histological features of intermediate-grade tumors are somewhere between high-grade and low-grade tumors.^[8] The diagnosis of MEC is based on finding three components of tumor that are mixed together: mucus cells, intermediate cells or clear cells, and squamous cells.^[9] Three

criteria of tumor grade, the location of the neoplastic cells, and the clinical symptoms all together determine the treatment strategy of this malignancy. It is worthy to mention that the main purpose of treatment is to be sure of the patient's safety by leaving a safe margin.^[8] Although surgery has brought remarkable advantages for the treatment of patients with MEC, the response rate of patients with the advanced stages of this malignancy still remains poor.^[10]

Considering the fact that mammary and SGs are both considered as tubule-acinar and exocrine glands and also based on their similarities, it is postulated that probably MEC shares a common neoplastic biology with breast cancer.^[4] This hypothesis evolved a possibility that probably ER could take part in the pathogenesis of this carcinoma, shedding a new light on the therapeutic approaches to this malignancy.^[11] The participation of ER in the pathogenesis of MEC has been examined in different cancer cell types; however, in many cases, there are conflicting results. In a study conducted by Kolude *et al.*, it has been reported that the expression level of ER- α (ER- α) is significantly higher in malignant SG neoplasms as compared to their benign counterparts. Moreover, their results revealed that there is an association between the grade of the tumor and expression of this receptor, as the high-grade tumors expressed the higher amount of ER- α than the low-grade tumors.^[11] In another study, Luo *et al.* indicated the promising effect of hormone therapy against ER- α in the SG tumors.^[10] On the contrary, Pires *et al.* failed to find any obvious relationship between the expression of ER- α and the incidence of MEC tumors and adenoid cystic carcinomas.^[12] In addition, Nasser *et al.* suggested that while ER- α is expressed in a few cases of malignant SG tumors, there is no evidence of the expression of this receptor in benign neoplasms.^[13] Furthermore, Tabatabaei *et al.* evaluated the expression of this receptor in MEC and AdCC claiming that probably this receptor does have a crucial role in tumorigenesis of these neoplasms.^[14] Moreover, Bashir *et al.* designed a study to investigate the percentage of expression of ER- α in SGTs (Salivary Gland Tumors) in their region, to find out if it can help clinicians to alter their treatment method regarding breast tumors. They concluded that ER- α can be considered as an appropriate target for anti-hormonal therapy in the subset of SGTs expressing them in variable proportions.^[2]

In line with these controversies, there was a particular interest to evaluate the contributing role of ER- α in MEC.

Table 1: Salivary mucoepidermoid carcinoma histological grading (Aclair 2009)^[4]

Parameter	Point value
Intracystic component <20%	2
Neural invasion present	2
Necrosis present	3
Four or more mitosis per 10 high-power field	3
Anaplasia present	4
Grade	Total point score
Low	0-4
Intermediate	5-6
High	7-14

MATERIALS AND METHODS

This laboratory cross-sectional study has been done by paraffin blocks of the Pathology Department of Isfahan University of Medical Sciences and Isfahan Alzahra Hospital in 2018. Using random sampling method, 28 cases of salivary MEC (14 low grade and 14 high grade) were collected. Those samples with damaged paraffin blocks or those with insufficient tissue in paraffin blocks slide were excluded from the study and the remained samples were examined under a light microscope (Olympus Bx41 TF, Tokyo, Japan) after staining with hematoxylin and eosin. The stage of carcinoma was confirmed by two oral and maxillofacial pathologists at the same time. After confirming the diagnosis, according to Aclair 2009 classification, the samples were classified into two groups of low grade and high grade.^[6] Then, immunohistochemical reactions against ER (Dako cytation, USA) were performed on histological sections. Phosphate-buffered saline was used instead of the primary antibody as a negative control, and breast cancer was used as positive control.

The specimens magnified $\times 400$ were examined using a light microscope by two oral and maxillofacial pathologists simultaneously and the percentage of stained nucleus was determined as labeling index (LI) using the following formula: number of positive nuclei/1000 tumor cells nuclei in 10 random field $\times 100$. Then, the samples were classified into four groups as (+1) $<5\%$ negative, (+2) $5\%–20\%$ poor, (+3) $21\%–50\%$ moderate, and (+4) $>50\%$ strong (11 and 2). The intensity of the stained nuclei also evaluated based on the following criteria: (+1) the possibility of stained cell recognition with $\times 400$ magnification, (+2) the possibility of stained cell recognition with $\times 100$ magnification, and (+3) the possibility of stained cell recognition with $\times 40$ magnification [Figures 1-4].^[12] At the final step, the staining-intensity distribution (SID) which is the scale of proportion of marked cells in each field multiply scale of marking intensity in the same field was calculated.^[15]

Finally, the data were analyzed using SPSS version 20 (IBM, Chicago, USA) and Mann–Whitney U- and independent *t*-tests (significance level: $P \leq 0.05$).

RESULTS

This study was conducted to evaluate the expression of ER- α in SG MEC. The samples included 14 patients who had low-grade SG MEC and 14 patients who had high-grade SG mucoepidermoid. Although the prevalence of the high-grade MEC was higher at the age of 55.9 ± 21.3 years, the incidence of the low-grade carcinoma was more common in patients with the age of 39.2 ± 11.6 years. The results of independent *t*-test showed that the mean ages of patients with high-grade MEC were significantly higher than low-grade MEC ($P = 0.02$). Another parameter that was evaluated in the present study was to find out whether there is an association between the gender and the stage of the MEC. We found that the high-grade tumor was more common in male (78.6%), whereas the low-grade MEC was more observed in female patients with an incident rate of 64.3% [Table 2]. The significance of this correlation was confirmed by the Chi-square test ($P = 0.02$). Moreover, the results obtained from Mann–Whitney U-test indicated that the staining intensity of estrogen at high-grade salivary MEC was significantly more than low-grade carcinoma ($P = 0.048$) [Table 3]. The results of Mann–Whitney U-test summarized in Table 4 indicated that the “LI” in high-grade salivary MECs was significantly higher than low-grade carcinomas ($P = 0.043$).

Evaluating the expression level ER in high- and low-grade carcinoma showed that the average of “SID” at high-grade salivary MEC group was 2.4 with standard deviation of 1 and at low-grade salivary MEC group was 0.8 with standard deviation of 0.5. The independent *t*-test further confirmed that this difference is statistically significant ($P = 0.048$). As depicted in the mean “SID” in male patients was 2.5 with standard deviation of 0.9, while this number was

Table 2: The frequency distribution of “sex” in two groups of low-grade and high-grade salivary mucoepidermoid carcinomas

Sex	High-grade mucoepidermoid carcinoma, <i>n</i> (%)	Low-grade mucoepidermoid carcinoma, <i>n</i> (%)	<i>P</i>
Male	11 (78.6)	5 (35.7)	0.02
Female	3 (21.4)	9 (64.3)	

Table 3: Staining intensity in two groups of low-grade and high-grade salivary mucoepidermoid carcinoma

Staining intensity distribution	High-grade salivary mucoepidermoid carcinoma, n (%)	Low-grade salivary mucoepidermoid carcinoma, n (%)	P
No stained	7 (50)	11 (78.6)	0.048
Mild	4 (28.6)	1 (7.1)	
Moderate	1 (7.1)	2 (14.3)	
Severe	2 (14.3)	0	

Table 4: The frequency distribution of “labeling index” in two groups of low-grade and high-grade salivary mucoepidermoid carcinomas

Labeling index score	High-grade salivary mucoepidermoid carcinoma, n (%)	Low-grade salivary mucoepidermoid carcinoma, n (%)	P
Negative	8 (57.1)	12 (85.8)	0.043
Mild	3 (21.5)	1 (7.1)	
Moderate	1 (7.1)	1 (7.1)	
Strong	2 (14.3)	0	

0.4 with standard deviation of 0.3 in female patients. This finding was also substantiated with independent *t*-test ($P = 0.035$).

DISCUSSION

The frequency of malignant SG tumors is <5% of head-and-neck neoplasms, which among them, MEC is the most prevalent critically participating in oral pathology.^[14] For the first time, the clinical importance of ER- α in this tumor was demonstrated when the agent against this receptor was used as a treatment choice of SG.^[14] Due to the differential evaluation methods and classifications of stained cell as negative or positive, the results of the previous studies, regarding the role of ER- α in the pathogenesis of salivary MEC, were contradicted. As a result, there was a particular interest to evaluate the participation of this receptor in salivary MEC in 14 patients with low-grade MEC and 14 patients with high-grade MEC. We found that the mean “SID” in high-grade MEC was significantly greater than the low-grade samples. This finding was in agreement with the results of Kolude *et al.* and Luo *et al.*, who deduced that there is a correlation between the amount of ER- α expression level and the stage of the malignancy in the patients.^[10,11] In contrast, there are other studies that indicate ER- α does not express in the SG neoplasms.^[1,12-17] One of the reasons attributed to this controversy may be due to the different involved factors, such as sex, age, and tumor histology. Utilization of the different techniques of fixing the samples, restoring antigens during

immunohistochemistry (IHC) staining, and different pathological interpretations of IHC staining may be the other contributing factors for this controversy. Presumably, the last one may be due to the lack of same strong evaluating indexes; for example, in a study conducted by Tarakji *et al.*, the study classification system assumed that if the sample’s stained cells were <75%, it would be considered as a negative one.^[1] The distinguished characteristic of the present study to the previous ones is the presence of salivary MEC with very low-differentiated cells, which are representative of the negative ER- α staining. In addition, in the present study, we have chosen a single type of salivary MEC at two groups of low grade and high grade to compare their results. However, other studies had compared a small number of different benign and malignant tumors.^[11,12,14]

Considering the results of our study, it seems that there is a correlation between the expression of ER- α and the stage of the disease, proposing that some drugs, such as tamoxifen, which could block the expression of this receptor could cause some advantages for patients with SG tumors.^[11] Furthermore, this study showed that the mean age of low-grade salivary MEC was significantly lower than the high-grade samples. Besides, the incidence of the high-grade tumors was more common in men rather than women. In consistent, it has been reported that both the survival rate and prognosis of tumors in young and female patients were better.^[18,19] On the other hand, another study performed by Kolude *et al.* indicated that there is not any obvious relation between sex and the ER- α

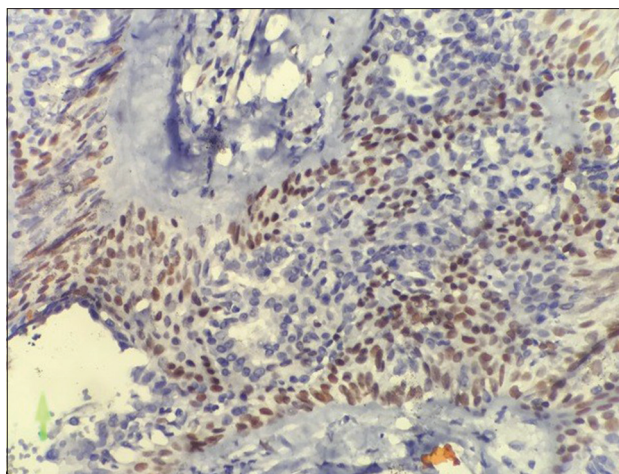


Figure 1: Staining with severe intensity of estrogen receptor in high grade salivary mucoepidermoid carcinoma (400x)

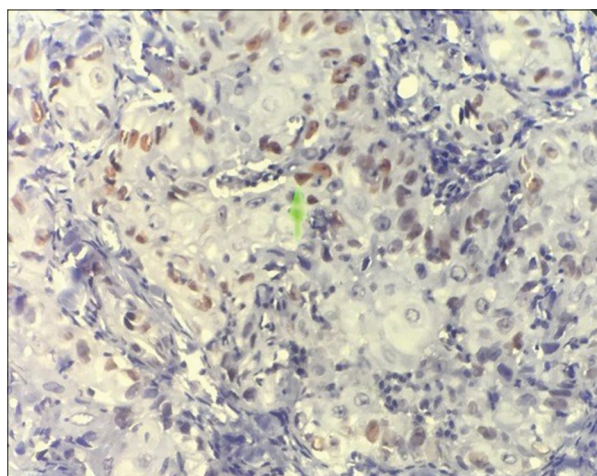


Figure 2: Staining with moderate intensity of estrogen receptor in high grade salivary mucoepidermoid carcinoma (400x)

expression in the salivary MEC.^[1] However, we have shown that the expression of this receptor was significantly higher in men, which could be actually an explanation for the higher prevalence of high-grade salivary MEC in men rather than in women.

The results of the present study suggested that further experiments on other SGs tumors should be done to widen our perspective about not only the clinical features of tumors but also a promising treatment strategy for them.

CONCLUSION

Based on the aforementioned results, we propose that probably ER- α may play a key role in the development of MEC, shedding light on the application of the

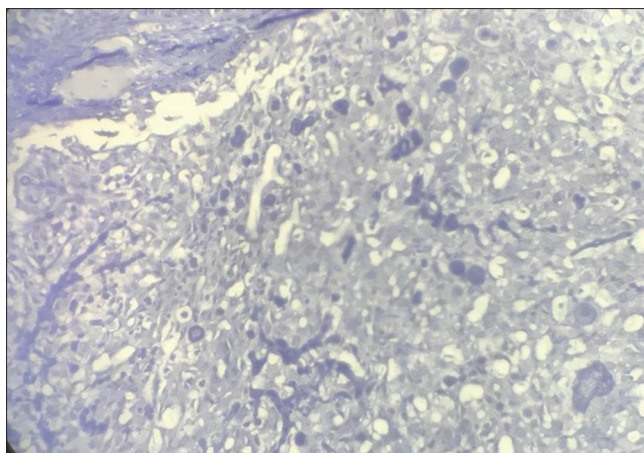


Figure 3: No staining of estrogen receptor in high grade salivary mucoepidermoid carcinoma (400x)

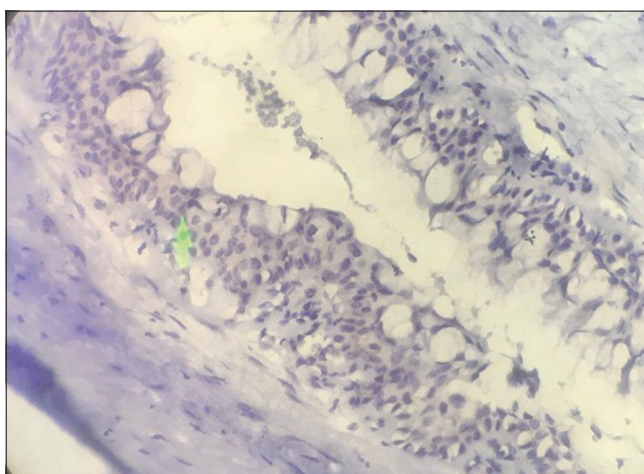


Figure 4: No staining of estrogen receptor in low grade salivary mucoepidermoid carcinoma (400x)

hormone therapy against ER- α alongside surgery in the therapeutic approaches of this carcinoma.

Acknowledgment

This study has been supported by a grant from Isfahan University of Medical Sciences, Isfahan, Iran NO: (397231).

Financial support and sponsorship

Nil.

Conflicts of interest

The authors of this manuscript declare that they have no conflicts of interest, real or perceived, financial or nonfinancial in this article.

REFERENCES

1. Tarakji B, Nassani MZ, Sloan PH. Immunohistochemical expression of estrogen and progesterone receptors in carcinoma ex pleomorphic adenoma-undifferentiated and adenocarcinoma

- types. *J Oral Med Pathol* 2010;15:e432-6.
2. Bashir N, Iqbal F, Ahmed S, Motahir ST, Mohammad S, Nausheen T. Estrogen receptor α signaling in salivary gland tumors: Lesson learned from breast carcinoma. *Int J Pathol* 2020;18:74-8.
 3. Malik SM, Niazi Z, Alikhan M, Hashmi SN. Cyclin D. Protein expression in various grade of salivary mucoepidermoid carcinoma. *J Pak Armed Forces Med* 2019;69:920-5.
 4. Golusiński W, Wegner A, Trzeciak P, Golusiński P, Sówka M, Kopczyński A, *et al.* The expression assessment of the estrogen, progesterone and HER2 receptors in selected malignant tumors of the salivary glands. *Otolaryngol Pol* 2013;67:245-51.
 5. Luna MA. Salivary mucoepidermoid carcinoma: Revisited. *Adv Anat Pathol* 2006;13:293-307.
 6. Neville B, Damm D, Allen C, Bouquot J. *Oral and Maxillofacial Pathology*. 3rd ed. St Louis: Mosby; 2016. p. 456.
 7. Ahmed O, Al-Azzawi L. MTA1 expression in salivary mucoepidermoid carcinoma: With special emphasis on grading systems. *J Int Dent Med Res* 2019;12:1253-7.
 8. Available form: <http://oralcancerfoundation.org/facts/rare/mucoepidermoid-carcinoma/>. [Last accessed on 2018 Sep 03].
 9. Bai S, Clubwala R, Adler E, Sarta C, Schiff B, Smith RV, *et al.* Salivary mucoepidermoid carcinoma: A multi-institutional review of 76 patients. *Head Neck Pathol* 2013;7:105-12.
 10. Luo SD, Su CY, Chuang HC, Huang CC, Chen CM, Chien CY. Estrogen receptor overexpression in malignant minor salivary gland tumors of the sinonasal tract. *Otolaryngol Head Neck Surg* 2009;141:108-13.
 11. Kolude B, Adisa A, Adeyemi B, Lawal A. Immunohistochemical expression of estrogen receptor- α and progesterone receptor in salivary gland tumours. *J TOC* 2013;42:716-9.
 12. Pires FR, da Cruz Perez DE, de Almeida OP, Kowalski LP. Estrogen receptor expression in salivary gland mucoepidermoid carcinoma and adenoid cystic carcinoma. *Pathol Oncol Res* 2004;10:166-8.
 13. Nasser SM, Faquin WC, Dayal Y. Expression of androgen, estrogen, and progesterone receptors in salivary gland tumors. Frequent expression of androgen receptor in a subset of malignant salivary gland tumors. *Am J Clin Pathol* 2003;119:801-6.
 14. Tabatabaei H, Jafari N, Akhavan M, Tavakoli A. Immunohistochemical study of estrogen receptor expression in Adenoid cystic carcinoma and mucoepidermoid carcinoma of the salivary gland. *J Dent Res* 2016;8:e26715.
 15. Razavi SM, Hasheminia D, Mehdizade M, Movahedian B, Keshani F. The relation of pricoronal third molar follicle dimension and bcl-2/ki-67 expression. *J Dent Res (Isfahan)* 2012;9:S26-31.
 16. Dori S, Trougouboff P, David R, Buchner A. Immunohistochemical evaluation of estrogen and progesterone receptors in adenoid cystic carcinoma of salivary gland origin. *J Oral Oncol* 2000;36:450-3.
 17. Shick PC, Riordan GP, Foss RD. Estrogen and progesterone receptors in salivary gland adenoid cystic carcinoma. *J Oral Surg, Oral Med Oral Pathol Oral Radiol Endod* 1995;80:440-4.
 18. Deyhimi P. *Salivary Glands Pathology*. 1st ed. Isfahan University of Medical Science: Pajooh R; 2014:603-606
 19. Rosai J. *Rosai and Ackerman's Surgical Pathology*. 9th ed. St. Louis: Mosby; 2004. p. 873-916,247-277.