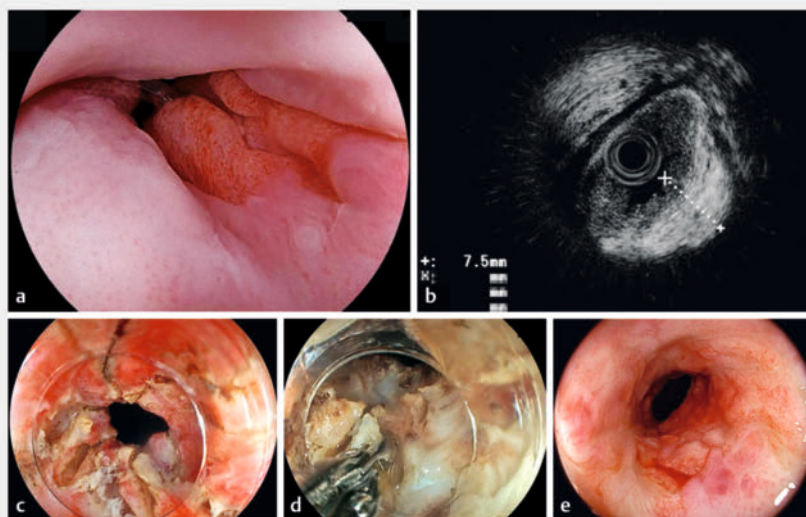


Novel endoscopic strictureplasty with longitudinal incisions and hot biopsy forceps removal for a rectal refractory stricture in Crohn's disease

OPEN
ACCESS

Numerous biologics have advanced Crohn's disease (CD) management, nevertheless, effectively treating intestinal strictures remains challenging. Endoscopic balloon dilation (EBD) is commonly used; dilatation has certain limitations and is not recommended for ulcerated strictures or those over 5 cm in length [1]. Moreover, even when EBD is performed, the majority of CD strictures tend to recur due to the healing process after dilation, necessitating additional dilatation [2,3,4]. Considering this perpetual need, we hypothesized that a substantial portion of CD stricture tissue consists of scar and could be physically excised [5]. Consequently, we devised an endoscopic strictureplasty involving multiple longitudinal incisions after ultrasonic evaluation and utilizing hot-biopsy forceps to remove rectal CD strictures.

A 29-year-old woman presented with rectal stricture and rectovaginal fistula, both attributed to a CD history of more than 15 years. Steroids and biologics were ineffective and the patient declined colostomy. Although the causal relationship between the stricture and the fistula was apparent, repeated EBD proved ineffective because the dilated lumen quickly reverted. Endoscopic ultrasound revealed that the stricture was predominantly composed of thickened mucosa and submucosa. Thus, after multidisciplinary review, we decided to remove the scar tissue, facilitating continuous luminal enlargement. The tough scar tissue precluded grasping with forceps, necessitating longitudinal incisions along the thickened wall, identified with ultrasound, utilizing a precutting knife (► Fig. 1, ► Video 1). The ridge formed by these incisions was engaged with hot-biopsy forceps and gradually removed. Although a 7.9-mm-diameter gastroscop could not pass the stricture before the procedure, an 11.7-mm colo-



► **Fig. 1** Sequential images of endoscopic strictureplasty employing longitudinal incisions and the utilization of hot biopsy forceps. **a** It is apparent that a rectal refractory stricture, characterized by its narrow aperture, precludes passage of a 7.9-mm-diameter gastroscop (EG-840TP, Fujifilm). **b** A 20 MHz miniature probe (UM-3R, Olympus, Tokyo, Japan) revealed that the stricture was thickened tissue in both the mucosa and submucosa. **c** Longitudinal incisions using a reusable precutting knife (KD-10Q-1, Olympus) on the tissue, which was seen as thickened on ultrasound. **d** The ridge formed by the incisions was grasped with hot biopsy forceps (Radial Jaw 4 Hot Biopsy Forceps, Boston Scientific Corp., Marlborough, Massachusetts, United States) and removed bit by bit until the inner circular muscularis propria could be visualized; additional longitudinal incisions were made as necessary. **e** It was possible to pass the gastroscop with a 10mm-outer-diameter cap (DH-083ST, Fujifilm) through the stricture 2 months after the procedure.

noscope could pass through. Post-procedure betamethasone suppositories 1 mg/day were administered to the patient for 6 weeks to prevent early re-narrowing. The patient remained free from obstructive symptoms, and 2 months later, a gastroscop with a 10-mm-outer-diameter cap could traverse the stricture. Another strictureplasty was performed proximally to ensure adequate lumen passage. The patient reported no obstructive symptoms 5 months after the first procedure.

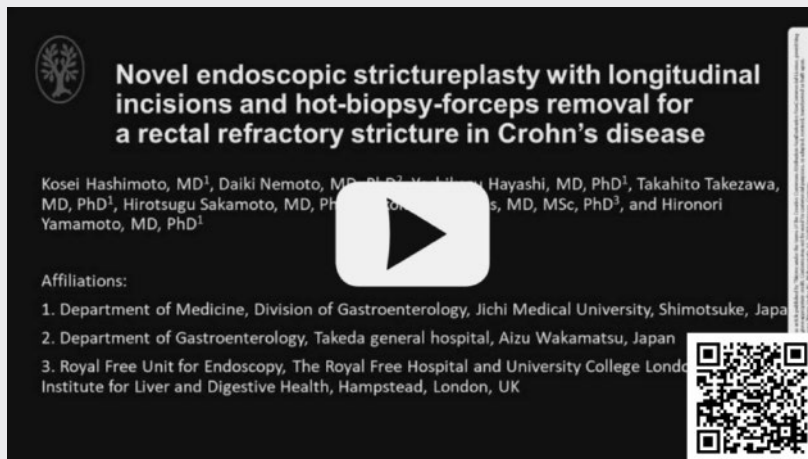This case illustrates that longitudinal incisions with a knife and hot biopsy forceps can successfully treat a refractory CD rectal stricture. Our preliminary ex-

perience shows that this novel technique is safe and effective for CD strictures and warrants further study.

Conflict of Interest

H.Y. has consultant relationships with Fujifilm Co. Ltd. and received honoraria, grants, and royalties from the company. The other authors declare no conflicts of interest.

VIDEO



► **Video 1** Novel endoscopic strictureplasty with longitudinal incisions and hot biopsy forceps removal for a rectal refractory stricture in Crohn's disease.

Bibliography

Endosc Int Open 2024; 12: E97–E98

DOI 10.1055/a-2223-0754

ISSN 2364-3722

© 2024. The Author(s).

This is an open access article published by Thieme under the terms of the Creative Commons Attribution-NonDerivative-NonCommercial License, permitting copying and reproduction so long as the original work is given appropriate credit. Contents may not be used for commercial purposes, or adapted, remixed, transformed or built upon. (<https://creativecommons.org/licenses/by-nc-nd/4.0/>)

Georg Thieme Verlag KG, Rüdigerstraße 14, 70469 Stuttgart, Germany



The authors

Kosei Hashimoto¹, Daiki Nemoto², Yoshikazu Hayashi¹, Takahito Takezawa¹, Hirotsugu Sakamoto¹, Nikolaos Lazaridis³, Hironori Yamamoto¹

- 1 Department of Medicine, Division of Gastroenterology, Jichi Medical University, Shimotsuke-shi, Japan
- 2 Gastroenterology, Takeda General Hospital, Aizuwakamatsu, Japan
- 3 Endoscopy, Royal Free Hospital, London, United Kingdom of Great Britain and Northern Ireland

Corresponding author

Dr. Yoshikazu Hayashi

Jichi Medical University, Department of Medicine, Division of Gastroenterology, Shimotsuke-shi, Japan
hayashi@jichi.ac.jp

References

- [1] Yamamoto H, Yano T, Araki A et al. Guidelines for endoscopic balloon dilation in treating Crohn's disease-associated small intestinal strictures (supplement to the Clinical Practice Guidelines for Enteroscopy). *Dig Endosc* 2022; 34: 1–2 doi:10.1111/den.1442936073310
- [2] Takeda T, Kishi M, Takatsu N et al. Long-term outcomes of endoscopic balloon dilation for intestinal strictures in patients with Crohn's disease during maintenance treatment with anti-tumor necrosis factor alpha antibodies. *Dig Endosc* 2022; 34: 517–525
- [3] Lan N, Stocchi L, Ashburn JH et al. Outcomes of endoscopic balloon dilation vs surgical resection for primary ileocolic strictures in patients with Crohn's disease. *Clin Gastroenterol Hepatol* 2018; 16: 1260–1267
- [4] Shen B, Kochhar G, Navaneethan U et al. Practical guidelines on endoscopic treatment for Crohn's disease strictures: a consensus statement from the Global Interventional Inflammatory Bowel Disease Group. *Lancet Gastroenterol Hepatol* 2020; 5: 393–405
- [5] Moroi R, Shiga H, Kuroha M et al. Endoscopic radial incision and cutting for Crohn's Disease-associated intestinal stricture: a pilot study. *Endosc Int Open* 2020; 8: E81–E86 doi:10.1055/a-1027-692131921989