

An ocular myasthenia gravis attack after oral pyrantel pamoate

An unusual case report

Chaolan Shen, MD*, Min Li, MD, Xin Zhao, MD, Lin Cui, MD

Abstract

Rationale: Myasthenia gravis (MG) is an autoimmune disease of the neuromuscular junction that can be triggered by anticholinergic agents.

Patient concerns: We present a 4-year-old female patient who was admitted to the outpatient clinic. She complained of drooped eyelids, which first appeared 2 days after taking a 200 mg dose of pyrantel pamoate. Past medical history is negative.

Diagnoses and treatment: She was hospitalized with a diagnosis of ocular type MG, and pyridostigmine (40 mg/day) treatment was started.

Outcomes: The patient recovered, and subsequently, the treatment dose was tapered.

Conclusion: Pyrantel is an anthelmintic that acts as an agonist of nicotinic acetylcholine receptors (AChRs) of nematodes and exerts its therapeutic effects by depolarizing their muscle membranes. Consequently, there may be an association between pyrantel pamoate and MG.

Abbreviations: BCVA = best corrected visual acuity, MG = myasthenia gravis, nAChR = nicotinic acetylcholine receptors.

Keywords: adverse effect, case report, myasthenia gravis, pyrantel pamoate

1. Introduction

Ocular myasthenia gravis (OMG) is a disease characterized by fluctuating weakness of the extraocular muscles resulting from an autoimmune response to acetylcholine receptors (AChR) in the postsynaptic neuromuscular region, generally due to parasympathetic nervous system effects.^[1] MG can be triggered by anticholinergic agents.^[2] In addition to the trigger by anticholinergic agents, it was found that pyrantel pamoate used during anthelmintic treatment led to MG.^[3] Pyrantel exerts its anthelmintic action by blocking the worm's neuromuscular transmission, producing a depolarizing-type neuromuscular

block. We present a female child with an MG attack following oral pyrantel pamoate treatment. Informed written consent was obtained from the patient for publication of this case report and accompanying images.

2. Case report

A 4-year-old female with itching of the anus had first taken a single 200 mg dose of pyrantel pamoate orally without having attended the clinic (Fig. 1). After using the medication, the kindergarten found that the little girl's right eyelid had developed ptosis. During the next few days, she experienced intermittent diplopia, which resolved after rest and worsened in the afternoon (Fig. 2 A). According to the patient's mother, this was the first time the patient had presented with these symptoms. Past medical history is negative. On ocular examination, best corrected visual acuity (BCVA) was 0.8 in both eyes, and intraocular pressure and pupillary light reflex were normal. In the eyes straight ahead position, orbicularis muscle tone was decreased in the right eye, and the right eyelid covered 3 mm of the upper cornea. The right eyelid worsened after continuous blinking. In a blood analysis, markers of thyroid-associated orbitopathy (T3, free T4, thyroid-stimulating hormone, anti-thyroid peroxidase antibody, thyroid-stimulating hormone receptor antibody, thyroid-stimulating immunoglobulin) and the AChR antibody were tested; all were negative. An electroencephalogram showed a normal response. Computed tomography of the chest was unremarkable for thymoma. Magnetic resonance imaging of the brain and orbits showed no abnormal findings. The neostigmine test showed a positive response wherein administration of 2 mg of edrophonium chloride reversed the ophthalmoparesis. Finally, the girl was diagnosed with ocular myasthenia gravis. She was

Editor: N/A.

In accordance with the Declaration of Helsinki, written informed consent was obtained from the patient.

This work was supported in part by National Natural Science Foundation of China Grants 81760172.

The authors have no conflicts of interest to disclose.

Department of Ophthalmology, People's Hospital of Guangxi Zhuang Autonomous Region, Nanning, Guangxi, China.

* Correspondence: Chaolan Shen, Department of Ophthalmology, People's Hospital of Guangxi Zhuang Autonomous Region, 6 taoyuan road, Nanning, Guangxi 530021, China (e-mail: xiaolan8614@126.com).

Copyright © 2019 the Author(s). Published by Wolters Kluwer Health, Inc. This is an open access article distributed under the terms of the Creative Commons Attribution-Non Commercial License 4.0 (CCBY-NC), where it is permissible to download, share, remix, transform, and buildup the work provided it is properly cited. The work cannot be used commercially without permission from the journal.

Medicine (2019) 98:27(e16321)

Received: 20 December 2018 / Received in final form: 5 May 2019 / Accepted: 13 June 2019

<http://dx.doi.org/10.1097/MD.00000000000016321>

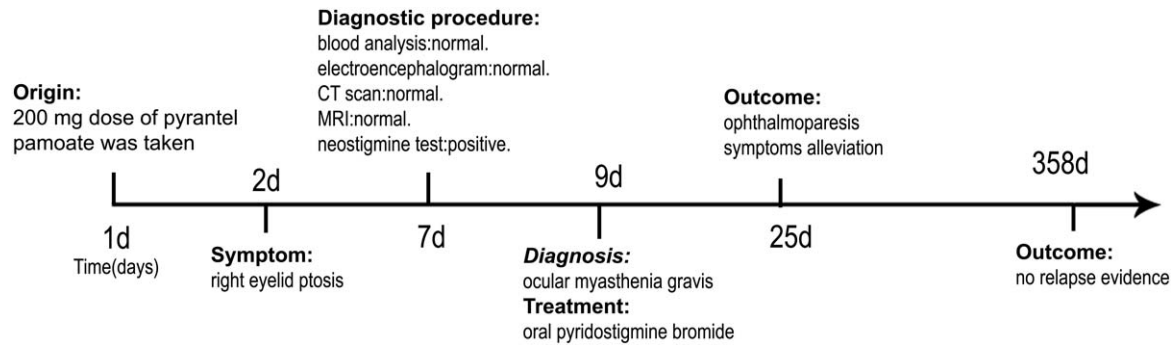


Figure 1. Diagnosis and treatment timeline.

discharged with a prescription for pyridostigmine bromide, 20 mg bid while awake. Two weeks later, her ophthalmoparesis symptoms were alleviated. Two months after treatment, the pyridostigmine dose was decreased to 10 mg bid without recurrent symptoms (Fig. 2 B). Consequently, we hypothesized that pyrantel pamoate has a probable association with MG.

3. Discussion

Myasthenia gravis is a complex disease caused by antibody-mediated damage to the neuromuscular junction, which is characterized by muscle weakness and fatigue. If the weakness is limited to the ocular muscles, it is designated ‘ocular myasthenia’. The average annual incidence of MG is 20 in 100,000.^[4] The epidemiological characteristics of MG in childhood are rarely reported since MG occurs more often in elderly persons. Only 10% to 15% of myasthenia patients are in the childhood age group. The rate of MG is 4.2% in children under 10 years of age.^[5] However, juvenile myasthenia gravis, a subtype of early-onset disease, has a high frequency in East Asia, in which up to 50% of all cases have onset before age 15 years, many of them with ocular symptoms only.^[6,7] In the present case, the patient had a rapid-onset eyelid droop as the first symptom of early-onset MG, which appeared just 1 day after pyrantel was taken orally.

Pyrantel exerts its anthelmintic action by blocking the worm’s neuromuscular transmission, producing a depolarizing-type neuromuscular block.^[8] Mebendazole, albendazole, and pyrantel pamoate are the most widely used agents to treat oxyuriasis.^[9] In particular, pyrantel pamoate is a deworming drug acting as a depolarizing neuromuscular blocking agent, thereby, causing sudden contraction, followed by paralysis, of the helminths. As a result, the worms lose their grip on the intestinal wall and pass out of the system by natural processes. Anthelmintics are commonly considered quite safe agents, and side effects such as gastrointestinal, neurologic, hematologic, or hepatic injury have been only rarely reported.^[10] In rats, a dosage of 50 mg/kg administration leads to paralysis and death,^[11] but toxic neuromuscular effects in humans have only been reported once in older male patients in 1989.^[3] In this case, 200 mg dose of pyrantel pamoate orally, for the child to have had it as an over the counter medication, is follow the dosage chart which printed on drug’s package.

A possible explanation for the sudden onset of myasthenia gravis after oral pyrantel is that it mainly affects the nicotinic acetylcholine receptors (nAChR). Pyrantel, which acts as an agonist of nicotinic receptors (AChRs) of nematodes, may exert its therapeutic effects by depolarizing nematodes’ muscle membranes. It is widely considered that this action is specific to helminths; no evidence shows that it can also affect human neuromuscular junctions. However, young children and immunocompromised people may be affected in some ways that are unclear.

Hence, we hypothesized that, in this patient, ingestion of pyrantel pamoate may trigger MG symptoms. Producing a depolarizing-type neuromuscular block,^[8] and hypothetically, the main reason for the attack is pyrantel. It should be considered that oral anthelmintic drugs may trigger and worsen MG and that they should be used with caution in MG patients. Although the overall frequency of MG attack in children is low, it is relatively high in Asia. This case suggested that pyrantel for the treatment of intestinal parasites in Asian children should be used with caution.

Author contributions

Methodology: Lin Cui.

Project administration: Min Li.

Supervision: Min Li, Xin Zhao.

Writing – original draft: Chaolan Shen.

Writing – review & editing: Chaolan Shen.

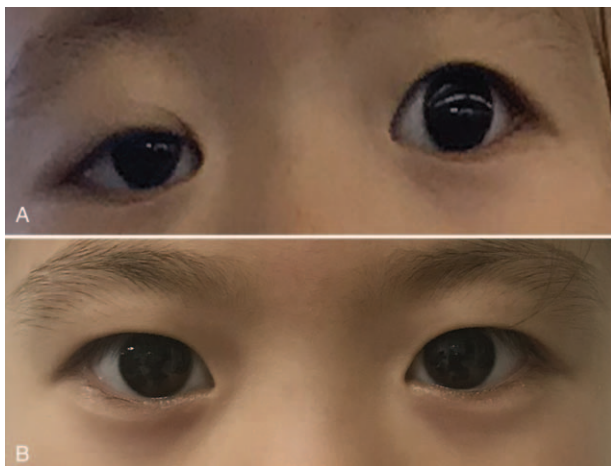


Figure 2. Female child with ptosis of the right eye before treatment (A) and 11 months after pyridostigmine bromide treatment (B).

References

- [1] Meriggioli MN, Sanders DB. Autoimmune myasthenia gravis: emerging clinical and biological heterogeneity. *Lancet Neurol* 2009;8:475–90.
- [2] Sanders DB, Wolfe GI, Narayanaswami P. Developing treatment guidelines for myasthenia gravis. *Ann N Y Acad Sci* 2018;1412:95–101.
- [3] Bescansa E, Nicolas M, Aguado C, et al. Myasthenia gravis aggravated by pyrantel pamoate. *J Neurol Neurosurg Psychiatry* 1991;54:563.
- [4] Phillips LH2nd. The epidemiology of myasthenia gravis. *Ann N Y Acad Sci* 2003;998:407–12.
- [5] VanderPluym J, Vajsar J, Jacob FD, et al. Clinical characteristics of pediatric myasthenia: a surveillance study. *Pediatrics* 2013;132:e939–44.
- [6] Pakzad Z, Aziz T, Oger J. Increasing incidence of myasthenia gravis among elderly in British Columbia, Canada. *Neurology* 2011;76:1526–8.
- [7] Peragallo JH. Pediatric Myasthenia Gravis. *Semin Pediatr Neurol* 2017;24:116–21.
- [8] Martin RJ, Verma S, Levandoski M, et al. Drug resistance and neurotransmitter receptors of nematodes: recent studies on the mode of action of levamisole. *Parasitology* 2005;131(Suppl):S71–84.
- [9] St Georgiev V. Pharmacotherapy of ascariasis. *Expert Opin Pharmacother* 2001;2:223–39.
- [10] Fasanmade AA, Akanni AO, Olaniyi AA, et al. Bioequivalence of pyrantel pamoate dosage forms in healthy human subjects. *Biopharm Drug Dispos* 1994;15:527–34.
- [11] Richardson DJ, Brink CD. Effectiveness of various anthelmintics in the treatment of moniliformiasis in experimentally infected Wistar rats. *Vector Borne Zoonotic Dis* 2011;11:1151–6.