

## IMAGES

## Successful salvage of failed post-sarcoma excision reconstruction and exposed alloplastic mesh with an anterolateral thigh flap

Juan Enrique Berner<sup>1,2</sup>, Luigi Troisi<sup>1,3</sup>, Paul Wilson<sup>1</sup>

<sup>1</sup>Department of Plastic and Reconstructive Surgery, Southmead Hospital, Bristol; <sup>2</sup>Kellogg College, University of Oxford, Oxford, UK; <sup>3</sup>Department of Plastic Surgery, Sapienza University of Rome, Rome, Italy

**Correspondence:** Luigi Troisi  
Department of Plastic and Reconstructive Surgery, Southmead Hospital,  
Southmead Road, Westbury-on-Trym, Bristol BS10 5NB, UK  
Tel: +44-117-950-5050, Fax: +44-117-950-5050  
E-mail: luigi.troisi@nhs.net

Received: 5 Jun 2018 • Revised: 12 Aug 2018 • Accepted: 12 Sep 2018  
pISSN: 2234-6163 • eISSN: 2234-6171  
<https://doi.org/10.5999/aps.2018.00766>  
Arch Plast Surg 2019;46:390-391



Copyright © 2019 The Korean Society of Plastic and Reconstructive Surgeons  
This is an Open Access article distributed under the terms of the Creative Commons  
Attribution Non-Commercial License (<http://creativecommons.org/licenses/by-nc/4.0/>)  
which permits unrestricted non-commercial use, distribution, and reproduction in any  
medium, provided the original work is properly cited.

The salvage of a patient with a failing chest reconstruction can be far more challenging than the primary reconstruction itself. Free flaps have an important role for this and it is usually standard practice to remove and replace any previously exposed alloplastic implants at the time that definitive

soft tissue cover is achieved. This is proposed to reduce the risk of future infection due to colonization of the implant [1]. Unfortunately, removal of alloplastic material is not always possible [2].

A 69-year-old patient was referred to our unit with a low-grade myofibroblastic sarcoma affecting his anterior chest wall (Fig. 1). Excision of the tumor was performed by a joint team of cardiothoracic and general surgeons. An acellular porcine dermal implant (Permacol; Medtronic Public Ltd., Minneapolis, MN, USA) was used to cover the pericardium. Over this implant an omental flap was placed and resurfaced with a split thickness skin graft.

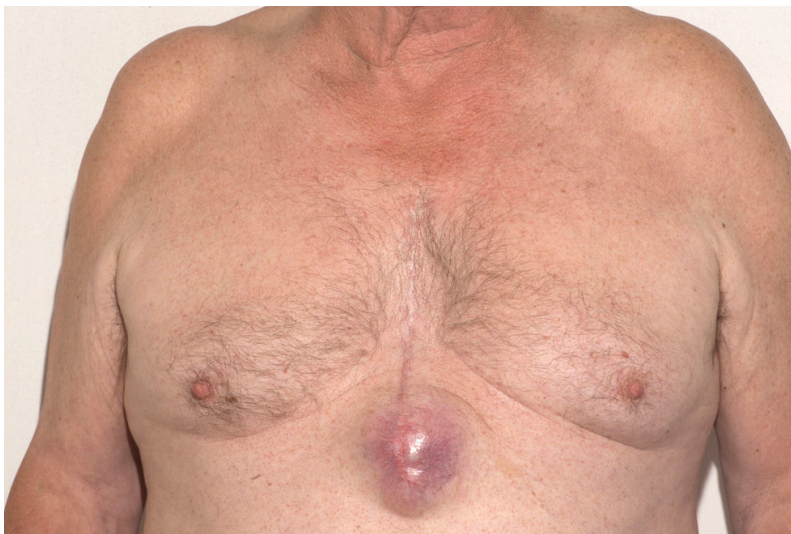Three days after this operation, spontaneous coughing caused evisceration of abdominal contents. The failed omental flap required immediate debridement and the acellular porcine dermal implant was removed. The resulting defect was covered with a topical negative pressure (TNP) dressing.

Four days later, the patient had to be taken back to theatre due to malfunctioning of the TNP system and further evisceration. On that same night, he eviscerated in to the wound for the third time. It was decided then to take him back to theatre for a revisional mesh repair of this abdominal and chest wall defect, using a polypropylene mesh (Prolene; Ethicon Inc., Somerville, NJ, USA), covered by TNP dressings.

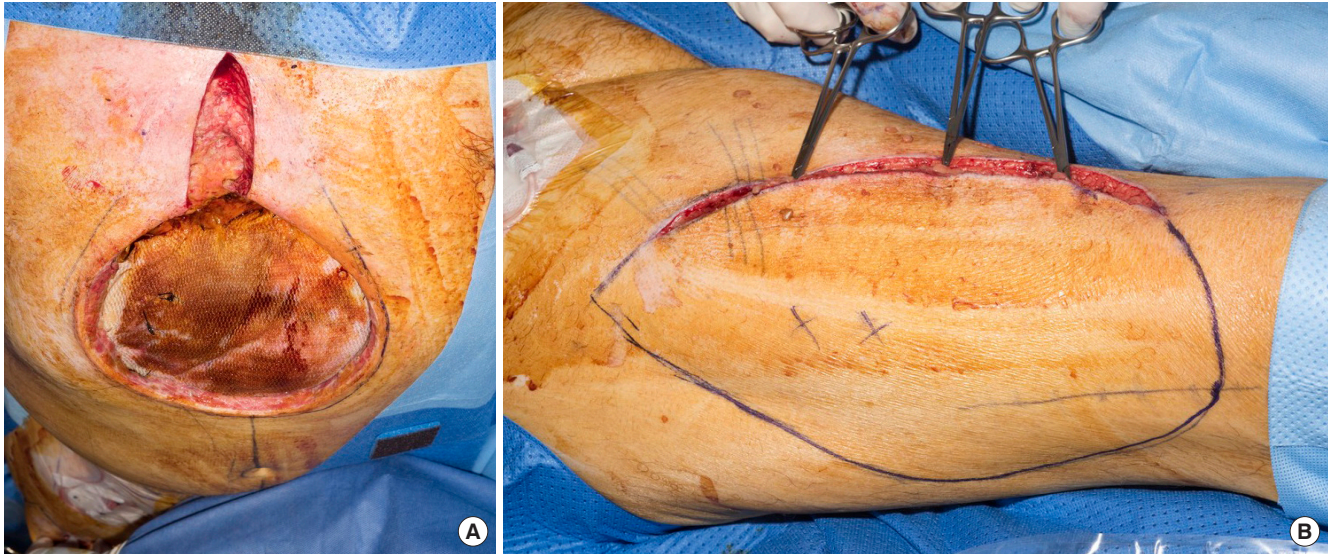
Re-exploration and definitive soft tissue cover were undertaken 1 week later by a plastic surgery team. At that point, the polypropylene mesh was found completely adhered to mediastinal contents, and exchange of this implant was considered unfeasible (Fig. 2). A two-perforator, 16 × 25 cm free anterolateral thigh flap was raised and anastomosed to the internal thoracic artery and vein to resurface the wound and cover the exposed polypropylene mesh.

Final histological diagnosis confirmed excision with adequate margins and no postoperative radiotherapy or chemotherapy was required [3]. At his 1-year follow-up appointment the patient did not show signs of recurrence or any signs of infection clinically and on magnetic resonance imaging scans (Fig. 3).

Even though it is ideal to exchange any exposed material by the time definitive cover is achieved, sometimes, due to the complexity of the case this is not possible. The previously exposed case intends to demonstrate the salvage of the situation with a free flap can be a feasible option.



**Fig. 1.** Preoperative photographs showing the extent of the soft tissue sarcoma in our patient's chest wall.



**Fig. 2.**

(A) Picture showing the state of the polypropylene mesh by the time soft tissue covering was intended, adhered to mediastinal contents. (B) The utilized anterolateral thigh flap being raised is also shown.

## Notes

### Conflicts of interest

No potential conflict of interest relevant to this article was reported.

### Ethical approval

The study was performed in accordance with the principles of the Declaration of Helsinki. Written informed consent was obtained.

### Patient consent

The patient provided written informed consent for the publication and the use of his images.

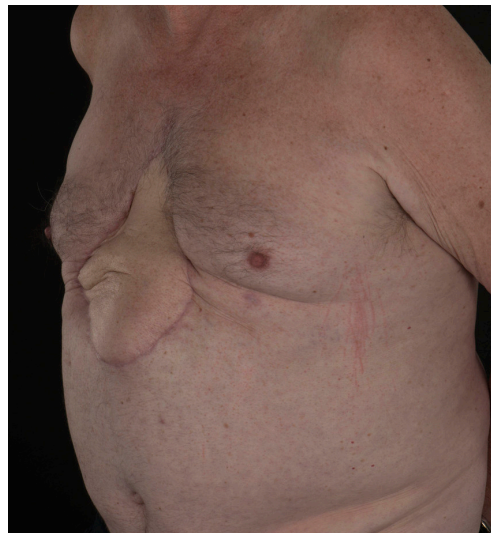### Author contribution

Conceptualisation: Troisi L, Wilson P. Data collection: Berner JE. Formal analysis: Berner JE. Methodology: Berner JE, Troisi L. Project administration: Wilson P. Writing original draft: Berner J. Writing, reviewing and editing: all authors.

### ORCID

Juan Enrique Berner <https://orcid.org/0000-0003-2178-5161>

Luigi Troisi <https://orcid.org/0000-0002-4754-3075>



**Fig. 3.**

Postoperative pictures 6 months after the final surgical intervention, fully healed and not showing any signs of infection.

## References

1. Birolini C, de Miranda JS, Utiyama EM, et al. A retrospective review and observations over a 16-year clinical experience on the surgical treatment of chronic mesh infection. What about replacing a synthetic mesh on the infected surgical field? *Hernia* 2015;19:239-46.
2. Meagher H, Clarke Moloney M, Grace PA. Conservative management of mesh-site infection in hernia repair surgery: a case series. *Hernia* 2015;19:231-7.
3. Dangoor A, Seddon B, Gerrand C, et al. UK guidelines for the management of soft tissue sarcomas. *Clin Sarcoma Res* 2016;6:20.