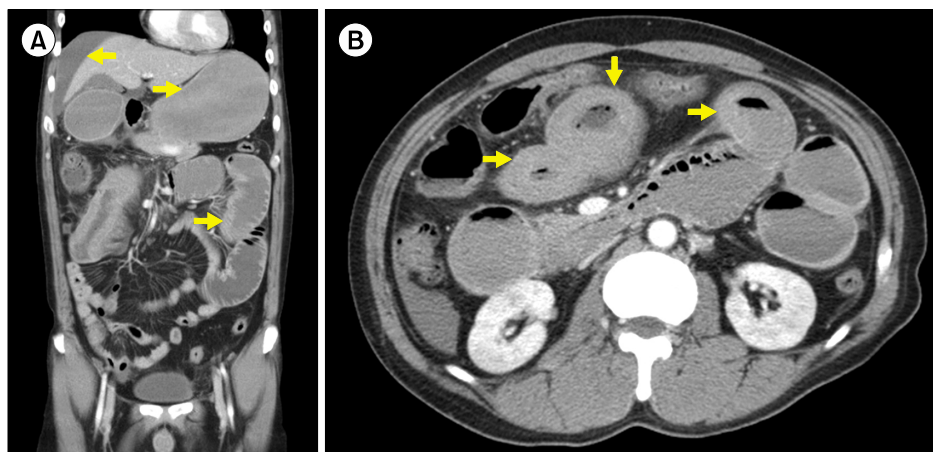


## Spontaneous intramural hemorrhage in a patient with severe hemophilia A

Ken-Hsyuan Shan<sup>1</sup>, Li-Mien Chen<sup>2</sup>, Cheng-Ming Peng<sup>3</sup>, Jiaan-Der Wang<sup>4,5</sup>

<sup>1</sup>Division of Pediatrics, <sup>2</sup>Division of Hematology/Oncology, Department of Internal Medicine, Taichung Armed Forces General Hospital, <sup>3</sup>Division of General Surgery, <sup>4</sup>Center of Hemophilia and Rare Disease, Taichung Veterans General Hospital, <sup>5</sup>School of Medicine, China Medical University, Taichung, Taiwan, China

**Correspondence to** Jiaan-Der Wang, M.D., Ph.D., Center of Rare Disease and Hemophilia, 1650 Taiwan Boulevard Sect. 4, Taichung, Taiwan 40705, China, E-mail: wangjiaander@gmail.com



A 49-year-old man with severe hemophilia A presented with bilious vomiting and abdominal pain for 3 days. There was no history of fever, diarrhea, or abdominal trauma. On physical examination, his abdomen was distended, with the presence of peritoneal signs. According to coagulation studies, the clotting factor VIII level was <1%, and factor VIII inhibitor levels were undetectable. Abdominal computed tomography showed high-density ascites and intraluminal fluid over the stomach and small intestine (A, arrows). In addition, several segments of the small intestine demonstrated marked intramural thickening (B, arrows). Bloody fluid over the peritoneal cavity and a hemorrhagic infarction in 50 cm of the jejunum and 10 cm of the ileum were observed upon surgical intervention. After segmental resection of the infarcted bowel and end-to-end anastomosis, the patient completely recovered with regular infusion of factor VIII 10 days later. Spontaneous intramural hemorrhage is rarely observed in patients with congenital bleeding disorders. The pathogenesis may result from the shredding of the terminal arterial vessels as they leave the mesentery and penetrate the intestinal wall. Although conservative therapy provides regression of the hematoma in most patients, surgical intervention is needed in complicated cases.