

Novel homozygous inactivating mutation of the calcium-sensing receptor gene in neonatal severe hyperparathyroidism responding to cinacalcet therapy

A case report and literature review

Xiaomei Sun, MD^{a,b}, Liang Huang, MM^{b,c}, Jin Wu, MD^{a,b}, Yuhong Tao, MD^{a,b}, Fan Yang, MD^{a,b,*}

Abstract

Rationale: Calcium-sensing receptor (CaSR) mutations can cause life-threatening neonatal severe hyperparathyroidism (NSHPT). The medical management of NSHPT is often challenging and complex. Here, we present a case of NSHPT caused by a novel homozygous CaSR mutation.

Patient concerns: A Chinese female infant presented with poor feeding, constipation, severe hypotonia, and periodic bradycardia. Biochemistry tests revealed markedly elevated serum levels of Ca²⁺ and parathyroid hormone (PTH).

Diagnoses: Genetic sequencing revealed a previously undescribed CaSR mutation in exon 3 (c.242T>A; p.I81K). A diagnosis of NSHPT secondary to homozygously inherited familial hypocalciuric hypercalcemia syndrome was established.

Interventions: Cinacalcet was administered after the common treatments (low-calcium intake, hydration, and furosemide), calcitonin, and pamidronate therapy all failed.

Outcomes: Serum Ca²⁺ decreased and stabilized with cinacalcet therapy. During a 10-month follow-up, total calcium was maintained within the high-normal range and PTH was normalized.

Lessons: A trial of cinacalcet therapy might be undertaken in cases of NSHPT while definitive results of the genetic analysis are awaited.

Abbreviations: ALP = alkaline phosphatase, CaSR = calcium-sensing receptor, DOL = day of life, FHH = familial hypocalciuric hypercalcemia syndrome, NSHPT = neonatal severe hyperparathyroidism, PTH = parathyroid hormone, TMD = transmembrane domain, UCCR = urine calcium-to-creatinine clearance ratio.

Keywords: calcium-sensing receptor, CaSR, cinacalcet, neonatal severe hyperparathyroidism

1. Introduction

The calcium-sensing receptor (CaSR) is a 1078 amino acid cell membrane protein with a large extracellular domain expressed

mainly in the parathyroid glands and kidneys.^[1,2] The CaSR plays key roles in the maintenance of a narrow range (1.1–1.3 mmol/L) of extracellular ionized calcium concentration (Ca²⁺) primarily by regulating parathyroid hormone (PTH) secretion and urinary calcium excretion.^[3–5]

Heterozygous inactivating mutations of the CaSR gene (*CaSR*) usually result in mild, asymptomatic hypercalcemia seen in familial hypocalciuric hypercalcemia syndrome (FHH; OMIM 145980). Homozygous inactivating *CaSR* mutations result in neonatal severe hyperparathyroidism (NSHPT; OMIM 239200). NSHPT usually presents in the first weeks of life with failure to thrive, hypotonia, dehydration, respiratory distress, and metabolic bone disease.^[1,3,4,6]

NSHPT is a life-threatening disorder, and its acute management is based on dietary calcium restriction, intravenous fluid hydration, calcitonin, and bisphosphonate.^[4,6,7] Parathyroidectomy is an option for patients unresponsive to medical therapy.^[5,7–10] However, parathyroidectomy is a complex procedure, and many medical centers have no parathyroidectomy experience in infants. In recent years, cinacalcet (a calcimimetic) has been used for NSHPT. Cinacalcet allosterically modulates the CaSR, increasing its affinity for calcium and thereby decreasing serum PTH and Ca²⁺ levels.^[3,10–14]

We present a case of a Chinese girl diagnosed with NSHPT and treated successfully with cinacalcet after bisphosphonates had failed. Molecular biology analysis revealed an inherited homo-

Editor: N/A.

XS and LH have contributed equally to this work.

This study was supported by the Sichuan Medical Research Project (grant no. S17049).

The authors have no conflicts of interest to disclose.

^a Department of Pediatrics, ^b Key Laboratory of Birth Defects and Related Diseases of Women and Children, Ministry of Education, ^c Department of Pharmacy/Evidence-Based Pharmacy Center, West China Second University Hospital, Sichuan University, Chengdu, Sichuan, China.

* Correspondence: Fan Yang, Department of Pediatrics, West China Second University Hospital, Sichuan University, Chengdu, Sichuan 610041, China (e-mail: hxpediatrics@163.com).

Copyright © 2018 the Author(s). Published by Wolters Kluwer Health, Inc. This is an open access article distributed under the terms of the Creative Commons Attribution-Non Commercial-No Derivatives License 4.0 (CCBY-NC-ND), where it is permissible to download and share the work provided it is properly cited. The work cannot be changed in any way or used commercially without permission from the journal.

Medicine (2018) 97:45(e13128)

Received: 17 July 2018 / Accepted: 12 October 2018

<http://dx.doi.org/10.1097/MD.0000000000013128>

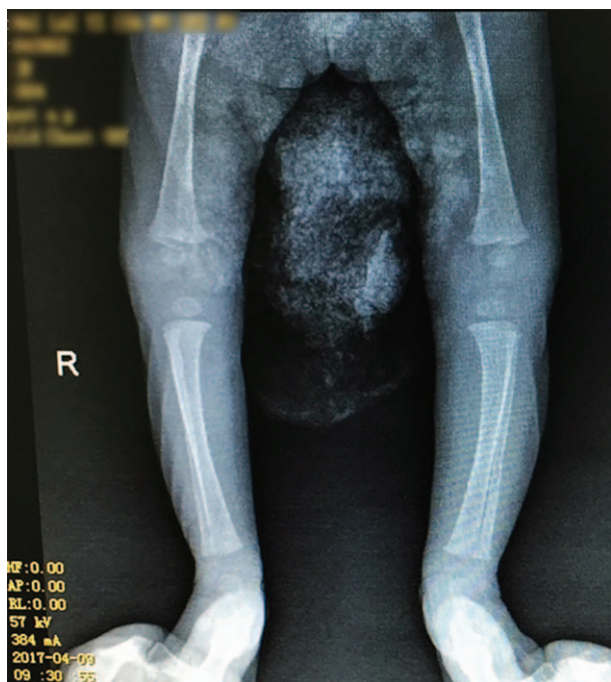


Figure 1. X-ray image of the lower extremities. There was generalized skeletal undermineralization but no signs of bone resorption or fractures.

zygous mutation in the third exon of the *CaSR* (c.242T>A) not previously described.

2. Case presentation

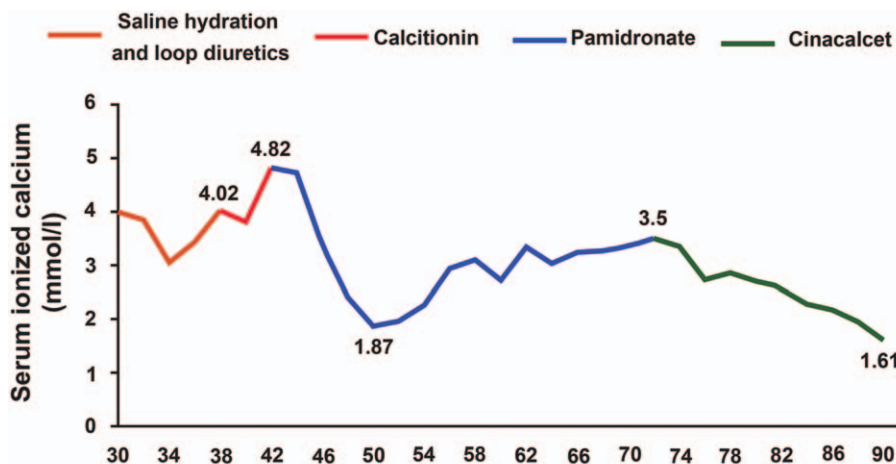
Standard care is performed, so ethical approval is not applicable in this study. Informed consent was obtained from the parents of the infant presented in the case report.

We present the case of a Chinese female infant born by spontaneous vaginal delivery at term (3000g, 50th percentile). The pregnancy had progressed normally, and the family history was unremarkable, although the parents were second cousins. The baby

appeared well initially but exhibited poor feeding, drowsiness and constipation on day of life (DOL) 7. Unresolving pneumonia and hypercalcemia prompted referral to West China Second University Hospital of Sichuan University on DOL 30 (April 6, 2017). Physical examination demonstrated lethargy, severe hypotonia, absent deep tendon reflexes, periodic bradycardic episodes, a bell-shaped chest, and signs of respiratory distress but no dysmorphic features. Biochemistry investigations revealed markedly elevated serum levels of Ca^{2+} (3.99 mmol/L; reference range: 0.98–1.45 mmol/L), total calcium (6.01 mmol/L; reference range: 2.10–2.55 mmol/L), and alkaline phosphatase (ALP; 555 U/L; reference range: 125–250 U/L) as well as a reduced serum concentration of phosphorus (0.56 mmol/L; reference range: 1.45–2.10 mmol/L). The results of other laboratory investigations were intact PTH level of 945.8 pg/mL (reference range: 15.0–68.3 pg/mL); 25-hydroxyvitamin D level of 10.8 ng/mL (reference range: 30–100 ng/mL); and magnesium ion (Mg^{2+}) level of 1.84 mmol/L (reference range: 0.7–1.0 mmol/L). The 24-hour renal calcium excretion was 3.3 mg/kg (reference range: 2–6 mg/kg). Chest computed tomography showed pneumonia. X-ray of the lower extremities revealed generalized skeletal undermineralization but no signs of bone resorption or fractures (Fig. 1). Electrocardiography demonstrated ST segment changes. Both parathyroid ultrasonography and Technetium-99m methoxyisobutylisonitrile (Tc-99m MIBI) scintigraphy were normal, with no evidence of parathyroid adenoma.

Given that NSHPT was suspected due to homozygously inherited FHH, calcium metabolism tests and genetic tests were requested from both parents. For the father, total serum calcium was 2.82 mmol/L, PTH was 42.3 pg/mL, and 24-hour urine calcium-to-creatinine clearance ratio (UCCR) was 0.002. For the mother, total serum calcium was 2.78 mmol/L, PTH was 38.2 pg/mL, and UCCR was 0.008.

After hospitalization, the infant was treated initially with intravenous fluids (1 U of physiological saline and 3 U of 5% dextrose administered at 100 mL/kg), furosemide (0.5 mg/kg every 8 hours), and low-calcium milk. Since the hypercalcemia did not improve, salmon calcitonin (Novartis Pharma Schweiz Aktien Gesellschaft, Schaffhauserstrasse, Stein, Switzerland) was given intramuscularly (8 IU/kg per day, every 12 hours) from DOL 38 for 4 days. However, the patient showed a worsening of



Calcium tendency chart

Figure 2. Changes in the serum levels of ionized calcium during the administration of different medical therapies. The numbers annotating the graph show the values of serum ionized calcium at specific time points.

hypercalcemia (Fig. 2), so treatment with pamidronate (0.5 mg/kg per day iv, administered every 2 days) was started on DOL 42. The patient showed a response to pamidronate in the initial phase, with serum Ca^{2+} levels falling to 1.87 mmol/L on DOL 50, the 9th day of pamidronate therapy. However, serum Ca^{2+} levels subsequently increased over the course of 22 days to 3.5 mmol/L. Therefore, definitive therapy was sought. After obtaining informed consent from the parents, therapy with cinacalcet (Kyowa Hakko Kirin Co., Ltd, Ohtemachi, Chiyoda-ku, Tokyo, Japan) was initiated on DOL 72 (30 mg/m² per day, twice daily). Serum Ca^{2+} decreased and stabilized at around 2.8 mmol/L. On DOL 78, the dose of cinacalcet was adjusted to 45 mg/m² per day, twice daily. Serum Ca^{2+} decreased further and stabilized at around 1.6 mmol/L, while PTH decreased to 5.5 pg/mL (Fig. 2). The patient has been followed-up monthly for 10 months. She is thriving and developing normally. The total calcium level has been maintained within the high-normal range, and the levels of PTH and ALP have been normal.

3. Sequence analysis of the *CaSR*

Genetic sequencing of the patient's *CaSR* (Beijing Zhiyin Oriental Translational Medical Research Center, Yizhuang, Beijing, China) revealed a previously undescribed homozygous T>A point mutation at nucleotide c.242 in exon 3 (c.242T>A), which was heterozygous in both parents. This mutation results in the replacement of isoleucine by lysine at codon 81 (p.I81K). The NSHPT associated with this novel homozygous mutation (c.242T>A; p.I81K) in the *CaSR* was transmitted as an autosomal recessive trait in this family.

4. Discussion

The patient described in this case report presented with life-threatening neonatal hypercalcemia (serum Ca^{2+} > 4 mmol/L), very high PTH levels, failure to thrive, severe hypotonia, and respiratory distress. The clinical diagnosis of NSHPT was confirmed by genetic tests.^[3,15] The sensitivity of Tc-99m MIBI scintigraphy in patients with primary hyperparathyroidism ranges between 54% and 100%, with a relatively high false-negative rate.^[16] Thus, a Tc-99m MIBI scan may be normal in patients with NSHPT.

The medical management of NSHPT is often challenging and complex, and calcium intake must be restricted. Therapy for hypercalcemia was initiated using hydration and administration of a loop diuretic and calcitonin. Calcitonin can reduce bone and tubular calcium resorption, but its effect has been described as transient.^[5,7] Calcitonin was not effective in our patient.

Bisphosphonates that inhibit osteoclastic bone resorption have been increasingly used in children for a variety of disorders including hypercalcemia. Therefore, the short-term use of a bisphosphonate is logical. In NSHPT, it is thought that uncontrolled hyperparathyroidism stimulates osteoclasts and leads to a marked increase in bone resorption, exacerbating hypercalcemia.^[6,17] The Ca^{2+} levels in our patient decreased during the first 9 days of pamidronate administration but subsequently increased, accompanied by a rebound increase in serum PTH. Individual variability in the responsiveness of NSHPT to pamidronate has been reported. In some cases, pamidronate was found to control severe hypercalcemia, enabling the postponement or avoidance of surgery.^[6,8,10,18] However, there have been reports of Ca^{2+} levels decreasing temporarily following bisphosphonate administration but then

subsequently increasing,^[1,12,19,20] while other cases have shown no apparent immediate fall in serum Ca^{2+} .^[7,8] Hypercalcemia in NSHPT has a multifactorial etiology and is not simply secondary to rampant bone resorption^[6,19]; pamidronate has limited efficacy and does not specifically address the problem of abnormal *CaSR* function.^[21] In addition, the adverse effects of long-term use of pamidronate in children are not fully known.^[19] Thus, we propose that although pamidronate may not represent a definitive therapy, it could be used as a short-term medical therapy to stabilize a patient's severe hypercalcemia.

Since the patient had only a transient response to pamidronate, definitive therapy was sought. Parathyroidectomy is a life-saving intervention, but the family expressed reservations about this option. Hence, cinacalcet was offered as an experimental alternative, since it has been shown previously to be effective in some cases. After discussion with the parents regarding the risks and benefits of the alternatives, cinacalcet was chosen as the therapeutic option and consent for treatment was provided.

Calcimimetics are drugs that interact with the transmembrane domain (TMD) of the *CaSR* and make the receptor more sensitive to Ca^{2+} . Calcimimetics suppress PTH levels and increase renal Ca^{2+} excretion, which can avoid the need for surgery. Cinacalcet, a type II calcimimetic, is a positive allosteric activator of the *CaSR*.^[3-5,10] Cinacalcet has proven useful in the management of neonatal hyperparathyroidism or NSHPT^[1,10,12,13] but is not effective in every case.^[5,7,19,20] To date, there have been 4 published cases of NSHPT successfully treated with cinacalcet (reviewed in Table 1).^[1,10,13] Our patient responded well to cinacalcet, showing an obvious improvement in serum Ca^{2+} level and normalization of PTH level, suggesting a positive effect of cinacalcet on this previously unreported homozygous mutation in the *CaSR*. The present report expands the number of cases of NSHPT successfully treated with cinacalcet to 5. Despite the successes reported in these 5 patients, other cases of NSHPT were found to be resistant to cinacalcet (reviewed in Table 1).^[5,7,19,20] Thus, the effects of cinacalcet may vary depending on the *CaSR* mutation.

Although NSHPT classically manifests as the result of a homozygously inherited inactivating mutation of *CaSR*, some NSHPT cases are due to compound homozygous or heterozygous inactivating mutations of *CaSR* or simply de novo mutations in heterozygotes.^[1-4,22] The type of mutation can affect the severity of the clinical manifestation and the response to treatment.^[5] In the present case, the proband was homozygous for a *CaSR* allele with a missense variant, I81K, which has not been previously described. The proband's father and mother were asymptomatic heterozygous carriers for the mutation and could be diagnosed as FHH. Prediction analysis of the functional effect of the I81K *CaSR* variant using PROVEAN, PolyPhen-2, SIFT, MutationTaster, and REVEL revealed that this mutation was very likely to be deleterious.

Amino acid 81 of the *CaSR* lies within the extracellular Venus Flytrap module, which is the principal site of Ca^{2+} binding.^[4,23,24] Furthermore, there is evidence that the TMD is also involved in Ca^{2+} sensing because a mutant *CaSR* lacking the extracellular domain (ECD) also responded to Ca^{2+} and other polyvalent cations.^[25] The existence of multiple binding sites for Ca^{2+} in the *CaSR* might explain why the I81K variant, which showed abnormal Ca^{2+} sensing function (since 1 Ca^{2+} -binding site was inactivated), was still able to respond to a calcimimetic (via other Ca^{2+} -binding sites).

Geng et al identified 4 novel Ca^{2+} -binding sites in the ECD structure of each *CaSR* protomer and named these 1 through 4. The bound Ca^{2+} located at site 1 is primarily coordinated by the

Table 1

Published cases of neonatal severe hyperparathyroidism treated successfully or unsuccessfully with cinacalcet.

Study	Disorder	Cinacalcet dose	Cinacalcet therapy initiation	Cinacalcet therapy duration	CaSR mutation: nucleotide (c.) and protein (p.)	Other therapy used	Response to cinacalcet (Y/N)	PTx (Y/N)	Growth of patient
Cinacalcet reported to be effective Gannon et al ^[13]	NSHPT	0.4–9.6 mg/kg per day	Newborn period	18 mo	Inherited heterozygous c.554G>A (p.R185Q)	Saline, phosphate, cholecalciferol	Y	N	—
Wilhelm-Bais et al ^[10]	NSHPT, PTx failed	1.4–3.5 mg/kg per day	6 y	6 y	Inherited heterozygous c.206G>A (p.R69H)	Pamidronate, phosphate, hydration	Y	Y, before cinacalcet	Growth improved and followed –1 SD
Fisher et al ^[1]	NSHPT	2.4–7.4 mg/kg per day	12 mo	32 mo	De novo heterozygous c.554G>A (p.R185Q)	Saline, low calcium formula, phosphate, pamidronate	Y	N	Growth parameters recovered and followed 3rd percentile
Fisher et al ^[1]	NSHPT	1–2.7 mg/kg per day	4 mo	13 mo	De novo heterozygous c.554G>A (p.R185Q)	Saline, low calcium formula, phosphate	Y	N	Weight and length reached 90th and 75th percentiles at 12 mo of age
Current report	NSHPT	30–45 mg/m ² per day	72 d	8 mo	Inherited homozygous c.242T>A (p.I81K)	Saline, diuretic, calcitonin, pamidronate, cholecalciferol	Y	N	Growth parameters recovered by 5 mo of age
Reh et al ^[12]	NHPT	20 mg/m ² per day	23 d	12 mo	De novo heterozygous c.554G>A (p.R185Q)	Saline, furosemide, pamidronate	Y	N	All growth parameters recovered by 5 mo of age
Cinacalcet reported not to be effective García Soblechero et al ^[5]	NSHPT	10–25 mg/m ² per day	2 mo	42 d	De novo heterozygous c.1392_1404del13 p.Arg465 Leufs*9	Saline, furosemide, glucocorticoids, low calcium formula, calcitonin	N	Y	—
Atay et al ^[7]	NSHPT	30–90 mg/m ² per day	28 d	17 d	c.[222_226delGATAT; 740C>T] p.[M741fs*24;S247F]	Saline, furosemide, calcitonin, pamidronate	N	Y	—
Savas-Erdeve et al ^[9]	NSHPT	10–25 mg/m ² per day	29 d	16 d	De novo heterozygous c.1630C>T (p.Arg544)	Saline/dextrose, furosemide, prednisone, pamidronate	N	Y	—
Murphy et al ^[20]	NSHPT	0.4–8.5 mg/kg per day	18 d	18 d	Inherited heterozygous c.206G>A (p.R69H)	Saline, furosemide, pamidronate	N (partial control for all therapies)	Y	—

CaSR = calcium-sensing receptor, NHPT = neonatal hyperparathyroidism, NSHPT = neonatal severe hyperparathyroidism, PTx = parathyroidectomy, SD = standard deviation.

backbone carbonyl oxygen atoms of I81, S84, L87, and L88.^[26] Thus, we speculate that the replacement of isoleucine by lysine at codon 81 interferes with the coordination of a divalent cation at this binding site and results in abnormal Ca²⁺ sensing function. The mechanism by which cinacalcet is able to overcome the impairment of Ca²⁺ binding at this site remains to be determined. Although the I81K variant has not been described previously, the disease-causing mutation I81K has been shown to abolish the Ca²⁺-dependent receptor response,^[27] highlighting the importance of I81 for normal CaSR Ca²⁺ binding and function.

The 4 previously reported cases of NSHPT that responded to cinacalcet were all associated with heterozygous mutations (reviewed in Table 1). García Soblechero et al reported a case of NSHPT with a homozygous mutation of the *CaSR* that showed treatment failure with cinacalcet, whereas the present case with a homozygous mutation was responsive to the drug. We suggest that a mutation of the *CaSR* that loses the Ca²⁺-binding domain or cinacalcet-binding domain would be unresponsive to cinacalcet irrespective of whether the mutation was homozygous or heterozygous. Residual functionality of the CaSR may be an important predictor of the success of cinacalcet therapy.^[1,19] A prompt assessment of the *CaSR* genotype is desirable to determine whether treatment with a calcimimetic is suitable.

Our patient experienced no adverse effects of cinacalcet, such as nausea, vomiting, or hypocalcemia. Nonetheless, we recommend that calcium, phosphorus, PTH, and ALP levels be monitored regularly in patients administered cinacalcet.

In conclusion, we report a case of NSHPT caused by a novel homozygous inactivating mutation in the *CaSR* that responded very well to cinacalcet therapy. We suggest that a trial of cinacalcet therapy be undertaken in cases of NSHPT while definitive results of the genetic analysis are awaited.

Author contributions

Conceptualization: Xiaomei Sun.

Data curation: Xiaomei Sun, Liang Huang, Jin Wu.

Funding acquisition: Xiaomei Sun, Fan Yang.

Writing – original draft: Xiaomei Sun, Liang Huang.

Writing – review & editing: Xiaomei Sun, Yuhong Tao, Fan Yang.

References

- [1] Fisher MM, Cabrera SM, Imel EA. Successful treatment of neonatal severe hyperparathyroidism with cinacalcet in two patients. *Endocrinol Diabetes Metab Case Rep* 2015;2015:150040.
- [2] Glaudo M, Letz S, Quinkler M, et al. Heterozygous inactivating *CaSR* mutations causing neonatal hyperparathyroidism: function, inheritance and phenotype. *Eur J Endocrinol* 2016;175:421–31.
- [3] Vahe C, Benomar K, Espiard S, et al. Diseases associated with calcium-sensing receptor. *Orphanet J Rare Dis* 2017;12:19.
- [4] Egbuna OI, Brown EM. Hypercalcaemic and hypocalcaemic conditions due to calcium-sensing receptor mutations. *Best Pract Res Clin Rheumatol* 2008;22:129–48.
- [5] García Soblechero E, Ferrer Castillo MT, Jimenez Crespo B, et al. Neonatal hypercalcemia due to a homozygous mutation in the calcium-sensing receptor: failure of cinacalcet. *Neonatology* 2013;104:104–8.
- [6] Waller S, Kurzwinski T, Spitz L, et al. Neonatal severe hyperparathyroidism: genotype/phenotype correlation and the use of pamidronate as rescue therapy. *Eur J Pediatr* 2004;163:589–94.
- [7] Atay Z, Bereket A, Haliloglu B, et al. Novel homozygous inactivating mutation of the calcium-sensing receptor gene (*CASR*) in neonatal severe hyperparathyroidism-lack of effect of cinacalcet. *Bone* 2014;64:102–7.
- [8] Mallet E. Working Group on Calcium Metabolism/Primary hyperparathyroidism in neonates and childhood. The French experience (1984–2004). *Horm Res* 2008;69:180–8.
- [9] Al-Shanafey S, Al-Hosaini R, Al-Ashwal A, et al. Surgical management of severe neonatal hyperparathyroidism: one center's experience. *J Pediatr Surg* 2010;45:714–7.
- [10] Wilhelm-Bals A, Parvex P, Magdelaine C, et al. Successful use of bisphosphonate and calcimimetic in neonatal severe primary hyperparathyroidism. *Pediatrics* 2012;129:e812–6.
- [11] Timmers HJ, Karperien M, Hamdy NA, et al. Normalization of serum calcium by cinacalcet in a patient with hypercalcaemia due to a de novo inactivating mutation of the calcium-sensing receptor. *J Intern Med* 2006;260:177–82.
- [12] Reh CM, Hendy GN, Cole DE, et al. Neonatal hyperparathyroidism with a heterozygous calcium-sensing receptor (*CASR*) R185Q mutation: clinical benefit from cinacalcet. *J Clin Endocrinol Metab* 2011;96:E707–12.
- [13] Gannon AW, Monk HM, Levine MA. Cinacalcet monotherapy in neonatal severe hyperparathyroidism: a case study and review. *J Clin Endocrinol Metab* 2014;99:7–11.
- [14] Sato T, Muroya K, Hanakawa J, et al. Potential utility of cinacalcet as a treatment for CDC73-related primary hyperparathyroidism: a case report. *Clin Pediatr Endocrinol* 2016;25:91–8.
- [15] Hannan FM, Thakker RV. Calcium-sensing receptor (*CaSR*) mutations and disorders of calcium, electrolyte and water metabolism. *Best Pract Res Clin Endocrinol Metab* 2013;27:359–71.
- [16] Ozderya A, Temizkan S, Gul AE, et al. Biochemical and pathologic factors affecting technetium-99m-methoxyisobutylisonitrile imaging results in patients with primary hyperparathyroidism. *Ann Nucl Med* 2018;32:250–5.
- [17] Sebestyén JF, Srivastava T, Alon US. Bisphosphonates use in children. *Clin Pediatr (Phila)* 2012;51:1011–24.
- [18] Fox L, Sadowsky J, Pringle KP, et al. Neonatal hyperparathyroidism and pamidronate therapy in an extremely premature infant. *Pediatrics* 2007;120:e1350–4.
- [19] Savas-Erdeve S, Sagsak E, Keskin M, et al. Treatment experience and long-term follow-up data in two severe neonatal hyperparathyroidism cases. *J Pediatr Endocrinol Metab* 2016;29:1103–10.
- [20] Murphy H, Patrick J, Baez-Irizarry E, et al. Neonatal severe hyperparathyroidism caused by homozygous mutation in *CASR*: a rare cause of life-threatening hypercalcemia. *Eur J Med Genet* 2016;59:227–31.
- [21] Lu JY, Yang Y, Gnacadja G, et al. Effect of the calcimimetic R-568 [3-(2-chlorophenyl)-N-((1R)-1-(3-methoxyphenyl)ethyl)-1-propanamine] on correcting inactivating mutations in the human calcium-sensing receptor. *J Pharmacol Exp Ther* 2009;331:775–86.
- [22] Obermannova B, Banghova K, Sumnik Z, et al. Unusually severe phenotype of neonatal primary hyperparathyroidism due to a heterozygous inactivating mutation in the *CASR* gene. *Eur J Pediatr* 2009;168:569–73.
- [23] Rus R, Haag C, Bumke-Vogt C, et al. Novel inactivating mutations of the calcium-sensing receptor: the calcimimetic NPS R-568 improves signal transduction of mutant receptors. *J Clin Endocrinol Metab* 2008;93:4797–803.
- [24] Diaz-Soto G, Rocher A, Garcia-Rodriguez C, et al. The calcium-sensing receptor in health and disease. *Int Rev Cell Mol Biol* 2016;327:321–69.
- [25] Hu J, McLarnon SJ, Mora S, et al. A region in the seven-transmembrane domain of the human Ca²⁺ receptor critical for response to Ca²⁺. *J Biol Chem* 2005;280:5113–20.
- [26] Geng Y, Mosyak L, Kurinov I, et al. Structural mechanism of ligand activation in human calcium-sensing receptor. *eLife* 2016;5:e13662.
- [27] Hendy GN, Guarnieri V, Canaff L. Calcium-sensing receptor and associated diseases. *Prog Mol Biol Transl Sci* 2009;89:31–95.