

Case Report

Contralateral delayed epidural hematoma following intracerebral hematoma surgery

Volodymyr O. Solomiichuk, Konstantin I. Drizhdov

Neurosurgical Department, Yalta City Hospital, Yalta, Crimea, Ukraine

E-mail: *Volodymyr O. Solomiichuk - solomiichuk@gmail.com; Konstantin I. Drizhdov - yaltaneurozav@bigmir.net

*Corresponding author

Received: 31 May 13 Accepted: 29 August 13 Published: 03 October 13

This article may be cited as:Solomiichuk VO, Drizhdov KI. Contralateral delayed epidural hematoma following intracerebral hematoma surgery. *Surg Neurol Int* 2013;4:134.Available FREE in open access from: <http://www.surgicalneurologyint.com/text.asp?2013/4/1/134/119234>

Copyright: © 2013. Solomiichuk VO. This is an open-access article distributed under the terms of the Creative Commons Attribution License, which permits unrestricted use, distribution, and reproduction in any medium, provided the original author and source are credited.

Abstract

Background: Delayed epidural hematoma (EDH) is an uncommon finding in patients after intracranial hematomas evacuation. It occurs in 6.7-7.4% of cases. A total of 29 reports were found in literature. Between them were no cases of delayed contralateral EDH after intracerebral hematoma evacuation.

Case Description: This paper represents a clinical case of a 28-year-old male patient with opened penetrating head injury, who underwent left frontal lobe intracerebral hematoma evacuation and one day later a contralateral EDH was found and successfully surgically treated.

Conclusion: Contralateral EDH is a life-threatening neurosurgical emergency case, which can occur during first 24 hours after decompressive craniectomy. Control CT scans must be performed next day after the operation to verify and treat contralateral EDH timely.

Key Words: Decompressive craniectomy, epidural hematoma, head injury, postoperative hemorrhage

Access this article online**Website:**www.surgicalneurologyint.com**DOI:**

10.4103/2152-7806.119234

Quick Response Code:**INTRODUCTION**

Delayed epidural hematoma (EDH) is an uncommon finding in patients after intracranial hematomas evacuation. Contralateral intracranial hematoma develops in 7.4% of cases after decompressive surgery,^[10] especially contralateral hematoma formation following acute subdural hematoma evacuation is a well-described complication.^[2] In some series contralateral EDH are found in 6.7% cases.^[1] A total of 29 cases of such EDHs were found in literature [Table 1]. Among them was 1 case of delayed EDH after normal computed tomography (CT) scans on admission;^[4] 1 case after linear occipital fracture;^[4] 1 case after traumatic intraventricular bleeding;^[4] 1 case after the initial EDH;^[6] 3 cases after unstated primary lesions;^[8] and 22 cases after acute

subdural hematoma surgery.^[5,7-9] There were no reports about delayed contralateral EDH after intracerebral hematoma evacuation found in literature.

The pathophysiology of delayed EDH is debated. Conventional wisdom says that in most cases the source of the bleeding exists at the time of the trauma, but the protective mechanisms prevent immediate appearance of the hematoma.^[4] Between them are these, connected with increased ICP and include brain edema and another intracranial hematoma. They exert a tamponade effect with compression of the torn vessels. Lowering high ICP with mannitol, removal of space-occupying mass and/or decompressive craniectomy causes brain shrinkage and decompression of these vessels that which then start to bleed.^[3,4,10]

CASE REPORT

A 28-year-old right-handed male with trauma signs on his head (a wound in his occipital region, nasal hemoliquorrhea, right-sided otorrhorrhea) was admitted to Yalta City Hospital after he felt down while riding a skateboard. On admission, he was Glasgow coma scale (GCS) 5 with left dilated pupil.

CT scans showed intracerebral traumatic hematoma in the left frontal lobe, 6 mm midline shift, right temporal bone fracture and a small pneumocephalus in sellar region [Figure 1].

Performed operation: left-sided hemicraniectomy through “trauma-flap” incision, evacuation of

traumatic intracerebral hematoma in left frontal lobe. Intraoperatively an acute brain swelling occurred. Patient was transferred to ICU after the operation. One day after the operation, right-sided anisocoria occurred and a contralateral EDH with 10 mm of midline shifting was found at the control CT scans [Figure 2].

Patient underwent decompressive craniectomy in the right temporo-parietal region and evacuation of EDH about 100 cc in volume.

One day later there were no signs of residual hematoma on CT scans [Figure 3].

At the fifth day after the operation, percutaneous tracheostomy was performed. Patient was comatose 19 days after admitting to the hospital. He underwent conservative treatment of brain edema. After that control CT scans were performed [Figure 4].

Next day patient became apallic and 7 days later akinetic mutism was found.

Table 1: Cases of contralateral EDH, found in literature

Study	Age/sex	Primary lesion	Treatment	GOS
Saberi <i>et al.</i> ^[7]	19/M	Acute SDH	ICP monitoring	2
Ban <i>et al.</i> ^[11]	42/M	Acute SDH	Evacuation of EDH	5
	62/M			3
	18/M			5
	61M	Acute SDH and contusion		1
	24/F	Acute SDH, small EDH		5
Milo <i>et al.</i> ^[4]	33/M	Occipital linear fracture		5
	19/M	No intracranial pathology		5
	9/F	Intraventricular bleeding		1
Mohindra <i>et al.</i> ^[5]	45/M	Acute SDH		4
	28/M	Acute SDH		1
Ortega-Martinez <i>et al.</i> ^[6]	25/F	Acute EDH		1
Shen <i>et al.</i> ^[8]	51/M	Acute SDH		5
	52/F	Acute SDH		4
	35/M	Not stated		1
	43/M			1
	40/F			2
Su <i>et al.</i> ^[9]	39/M	Acute SDH		3
	70/M			5
	35/F			1
	43/F			5
	40/M			2
	38/M			2
	19/M			5
	25/F			1
	44/M			1
	28/M			2
	25/F			2
	19/F			1

GOS: Glasgow outcome scale; 1 death, 2 vegetative state, 3 severe disability, 4 moderate disability, 5 good recovery, EDH: Epidural hematoma, SDH: Subdural hematoma

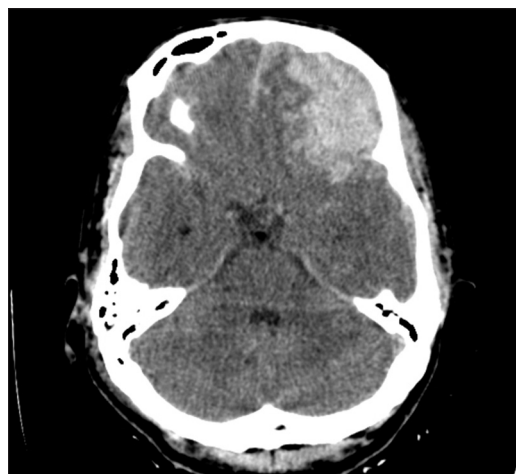


Figure 1: Intracerebral hematoma in left frontal lobe which causes 6 mm shifting of midline

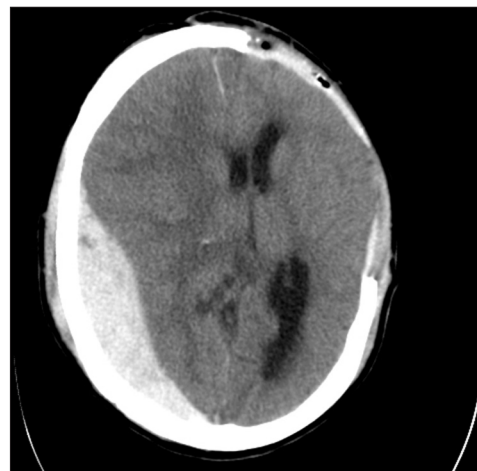


Figure 2: Contralateral delayed EDH with 10 mm of midline shifting one day after the decompressive craniectomy

At the 32nd day in the hospital, he was transferred from the intensive care unit (ICU) into the neurosurgical department. One month later patient was awake and spoke with single separated words.

On 76th day in the hospital the CT scans were performed with 1 mm collimation for the titanium mesh implants and stereolithographic models development [Figure 5].

At his 2 month follow-up, he had neurological deficit of

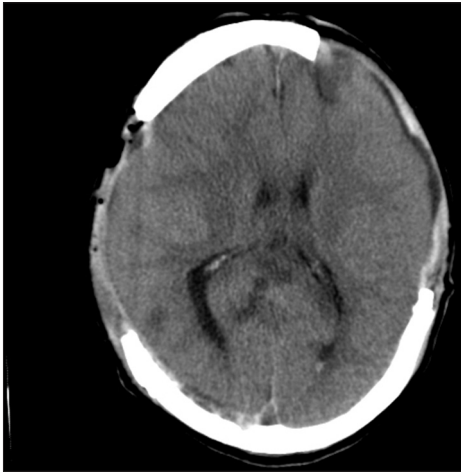


Figure 3: CT scan in a day after the EDH evacuation

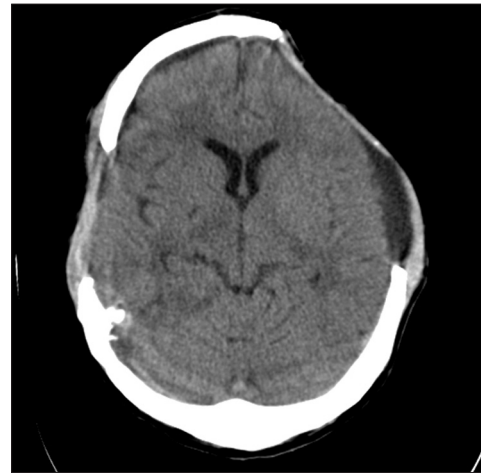


Figure 4: CT scan shows sinking skin flap at the 19th day after decompressive craniectomy

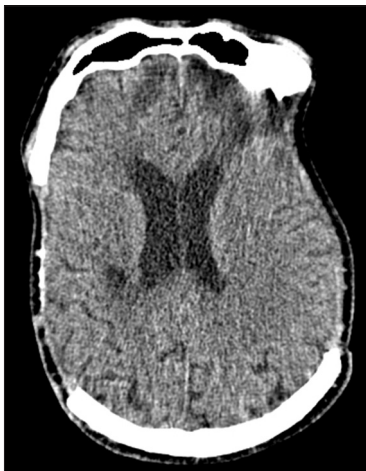

Figure 5: CT scan at the 76th day in the hospital

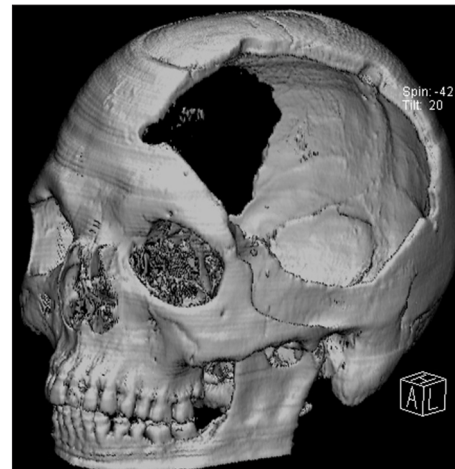


Figure 6: Bone defects (left side) before cranioplasty

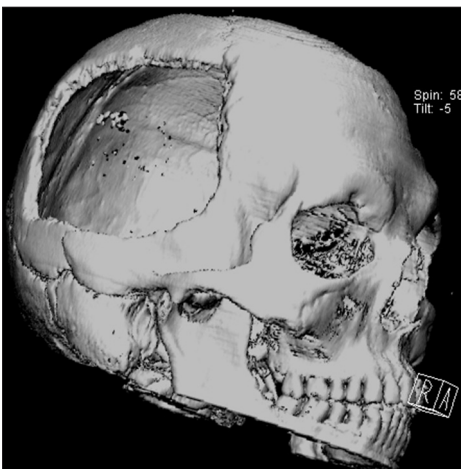


Figure 7: Bone defects (right side) before cranioplasty

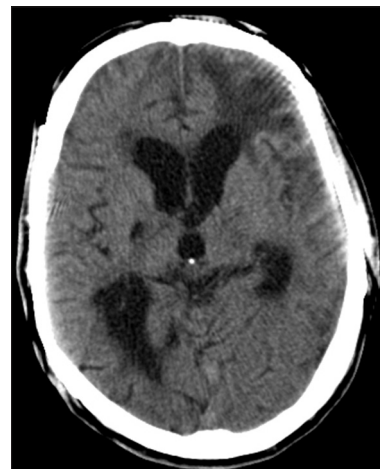

Figure 8: CT scan in a month after the cranioplasty

left-sided spastic hemiparesis, anosognosia, right-sided convergent strabismus.

Bilateral cranioplasty of two huge bone defects [Figures 6 and 7] with individually constructed titanium mesh was performed.

Postoperative period was uneventful and in 15 days patient was sent to rehabilitation.

CT scans in a month after the cranioplasty showed brain expansion to its original shape [Figure 8].

CONCLUSION

Considering that the reduction of intracranial pressure by removing the intracranial hematoma or/and performing decompressive craniectomy is a predisposing factor for development of contralateral EDH, it is recommended to perform CT scans during the first day after surgery to exclude contralateral EDH development, which can cause devastating consequences such as deep neurologic deficit, apallic syndrome, and even death.

REFERENCES

1. Ban M, Agawa M, Fukami T. Delayed evolution of posttraumatic contralateral extracerebral hematoma after evacuation of initial hematoma. *Neurol Med Chir (Tokyo)* 1991;31:927-30.

2. Fridley J, Thomas J, Kitagawa R, Chern J, Omeis I. Immediate development of a contralateral acute subdural hematoma following acute subdural hematoma evacuation. *J Clin Neurosci* 2011;18:422-3.
3. König A, Laas R, Herrmann HD. Cerebellar haemorrhage as a complication after supratentorial craniotomy. *Acta Neurochir (Wien)* 1987;88:104-8.
4. Milo R, Razon N, Schiffer J. Delayed epidural hematoma. A review. *Acta Neurochir (Wien)* 1987;84:13-23.
5. Mohindra S, Mukherjee KK, Gupta R, Chhabra R, Gupta SK, Khosla VK. Decompressive surgery for acute subdural haematoma leading to contralateral extradural haematoma: A report of two cases and review of literature. *Br J Neurosurg* 2005;19:490-4.
6. Ortega-Martínez M, Fernández-Portales I, Gómez Peral LF, Cabezedo JM. Contralateral extradural hematoma during evacuation of a previous one. *Neurocirugía (Astur)* 2004;15:468-71.
7. Saberi H, Meybodi AT, Meybodi KT, Habibi Z, Mirsadeghi SM. Delayed post-operative contralateral epidural hematoma in a patient with right-sided acute subdural hematoma: A case report. *Cases J* 2009;2:6282.
8. Shen J, Pan JW, Fan ZX, Zhou YQ, Zhan RY. Surgery for contralateral acute epidural hematoma following acute subdural hematoma evacuation: Five new cases and a short literature review. *Acta Neurochir (Wien)* 2013;155:335-41.
9. Su TM, Lee TH, Chen WF, Lee TC, Cheng CH. Contralateral acute epidural hematoma after decompressive surgery of acute subdural hematoma: Clinical features and outcome. *J Trauma* 2008;65:1298-302.
10. Yang XF, Wen L, Shen F, Li G, Lou R, Liu WG, et al. Surgical complications secondary to decompressive craniectomy in patients with a head injury: A series of 108 consecutive cases. *Acta Neurochir (Wien)* 2008;150:1241-7.

Disclaimer: The authors of this article have no conflicts of interest to disclose, and have adhered to SNI's policies regarding human/animal rights, and informed consent. Advertisers in SNI did not ask for, nor did they receive access to this article prior to publication.