

Received: 2021.04.19

Accepted: 2021.07.13

Available online: 2021.07.29

Published: 2021.09.05

# Huge Coronary Aneurysm in a Morbidly Obese Man with Exertional Dyspnea and Chest Pain

## Authors' Contribution:

Study Design A  
Data Collection B  
Statistical Analysis C  
Data Interpretation D  
Manuscript Preparation E  
Literature Search F  
Funds Collection GAB 1 **Ahmad Ali Amirghofran**BEF 2 **Reza Golchin Vafa**ABCDEFG 2-4 **Javad Kojuri**

1 Department of Cardiac Surgery, Shiraz University of Medical Sciences, Shiraz, Iran

2 Department of Cardiology, Professor Kojuri Cardiology Clinic, Shiraz, Iran

3 Department of Cardiology, Shiraz University of Medical Sciences, Shiraz, Iran

4 Clinical Education Research Center, Shiraz University of Medical Sciences, Shiraz, Iran

**Corresponding Author:** Javad Kojuri, e-mail: [Kojurij@yahoo.com](mailto:Kojurij@yahoo.com), [Info@kojuriclinic.com](mailto:Info@kojuriclinic.com)**Conflict of interest:** None declared**Patient:** Male, 64-year-old  
**Final Diagnosis:** Huge coronary aneurysm  
**Symptoms:** Chest discomfort • dyspnea  
**Medication:** Losar 25 mg twice daily • Amlodipine 5 mg twice daily • Aspirin 80 mg daily • Atorvastatin 20 mg daily • Pantaprazole 20 mg daily  
**Clinical Procedure:** Coronary artery bypass graft surgery  
**Specialty:** Cardiac Surgery • Cardiology**Objective:** Rare disease**Background:** Giant coronary artery aneurysm (GCAA) is a rare disease, with an incidence of 0.02% in the general population. GCAA is defined as when the diameter of the coronary artery is more than 4 times the adjacent part or more than 8 mm. There are several causes of GCAA, with atherosclerosis being the most common. Patients with giant coronary artery aneurysms can be asymptomatic or develop chest pain, dyspnea, and palpitations. Complications of GCAA include myocardial infarction, thrombosis, and sudden death, so early treatment is necessary to prevent mortality. There is no standard surgical approach for a giant coronary artery aneurysm.**Case Report:** A 64-year-old man with hypertension, opium addiction, morbid obesity (body weight 151 kg and BMI 46), and benign prostate hyperplasia presented with a giant coronary aneurysm in coronary angiography. The patient underwent cardiac surgery, and a 42-mm coronary aneurysm was detected. The aneurysm had many orifices that opened to the left main coronary artery, left circumflex artery, LAD, the diagonal branch of the LAD, and the septal branch of the LAD. Aneurysmectomy and coronary artery bypass graft were successfully performed.**Conclusions:** Giant coronary artery aneurysms are rare. Patients with giant coronary artery aneurysms may experience sudden death due to myocardial infarction and other cardiovascular complications due to ischemia. Because it is rare, there is no standard surgical approach for a giant coronary artery aneurysm. Further studies need to focus on standardized surgical management of patients with giant coronary artery aneurysms.**Keywords:** Coronary Aneurysm • Obesity • Thoracic Surgical ProceduresFull-text PDF: <https://www.amjcaserep.com/abstract/index/idArt/932786>

842



—



2



21



## Background

Coronary artery aneurysm is a relatively uncommon disease with an estimated incidence of between 1.5% and 5%. There are several causes for this disease, including atherosclerosis, Kawasaki disease, and trauma. Atherosclerosis is the most common cause, accounting for 50% of cases [1]. CAA is called giant when its diameter is more than 4 times the adjacent part or more than 8 mm [2]. Giant coronary artery aneurysm (GCAA) is less common than CAA, with an incidence of 0.02% in the general population [3]. The causes of giant coronary aneurysms are similar to those other coronary aneurysms, and atherosclerosis is the leading cause [4]. A GCAA can also occur following angioplasty [5].

Symptoms of GCAA include chest pain, shortness of breath, and palpitations. However, sometimes patients are asymptomatic [6]. Complications of GCAA include myocardial infarction, thrombosis, and sudden death, so early treatment of this disease is important to prevent mortality [7].

Different surgical procedures can be used, such as aneurysm resection or coronary artery reconstruction. Using the optimal surgical method according to the type of anomaly can play an important role in saving the patient's life [3]. Percutaneous procedures can be used for GCAA surgery in high-risk patients. Occluding with a detachable balloon or detachable coil is one of these procedures [8]. Excluding GCAA from the native coronary artery can be done by percutaneous stenting of the coronary artery [9,10]. Percutaneous interventions can have complications such as thrombosis, dissection, and no re-flow [11].

Due to the rarity of GCAA, there is no standard surgical approach for this disease, and few cases of GCAA have been reported in the literature [1,12-15]. In this case report, we present an interesting patient with GCAA and our successful treatment.

## Case Report

A 64-year-old man was referred to our cardiovascular clinic with exertional dyspnea and chest pain. He had hypertension, opium addiction, and benign prostate hypertrophy. His weight was about 151 kg, and his body mass index was about 46. Coronary angiography was performed. A giant aneurysm was seen at the origin of the left anterior descending (LAD) artery (Figure 1). The patient underwent cardiac surgery. In surgery, we found a clot-filled coronary aneurysm at the origin of the LAD. The aneurysm was behind the pulmonary artery and compressing it. The diameter of the aneurysm was about 42 mm (Figure 2). The aneurysm had many orifices opening to the left main coronary artery, left circumflex artery, LAD, the diagonal branch of the LAD, and the septal branch of the LAD. We

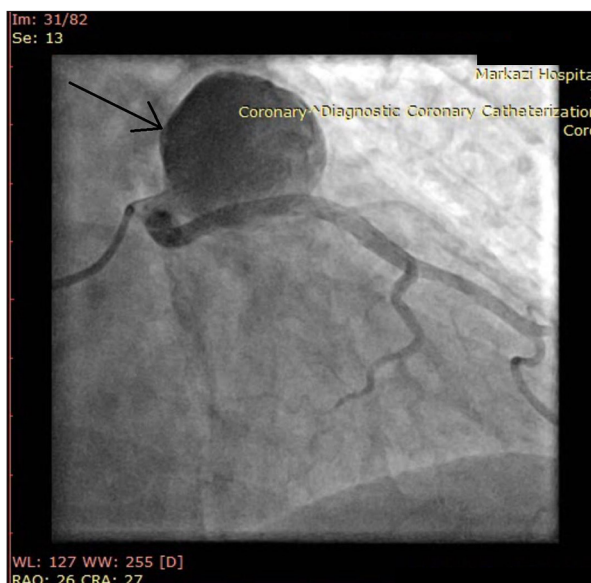


Figure 1. Coronary angiography of the patient shows GCAA at the origin of the LAD.

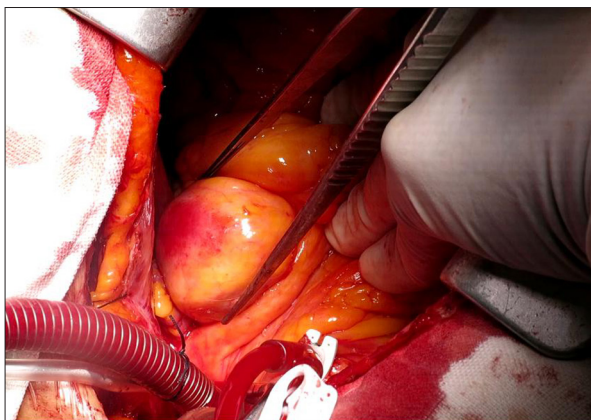


Figure 2. Giant coronary artery aneurysm of the patient.

decided to keep at least the border so that the orifices were not compromised. We kept the floor of the aneurysm and the orifices and excised other parts of the aneurysm. After aneurysmectomy, a coronary artery bypass graft (CABG) was done using the radial artery to the LAD. Flowmetry showed good flow in the LAD. The patient tolerated the procedure and discharged from the hospital.

## Discussion

GCAA is a rare disease that is mainly caused by coronary atherosclerosis [16]. GCAA may be incidentally found in the coronary angiography because the patient can be asymptomatic. In symptomatic cases, the patients can develop chest pain, dyspnea, and palpitations. The right coronary artery appears to be the most involved [1].

GCCA can be fatal. Imai et al reported a 5-year-old boy with a LAD giant aneurysm, who developed cardiac arrest and died [17]. Arboine et al reported a 49-year-old man with GCAA did not tolerate surgery and died [15]. Fatalities may be due to acute myocardial infarction and ventricular tachycardia. Patients may experience sudden death [18]. Crawley et al reported a 56-year-old man who developed with GCCA measuring 70×40 mm. The patient refused cardiothoracic surgery and died 1 month later [19].

Various percutaneous methods have been used for GCAA. These methods include coronary artery stenting and coiling [8-10]. The use of these methods can have short-term and long-term complications for patients [11].

However, there are few cases reports in the literature of patients who survived GCAA. Keyser et al reported a 43-year-old man with a right CAA measuring about 10.6×9.2 cm and 2 small aneurysms. They successfully resected the aneurysm and CABG was performed. He successfully recovered and was discharged [20]. Due to the morbid obesity of the present patient, we had to use a special orthopedic bed for the operation. The surgery was successful and the patient recovered well from the operation.

Coronary artery ectasia is more prevalent in patients with opium addiction [21]. There is little information on the relationship between opium consumption and coronary artery aneurysm [21].

## References:

1. Syed M, Lesch M. Coronary artery aneurysm: A review. *Prog Cardiovasc Dis*. 1997;40:77-84
2. Kato H, Sugimura T, Akagi T, et al. Long-term consequences of Kawasaki disease: A 10-to 21-year follow-up study of 594 patients. *Circulation*. 1996;94:1379-85
3. Li D, Wu Q, Sun L, et al. Surgical treatment of giant coronary artery aneurysm. *J Thorac Cardiovasc Surg*. 2005;130:817-21
4. Hao W-R, Chen F-C, Kao P-F, et al. Adult giant coronary artery aneurysm – a case report and literature review. *Acta Cardiologica Sinica*. 2004;20:187-90
5. Okamura T, Hiro T, Fujii T, et al. Late giant coronary aneurysm associated with a fracture of sirolimus eluting stent: A case report. *J Cardiol*. 2008;51:74-79
6. Ebina T, Ishikawa Y, Uchida K, et al. A case of giant coronary artery aneurysm and literature review. *J Cardiol*. 2009;53:293-300
7. Cohen P, O'Gara PT. Coronary artery aneurysms: A review of the natural history, pathophysiology, and management. *Cardiol Rev*. 2008;16:301-4
8. Peterson MA, Monsein LH, Dangas G, et al. Percutaneous transcatheter management of giant coronary aneurysms. *Circulation*. 1999;100:e8-e11
9. Eshtehardi P, Cook Sp, Moarof I, et al. Giant coronary artery aneurysm: Imaging findings before and after treatment with a polytetrafluoroethylene-covered stent. *Circ Cardiovasc Interv*. 2008;1:85-86
10. Engstrom K, Khan AA, LaRocca G, et al. A giant coronary artery aneurysm treated with a new-generation drug-eluting stent. *JACC Cardiovasc Interv*. 2017;10:e65-66
11. Boyer N, Gupta R, Schevchuck A, et al. Coronary artery aneurysms in acute coronary syndrome: Case series, review, and proposed management strategy. *J Invasive Cardiol*. 2014;26: 283-90
12. Saleh WK, Aljabbari O, Reardon MJ. Case report: A rare case of a giant right coronary artery aneurysm. *Methodist Debaque Cardiovasc J*. 2015;11:135-36
13. Mawatari T, Koshino T, Morishita K, et al. Successful surgical treatment of giant coronary artery aneurysm with fistula. *Ann Thorac Surg*. 2000;70:1394-97
14. Açar B, Ünal S, Yayla Ç, et al. Giant aneurysm of the left main coronary artery: A case report. *J Tehran Heart Cent*. 2018;13:35-37
15. Arboine L, Palacios JM. Left main coronary artery aneurysm. *N Engl J Med*. 2018;378:e32
16. Pham V, de Hemptinne Q, Grinda J-M, et al. Giant coronary aneurysms, from diagnosis to treatment: A literature review. *Arch Cardiovasc Dis*. 2020;113:59-69
17. Imai Y, Sunagawa K, Ayusawa M, et al. A fatal case of ruptured giant coronary artery aneurysm. *Eur J Pediatr*. 2006;165:130-33
18. Lee C-H, Son C-W, Park J-S. Giant left anterior descending artery aneurysm resulting in sudden death. *Hellenic J Cardiol*. 2016;57:263-66
19. Crawley PD, Mahlow WJ, Huntsinger DR, et al. Giant coronary artery aneurysms: Review and update. *Texas Heart Inst J*. 2014;41:603-8
20. Keyser A, Hilker MK, Husser O, et al. Giant coronary aneurysms exceeding 5 cm in size. *Interact Cardiovasc Thorac Surg*. 2012;15:33-36
21. Masoomi M, Ramezani MA, Karimzadeh H. The relationship of opium addiction with coronary artery disease. *Int J Prev Med*. 2010;1(3):182-86

## Conclusions

Giant coronary artery aneurysms are rare. Patients with GCAA may experience sudden death due to myocardial infarction and other cardiovascular complications due to ischemia. There is no standard surgical approach for GCAA due to its rarity. Further studies are needed to elucidate standardized surgical management of patients with GCAA.

## Conflict of Interest

None declared.

## Declaration of Figures Authenticity

All figures submitted have been created by the authors who confirm that the images are original with no duplication and have not been previously published in whole or in part.