

Case Report

# Atypical Endometrial Hyperplasia Arising in a Cesarean Section Scar: A Mechanism of Malignant Transformation

Marta Monist<sup>a</sup> Dorota Lewkowicz<sup>b</sup> Maciej Józwiak<sup>c</sup> Marek Gogacz<sup>a</sup>  
Michał Bogusiewicz<sup>a</sup> Tomasz Rechberger<sup>a</sup> Andrzej Semczuk<sup>a</sup>

<sup>a</sup>2nd Department of Gynecology, Lublin Medical University, Lublin, Poland; <sup>b</sup>Department of Clinical Pathology, Lublin Medical University, Lublin, Poland; <sup>c</sup>Department of Gynecology and Gynecologic Oncology, Białystok Medical University, Białystok, Poland

## Keywords

Atypical endometrial hyperplasia · Cesarean section · Endometriosis · Obesity

## Abstract

The incidence of scar endometriosis in Cesarean sections varies between 0.03 and 0.4%. However, the recently increased rate of Cesarean sections worldwide may be causing an increase in occurrence of scar endometriosis. This report presents anatomopathological evidence of an early-stage malignant transformation in endometriotic tissue from a post-Cesarean scar and briefly reviews possible underlying mechanisms. A 40-year-old woman with a body mass index of 42.7 was referred to the gynecological department with recurrent pain and presence of a palpable mass in her Cesarean section scar. She had undergone this procedure 7 years earlier and began experiencing discomfort and pain at the incision site 6 months postoperatively. Surgical treatment was instituted with complete removal of the lesion. Anatomopathological examination revealed endometriotic tissue intertwined with atypical endometrial hyperplasia and fibrosis. At 2 years' follow-up, she was asymptomatic, both clinically and based on ultrasound examination. Endometriotic foci inoculated within an abdominal scar may undergo malignant transformation. Long-lasting abdominal scar endometriosis, in morbidly obese women, requires special attention from the physician.

© 2019 The Author(s)  
Published by S. Karger AG, Basel

## Introduction

Endometriosis is defined as the presence of endometrial tissue (both glands and stroma) in locations other than the uterine lining [1]. A specific and potentially iatrogenic condition is abdominal wall scar endometriosis after a Cesarean section. The focus, or foci, of ectopic tissue can arise anywhere in the skin, subcutaneous layer, fascial tissue, or even penetrate to the peritoneal cavity. Endometriosis in a surgical scar after Cesarean section is uncommon as it accounts for between 0.03 and 0.4% of cases and its malignant transformation is extremely rare [2, 3].

Sampson was the first to report a malignant transformation of endometriotic foci in 1925. He proposed three criteria to diagnose such a transition: the immediate proximity of endometriosis and cancer tissue within the tumor, confirmed endometrial histology, and no evidence of other primary tumors. Over time, a fourth feature was added, the presence of metaplasia between benign endometriosis and cancer [3]. To date, a limited number of case studies describing the development of endometriosis-associated abdominal wall neoplasms have been documented [2, 4]. Interestingly, not only endometrioid-type endometrial cancer (EC), but also clear-cell carcinomas, endometrial stromal sarcomas, and even concomitant endometrioid-serous ECs were reported in abdominal scars [2, 4]. Of importance, based on a review of 27 publications, Taburiaux et al. [2] suggested a rather poor prognosis for women affected by such malignancies. However, the mean follow-up in their analysis was below 5 years.

Herein we present a case study of a woman of reproductive age with atypical endometrial hyperplasia arising in her Cesarean section scar and review briefly available world literature for possible mechanisms responsible for early neoplastic transformation of heterotopic endometrium.

## Case Report

This case report is in line with CARE guidelines [5]. A morbidly obese 40-year-old woman, para 1, was referred to the gynecological department with persistent pain in the abdominal wall scar after a Cesarean section. She underwent this procedure 7 years earlier and began experiencing discomfort and pain at the operated site 6 months postoperatively. Over the past 3 years, she felt both a 4 × 4 cm mass at the right edge of the Cesarean section scar and pain in the hypogastric area for which she received various analgesics, with no improvement. The pain always intensified with menstruation. Additionally, she suffered from chronic arterial hypertension managed with an angiotensin receptor blocker (losartan 50 mg p.o. daily). Her body mass index was 42.7 (body mass 115 kg; height 164 cm). The patient's mother died of colorectal cancer 2 years earlier.

Two nodules of endometriotic foci were surgically removed with wide margins. The first one, located at the right border of the abdominal scar, was 4 cm in diameter and penetrated the fascia and abdominal muscles. The second was an endometriotic tumor, 5 cm in diameter, located in the scar's midline. It infiltrated the fascia and abdominal muscles. Following removal and wound suturing, drainage was assured with a flexible subcutaneous catheter. The postoperative period was uneventful. The pathology report revealed endometriotic foci coexisting with atypical endometrial hyperplasia and fibrosis (Fig. 1a–c). A detailed anatomicopathological verification revealed clear margins. Immunohistochemical examination displayed positive staining for cytokeratins CKMNF 116 and CKAE1/AE3, and for CD10 and CD68, whereas vimentin was moderately positive (+/–).

The patient was discharged on postoperative day 3. At a current follow-up of 2 years, she is asymptomatic, assessed both clinically and with ultrasound examination.

## Discussion

Endometriotic implants in the anterior abdominal wall may occur after a Cesarean section or a wide array of other abdominal surgical procedures. They may even be present in post-appendectomy scars [6, 7]. The exact incidence of malignant transformation of an abdominal scar without endometriotic implants is unknown, whereas with the involvement of endometriosis, this figure is thought to be rare [2, 4, 8]. Notably, Taburiaux et al. [2] reported that “the mean delay between the first surgery and the diagnosis of the malignant disease of the abdominal wall was 21 years (range of 8–41 years).” Here, we report an unusual case of atypical endometrial hyperplasia, a direct precancerous lesion, arising in an endometriotic Cesarean section scar, diagnosed as early as 7 years postoperatively.

It is well documented that endometriosis may be associated with certain subtypes of ovarian cancers known as endometriosis-associated ovarian cancer (EAOC). The risk for such a transformation is approximately 3-fold higher than the ovarian cancer risk in the general population [9]. Histologically, EAOCs include clear-cell and endometrioid-type carcinomas and differ from other ovarian cancer subtypes by lower grades of endometriotic lesions and favorable overall survival [9, 10]. In contrast, the association of endometriosis with ECs is still unproven. Interestingly, an increased association of endometriosis with EC has been suggested in a recent population-based cohort study [11].

An important question arises: what are the mechanisms responsible for malignant transformation of endometriotic foci inoculated within a post-Cesarean scar? As mentioned, patients with a long-lasting history of ovarian endometriomas have a higher risk for developing ovarian cancer compared with that of the general population [9, 10]. Nezhat et al.’s [1] criteria (patients with long-standing history of endometriosis, endometriosis diagnosed at an early age, endometriosis-associated infertility and/or history of infertility treatment, and ovarian endometrioma) aim to identify women with endometriosis being at a higher risk for malignant transformation [10]. Of note, the majority of endometriosis-associated abdominal wall cancer patients are pre- and perimenopausal [2, 12]. In a classical study on intrauterine endometrial hyperplasia, progression to EC occurred in 8% of patients with simple atypical hyperplasia and in 29% of patients with complex atypical hyperplasia [13].

Yu et al. [11] presented two plausible molecular mechanisms responsible for the transformation of endometriotic foci into EC. The first one is based on estrogenic stimulation and the second is triggered by chronic inflammation. In the first mechanism, endometriosis behaves as an estrogen-dependent disorder, locally producing large amounts of estrogens due to increased expression of aromatase cytochrome P450 and concomitant deficient expression of 17 $\beta$ -hydroxysteroid dehydrogenase type 2 (which results in impaired inactivation of potent estradiol to less potent estrone). Other data revealed striking overexpression of estrogen receptor  $\beta$  (ER $\beta$ ) in endometriotic stromal cells which in turn suppresses estrogen receptor  $\alpha$  (ER $\alpha$ ) expression [14]. This same imbalance is observed in ECs. Moreover, the ER $\beta$ -to-ER $\alpha$  ratio imbalance in endometriotic stromal cells may result in decreased expression of both progesterone receptors in endometriosis and EC cells and, consequently, in their resistance to progesterone treatment [15].

In the second mechanism proposed by Yu et al. [11], among many cytokines, chemokines, and prostaglandins being overexpressed in endometriosis, cyclooxygenase 2 (COX-2) is sub-

stantially increased in both endometriosis and EC. COX-2 takes part in the synthesis of prostaglandin E2 which promotes the initial processes of carcinogenesis and influences cancer cell proliferation and neoangiogenesis. Furthermore, estrogenic stimulation and chronic inflammation are interconnected by COX-2-dependent aromatase expression with a resultant increased estrogen production [15]. Consequently, “there is association between endometriosis and endometrial cancer *via* the link by chronic inflammation” [11]. It seems very likely that our morbidly obese patient had both vivid conversion of androgens to estrogens in her adipose tissue and chronic inflammation of obesity over an extended period.

### Conclusions

In conclusion, endometriotic foci inoculated within an abdominal scar may undergo malignant transformation, similar to eutopic endometrium. A long-lasting history of abdominal scar endometriosis, in morbidly obese women, requires special attention from the physician.

### Statement of Ethics

The patient presented here provided written informed consent for the publication of this manuscript; the according consent form is part of her medical data.

### Funding Sources

This study was supported by Lublin Medical University, Lublin, Poland (Grant No. 326/19 to A.S.).

### Acknowledgements

We would like to thank Mr. Robert Klepacz for his help with slide photographs.

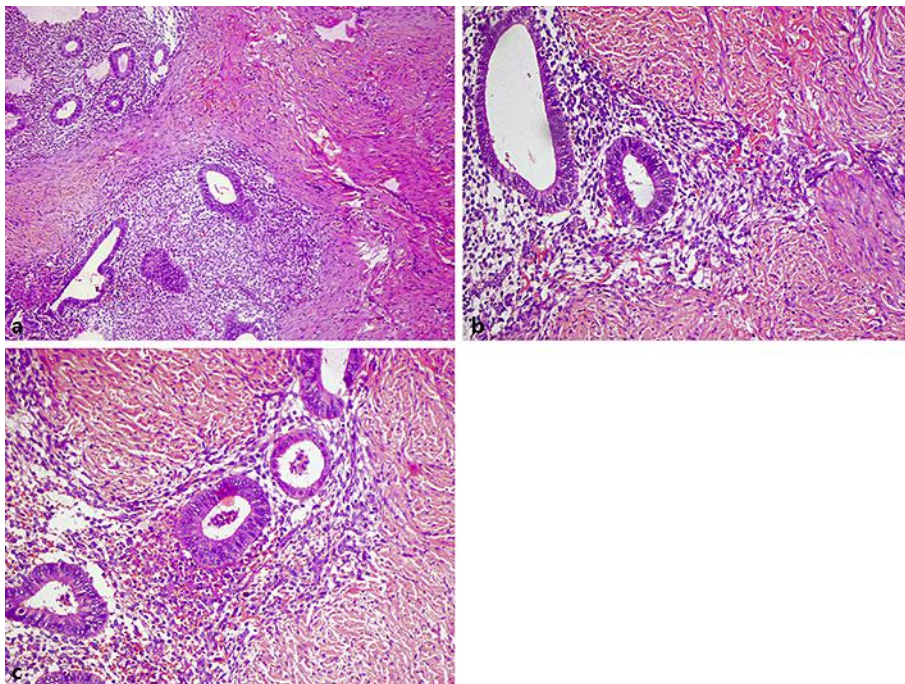
### Disclosure Statement

The authors have no conflicts of interest to declare.

### References

- 1 Nezhat F, Apostol R, Mahmoud M, el Daouk M. Malignant transformation of endometriosis and its clinical significance. *Fertil Steril*. 2014 Aug;102(2):342–4.
- 2 Taburiaux L, Pluchino N, Petignat P, Wenger JM. Endometriosis-associated abdominal wall cancer. *Int J Gynecol Cancer*. 2015 Nov;25(9):1633–8.
- 3 Scott RB. Malignant changes in endometriosis. *Obstet Gynecol*. 1953 Sep;2(3):283–9.
- 4 Mihailovici A, Rottenstreich M, Kovel S, Wassermann I, Smorgick N, Vaknin Z. Endometriosis-associated malignant transformation in abdominal surgical scar: A PRISMA-compliant systematic review. *Medicine (Baltimore)*. 2017 Dec;96(49):e9136.
- 5 Gagnier JJ, Kienle G, Altman DG, Moher D, Sox H, Riley D; CARE Group. The CARE guidelines: consensus-based clinical case report guideline development. *J Clin Epidemiol*. 2014 Jan;67(1):46–51.

- 6 Teng CC, Yang HM, Chen KF, Yang CJ, Chen LS, Kuo CL. Abdominal wall endometriosis: an overlooked but possibly preventable complication. *Taiwan J Obstet Gynecol*. 2008 Mar;47(1):42–8.
- 7 Zhao X, Lang J, Leng J, Liu Z, Sun D, Zhu L. Abdominal wall endometriomas. *Int J Gynaecol Obstet*. 2005 Sep;90(3):218–22.
- 8 Van Gorp T, Amant F, Neven P, Vergote I, Moerman P. Endometriosis and the development of malignant tumours of the pelvis. A review of literature. *Best Pract Res Clin Obstet Gynaecol*. 2004 Apr;18(2):349–71.
- 9 Modesitt SC, Tortolero-Luna G, Robinson JB, Gershenson DM, Wolf JK. Ovarian and extraovarian endometriosis-associated cancer. *Obstet Gynecol*. 2002 Oct;100(4):788–95.
- 10 Worley MJ Jr, Welch WR, Berkowitz RS, Ng SW. Endometriosis-associated ovarian cancer: a review of pathogenesis. *Int J Mol Sci*. 2013 Mar;14(3):5367–79.
- 11 Yu HC, Lin CY, Chang WC, Shen BJ, Chang WP, Chuang CM; Task Force on Carcinogenesis of Endometrial Cancer. Increased association between endometriosis and endometrial cancer: a nationwide population-based retrospective cohort study. *Int J Gynecol Cancer*. 2015 Mar;25(3):447–52.
- 12 Kumar S, Munkarah A, Arabi H, Bandyopadhyay S, Semaan A, Hayek K, et al. Prognostic analysis of ovarian cancer associated with endometriosis. *Am J Obstet Gynecol*. 2011 Jan;204(1):63.e1–7.
- 13 Kurman RJ, Kaminski PF, Norris HJ. The behavior of endometrial hyperplasia. A long-term study of “untreated” hyperplasia in 170 patients. *Cancer*. 1985 Jul;56(2):403–12.
- 14 Bulun SE, Monsavais D, Pavone ME, Dyson M, Xue Q, Attar E, et al. Role of estrogen receptor- $\beta$  in endometriosis. *Semin Reprod Med*. 2012 Jan;30(1):39–45.
- 15 Collins F, MacPherson S, Brown P, Bombail V, Williams AR, Anderson RA, et al. Expression of oestrogen receptors, ERalpha, ERbeta, and ERbeta variants, in endometrial cancers and evidence that prostaglandin F may play a role in regulating expression of ERalpha. *BMC Cancer*. 2009 Sep;9(1):330.



**Fig. 1.** **a** Typical endometriotic glands separated by dense connective tissue (Cesarean section scar). Magnification  $\times 50$ . **b** Endometrial glands of varied size in the direct proximity of the fibrotic capsule. Magnification  $\times 100$ . **c** Glands with atypical endometrial hyperplasia intertwined with glands with normal endometrium. Magnification  $\times 100$ .