

## Transient Constrictive Pericarditis after Coronary Bypass Surgery

JaeBum Kim, M.D.\*, Nam-Hee Park, M.D.\*, Sae-Young Choi, M.D.\*, Hyungseop Kim, M.D.\*\*

Constrictive pericarditis is a rare complication after coronary artery bypass grafting. In most cases pericardiectomy is required as a definitive treatment. However, there are several types of constrictive pericarditis such as transient cardiac constriction. Some types of constrictive pericarditis can only be managed with medical therapy. We report a 72-year-old female patient who developed subacute transient constrictive pericarditis with persistent left pleural effusion as a result of postcardiac injury syndrome. The patient went through coronary bypass surgery that was successfully treated with postoperative steroid therapy.

Key words: 1. Pericardium  
2. Pleural effusion  
3. Coronary artery bypass

### CASE REPORT

Constrictive pericarditis following coronary bypass surgery is a rare complication. Classic constrictive pericarditis after cardiac surgery is considered to be progressive and irreversible, for which definitive therapy is a pericardiectomy [1]. However, there have been recent reports describing a transient form of constrictive pericarditis that resolves without surgical intervention [2,3]. Here we report a patient, who developed transient form of acute constrictive pericarditis four weeks after a CABG procedure that resolved only with steroid therapy.

A 72-year-old woman was referred to our department for a CABG procedure. The patient had a 30-year history of diabetes and was diagnosed with triple vessel disease by coronary angiography. A conventional CABG was performed under cardiopulmonary bypass. A re-exploration was required for bleeding control the same day. The postoperative course was uneventful and the patient was discharged.

Four weeks after the surgery, the patient was re-admitted with complaints of fatigue, exertional dyspnea, and generalized edema. On physical examination, jugular venous distension and hepatomegaly were observed. The chest radiograph showed a massive pleural effusion on the left side and the laboratory tests were within normal limits except for a slight increase in C-reactive protein (3.1 mg/dL).

A pleural drainage was performed with 2,500 mL of hemorrhagic effusion drained. The pleural fluid analysis was exudative with lymphocyte dominance (80%). After removing the drainage catheter, a recurrent pleural effusion was observed despite the treatment with high dose of diuretics. One week later, the pleural catheter was re-inserted and 1,500 mL of serosanguinous fluid was drained. Thereafter, more than 400 cc of pleural fluid was drained everyday and continued for three weeks.

An echocardiography was performed and revealed an abnormal interventricular septal movement, marked respiratory

\*Department of Thoracic and Cardiovascular Surgery, Dongsan Medical Center, College of Medicine, Keimyung University

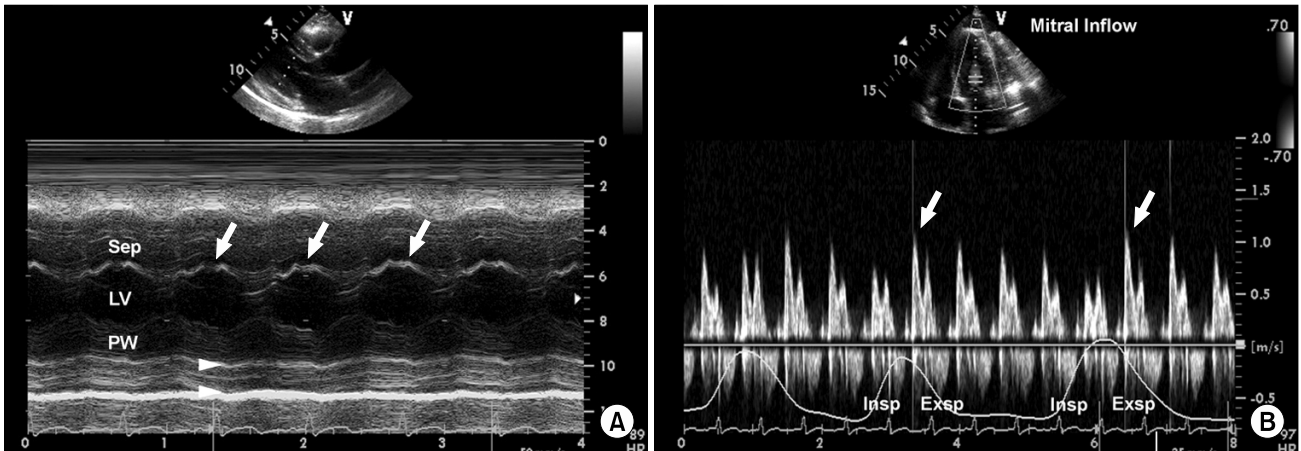
\*\*Department of Internal Medicine, Dongsan Medical Center, College of Medicine, Keimyung University

Received: April 26, 2010, Revised: May 31, 2010, Accepted: June 25, 2010

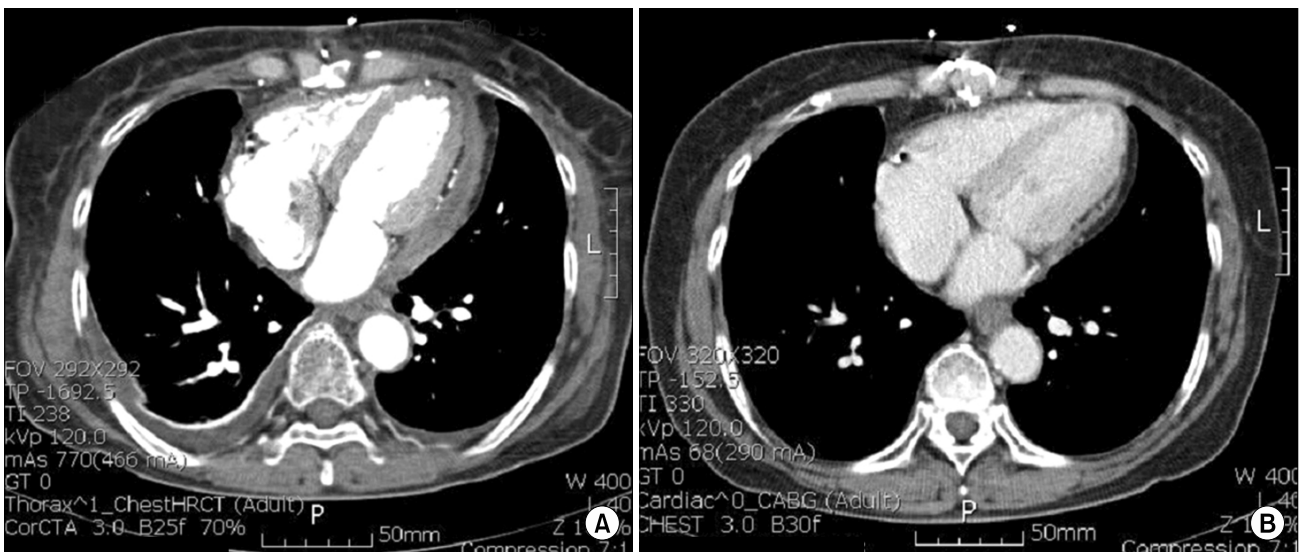
Corresponding author: Nam-Hee Park, Department of Thoracic and Cardiovascular Surgery, College of Medicine, Keimyung University, 194, Dongsan-dong, Joong-gu, Daegu 700-712, Korea  
(Tel) 82-53-250-7025 (Fax) 82-53-250-7307 (E-mail) nhpark@dsmc.or.kr

© The Korean Society for Thoracic and Cardiovascular Surgery. 2011. All right reserved.

© This is an open access article distributed under the terms of the Creative Commons Attribution Non-Commercial License (<http://creativecommons.org/licenses/by-nc/3.0>) which permits unrestricted non-commercial use, distribution, and reproduction in any medium, provided the original work is properly cited.



**Fig. 1.** (A) M-mode echocardiography shows the characteristic findings of septal bouncing (“double components”; arrow) with an increased pericardial thickness (arrowhead). (B) Pulsed wave Doppler recording of a marked respiratory variation of mitral inflow. Mitral inflow velocity is decreased with inspiration. However, with expiration, there is a marked increased mitral inflow (arrow). Sep=Septum; LV=Left ventricle; PW=Posterior wall; Insp=Inspiration; Exsp=Expiration.

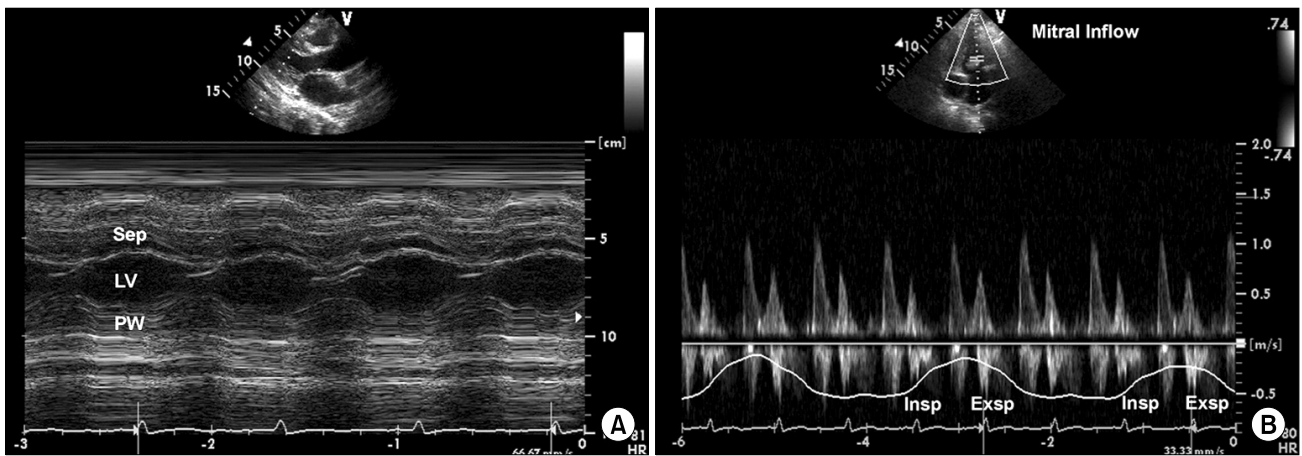


**Fig. 2.** Computed tomography shows the characteristic findings of pericardium. (A) Markedly thickened pericardium, (B) 18 months later follow-up, more thinned pericardium.

changes in the transmitral flow, and a small pericardial effusion with a thickened pericardium (Fig. 1). These findings were not seen on the immediate postoperative echocardiography. The computed tomography examination also showed a markedly thickened pericardium (Fig. 2). These findings were compatible with constrictive pericarditis.

The diagnosis of an acute constrictive pericarditis following a CABG procedure as part of the spectrum of postcardiac in-

jury syndrome (PCIS) was established. Prednisone therapy (5 mg/kg/day) began, continued for 10 days, and progressively tapered over two weeks. The amount of pleural fluid decreased daily and the generalized edema improved. Repeated echocardiography showed no respiratory changes of transmitral inflow and abnormal interventricular septal movement (Fig. 3). The patient was discharged on day 42. During 18 months of follow-up observation, the patient was asympto-



**Fig. 3.** (A) Follow-up echocardiography shows the disappearance of septal bouncing after steroid treatment despite persistent increased pericardial thickness. (B) The respiratory variation of transmitral inflow could not be seen. Sep=Septum; LV=Left ventricle; PW=Posterior wall; Insp=Inspiration; Exsp=Expiration.

matic and computed tomography demonstrated thinner pericardium (Fig. 2).

## DISCUSSION

Dressler's syndrome is largely a self limiting disease that very rarely leads to pericardial tamponade. The syndrome consists of persistent low-grade fever, chest pain (usually pleuritic in nature), pericardial friction rub, and/or pericardial effusion. However, constriction does not proceed from the Dressler's syndrome in general.

Constrictive pericarditis following coronary bypass surgery is an unusual complication with occurrence rate of 0.2~0.3% [4]. Time interval between surgery and development of symptoms varies from 1 to 204 months, and clinical course varies as well. The pathogenesis of constrictive pericarditis after cardiac surgery remains unknown. Once constrictive physiology has developed, it is presumed to be irreversible and pericardiectomy is known as a definitive treatment.

Matsuyama et al. [1] reported clinical characteristics of 11 patients that developed postoperative constrictive pericarditis among a total of 463 CABG patients. Ten patients (91%) had evidence of antecedent pericardial effusion and it was primary risk factor for postoperative constrictive pericarditis. Heidecker and Sahn [5] reported that most patients with constrictive pericarditis that develops after CABG have postcardiac injury

syndrome (PCIS) and persistent PCIS results in pericardial thickening with constriction. Postoperative myocardial antigen may play a role in the development of PCIS and postoperative antimyocardial antibodies have been found in most patients. Postoperative pleural effusions often associate with PCIS and the pleural fluid is characteristically hemorrhagic exudate.

Sagrasta-Sauleda et al. [6] observed a transient form of pericardial constriction that resolved with medical therapy alone. In a review of the cardiac constriction syndrome [7], he suggested that there are several types of constrictive pericarditis. These include classic chronic constrictive pericarditis, subacute constriction including effusive-constrictive pericarditis, transient cardiac constriction, and occult constrictive pericarditis, all of which have their own characteristic natural history. Therefore, spontaneous regression appears to be possible in some forms of constrictive pericarditis, particularly those that appear during the resolution of acute idiopathic pericarditis with effusion or that develop after cardiac surgery.

Haley et al. [2] reported 36 patients with transient constrictive pericarditis and concluded that a subset of patients with constrictive pericarditis cured without pericardiectomy. They emphasized that all of their patients were diagnosed during the acute phase of their illness. They also said that their results may not apply to patients with symptoms for a

long duration.

Our patient showed acute form of constrictive pericarditis with persistent left pleural effusion and pleural fluid was hemorrhagic exudate with lymphocytes dominance. Since we routinely leave the pericardium and left mediastinal pleura open, we believed that pleural fluid was originated from pericardial fluid as a result of effusive pericarditis. Because PCIS was seemed to be the cause of acute constrictive pericarditis and the patient was in acute phase of the disease, we tried the anti-inflammatory drug therapy prior to the pericardiectomy. Medical therapy such as corticosteroids has been effective in reversing pericardial constriction only in some cases when it is given within the first 2 months of the original surgery [8]. Therefore, we used prednisone as a first line of anti-inflammatory treatment and successfully treated without recurrence. In conclusion, transient constrictive pericarditis in acute phase can be managed with a trial of medical therapy in acute phase of constrictive pericarditis.

## REFERENCES

1. Matsuyama K, Matsumoto M, Sugita T, et al. *Clinical characteristics of patients with constrictive pericarditis after coronary bypass surgery*. Jpn Circ J 2001;65:480-2.
2. Haley JH, Tajik AJ, Danielson GK, Schaff HV, Mulvagh SL, Oh JK. *Transient constrictive pericarditis; causes and natural history*. J Am Coll Cardiol 2004;43:271-5.
3. Blasco PB, Comas JG, Ferrer JC, Menduña QF, García BM, Ipiña FG. *Transient postoperative pericardial constriction in a child*. Int J Cardiol 2009;131:e45-7.
4. Fowler NO. *Constrictive pericarditis: Its history and current status*. Clin Cardiol 1995;18:341-50.
5. Heidecker J, Sahn SA. *The spectrum of pleural effusions after coronary artery bypass grafting surgery*. Clin Chest Med 2006;27:267-83.
6. Sagrista-Sauleda J, Permanyer-Miralda G, Candell-Riera J, Angel J, Soler-Soler J. *Transient cardiac constriction: an unrecognized pattern of evolution in effusive acute idiopathic pericarditis*. Am J Cardiol 1987;59:961-6.
7. Sagrista-Sauleda J. *Cardiac constriction syndromes*. Rev Esp Cardiol 2008;61(Suppl 2):33-40.
8. Ansinelli RA, Weeks KD, Key TS. *Effects of steroids on postoperative constrictive pericarditis*. Am J Cardiol 1983; 51:1238-40.