

Prenatal Diagnosis of Fetal Congenital Mesoblastic Nephroma and Neonatal Follow-up

CME Credits

Li-Chan Lin¹, Yueh-Chin Cheng², Chiung-Hsin Chang^{2*}¹Department of Obstetrics and Gynecology, Cathay General Hospital, Taipei, Taiwan, ²Department of Obstetrics and Gynecology, National Cheng Kung University Hospital and College of Medicine, Tainan, Taiwan

Abstract

We describe a case of fetal congenital mesoblastic nephroma (CMN) who was diagnosed with ultrasound at 32 weeks of gestation; after delivery, the neonate received left radical nephrectomy, and pathology report confirmed the diagnosis. All cross-sectional imaging studies, such as ultrasonography, computed tomography (CT) scanning, and magnetic resonance imaging, may help to define the organ of origin and the relationship to the ipsilateral kidney. To our knowledge, this is the first case of fetal CMN who was diagnosed in the third trimester and then with a live-born baby in Taiwan. The prenatal examination such as three-dimensional ultrasound and CT image was performed to help us for prenatal diagnosis.

Keywords: Congenital mesoblastic nephroma, prenatal diagnosis, computed tomography

INTRODUCTION

Neonatal tumors occur every 12,500–27,500 live births and account for 2% of child malignancies.^[1] There are several pediatric renal tumors and masses should be differentiated, for example, Wilms' tumor, mesoblastic nephroma, nephroblastomatosis, and multilocular cystic renal tumor.^[2] Congenital mesoblastic nephroma (CMN) is the primary consideration in a neonate with solid renal mass. It is the most common renal tumor identified in the neonatal period and the most frequent benign renal tumor in childhood.^[3] CMN represents 3%–10% of all pediatric renal tumors. Here, we report a case of fetal CMN diagnosed by prenatal ultrasound and neonatal follow-up for further treatment. To our knowledge, this is the first case of fetal CMN who had prenatal diagnosis in the third trimester and then with a live-born baby in Taiwan.

CASE REPORT

The mother was a 31-year-old female, primigravida. The prenatal care was regular, and the prenatal examinations were all within normal limits. The prenatal ultrasound at 32 weeks of gestation showed one well-circumscribed, solid, and low-level

homogeneous echoes mass with abundant flow in the left kidney, measuring 6.0 cm × 5.8 cm × 5.2 cm in size [Figure 1], associated with polyhydramnios (amniotic fluid index was about 33.4 cm). CMN was highly suspected. According to uterine distension and premature uterine contraction, cesarean section was performed at 32 weeks of gestation. A premature male baby, 1 min Apgar scores 7 followed by 5 min Apgar scores 9, birth weight 1802 g, was delivered. The computed tomography (CT) was performed and revealed left renal heterogeneous tumor, 5.2 cm × 5.1 cm × 5.8 cm in size [Figure 2] on the 2nd day after birth. Seven days after birth, the neonate underwent left radical nephrectomy. One tumor mass (6.2 cm × 5.7 cm × 5.0 cm, 89 g) with tissue of the kidney (2.4 cm × 1.5 cm × 5.0 cm) seen at the peripheral of the tumor. The tumor is yellow to tan in color and is homogeneous, without necrosis, hemorrhage, or calcification [Figure 3]. The sections showed a classic-type CMN composed of fibroblastic cells. The neonate recovered gradually and discharged under stable condition 3 weeks later.

Address for correspondence: Prof. Chiung-Hsin Chang, Department of Obstetrics and Gynecology, National Cheng Kung University Hospital, No. 138, Sheng-Li Road, Tainan 70428, Taiwan. E-mail: ahsin@mail.ncku.edu.tw

Received: 20-05-2020 Revised: 03-07-2020 Accepted: 03-07-2020 Available Online: 01-10-2020

Access this article online

Quick Response Code:



Website:
www.jmuonline.org

DOI:
10.4103/JMU.JMU_79_20

This is an open access journal, and articles are distributed under the terms of the Creative Commons Attribution-NonCommercial-ShareAlike 4.0 License, which allows others to remix, tweak, and build upon the work non-commercially, as long as appropriate credit is given and the new creations are licensed under the identical terms.

For reprints contact: WKHLRPMedknow_reprints@wolterskluwer.com

How to cite this article: Lin LC, Cheng YC, Chang CH. Prenatal diagnosis of fetal congenital mesoblastic nephroma and neonatal follow-up. J Med Ultrasound 2021;29:126-8.

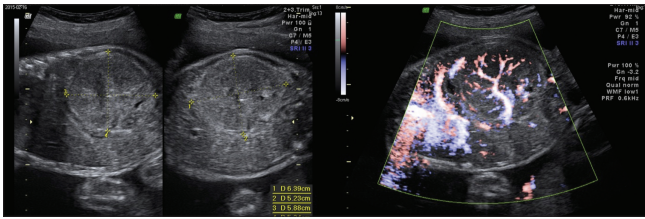


Figure 1: The prenatal ultrasound at 32 weeks of gestation showed one well-circumscribed, solid, and low-level homogeneous echoes mass with abundant flow in the left kidney, measuring 6.0 cm × 5.8 cm × 5.2 cm in size, associated with polyhydramnios

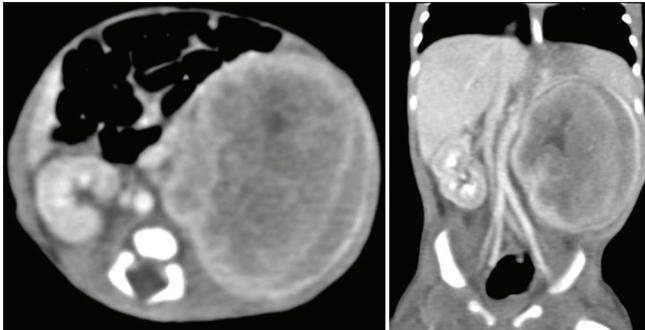


Figure 2: The computed tomography revealed left renal heterogeneous tumor, 5.2 cm × 5.1 cm × 5.8 cm, involving the upper and middle poles showing perirenal fluid collection and enhanced Gerota's fascia

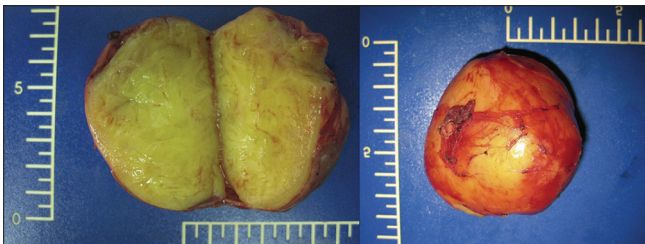


Figure 3: The tumor is yellow to tan in color and is homogeneous, no necrosis, hemorrhage, or calcification

DISCUSSION

Nearly two-thirds of infantile or fetal abdominal masses are renal origin.^[4] Most of them are benign and related to hydronephrosis and multicystic dysplasia. Congenital renal tumors are rare, comprising 2.5%–7% of all perinatal tumors. CMN arises from renal mesenchyma and is usually benign. It comprises <5% of all pediatric renal tumors. CMN is almost always unilateral and is rarely malignant. The clinical features of CMN in the perinatal period include polyhydramnios, hematuria, anemia, hypertension, hypercalcemia, and elevated renin levels. The CMN predominates in boys with a male: female ratio of about 2:1.^[5] In our case, polyuria and hypertension and hypercalcemia were all noted after birth.

Polyhydramnios accompanies about 70% of cases and contributes to high rates (25%) of premature delivery. The increased amniotic fluid may be attributed to increased urine production due to renal hyperperfusion, decreased gastrointestinal absorption due to bowel compression, or tumor

secretion of prostaglandins leading to hypercalcemia-induced polyuria.^[6]

The differential diagnosis includes CMN, Wilms' tumor, rhabdoid tumor, clear cell sarcoma, and hamartomas. To detect early, the mass may be first diagnosed when the detailed fetal anatomy scan is performed at 18–20 weeks of gestation. In general, it is a well-defined mass with low-level homogeneous echoes. The presence of concentric echogenic and hypoechoic rings can be a helpful diagnostic feature in the classic subtype but may also be seen in the cellular subtype. A more complex pattern due to hemorrhage, cyst formation, and necrosis can also be seen and tends to favor the cellular variant. Color Doppler interrogation may show increased vascularity. Uncommonly, the tumor may appear predominantly cystic.^[7] If the mass is very large, it may be difficult to determine the organ of origin in some cases. Fetal magnetic resonance imaging (MRI) may be helpful in determining the organ of origin because of excellent soft-tissue detail on MRI and the ability to image in multiple planes. All cross-sectional imaging studies, such as ultrasonography, CT scanning, and MRI, may help to define the organ of origin and the relationship to the ipsilateral kidney. However, MRI is the most accurate imaging modality, as it most accurately depicts the local and regional extent of the tumor.^[8]

In conclusion, we presented a case who was diagnosed with CMN under prenatal ultrasound examination. The clinical feature of the mother includes polyhydramnios, uterine distension, and premature uterine contraction. For more detailed diagnosis, fetal MRI should be done for more information gathered and will allow the obstetrician to make a more precise diagnosis and provide proper management. Fortunately, the neonate got accurate prenatal diagnosis immediately and timely delivery. The final pathology report also confirmed our diagnosis, and the neonate's outcome was also good.

Declaration of patient consent

The authors certify that they have obtained all appropriate patient consent forms. In the form the patient has given her consent for her images and other clinical information to be reported in the journal. The patient understands that her name and initials will not be published and due efforts will be made to conceal identity, but anonymity cannot be guaranteed.

Financial support and sponsorship

Nil.

Conflicts of interest

Dr. Chiung-Hsin Chang, an Editor at *Journal of Medical Ultrasound*, had no role in the peer review process of or decision to publish this article. The other authors declared no conflicts of interest in writing this paper.

REFERENCES

1. Moore SW, Satgé D, Sasco AJ, Zimmermann A, Plaschkes J. The epidemiology of neonatal tumours. Report of an international working

- group. *Pediatr Surg Int* 2003;19:509-19.
2. Esmer AC, Kalelioglu I, Kilicaslan I, Gun F, Ziylan O. Prenatal sonographic diagnosis of multicystic congenital mesoblastic nephroma. *J Clin Ultrasound* 2013;41 (Suppl 1):59-61.
 3. Fuchs IB, Henrich W, Brauer M, Stöver B, Guschmann M, Degenhardt P, *et al.* Prenatal diagnosis of congenital mesoblastic nephroma in 2 siblings. *J Ultrasound Med* 2003;22:823-7.
 4. Glick RD, Hicks MJ, Nuchtern JG, Wesson DE, Olutoye OO, Cass DL. Renal tumors in infants less than 6 months of age. *J Pediatr Surg* 2004;39:522-5.
 5. Furtwaengler R, Reinhard H, Leuschner I, Schenk JP, Goebel U, Claviez A, *et al.* Mesoblastic nephroma--a report from the gesellschaft für pädiatrische onkologie und hämatologie (GPOH). *Cancer* 2006;106:2275-83.
 6. Maymon R, Strauss S, Herman A, Wiener Y, Heyman E, Goldman M. The prenatal scan pitfall for the diagnosis of renal mass: Case report. *Prenat Diagn* 2004;24:932-4.
 7. Chung EM, Graeber AR, Conran RM. Renal tumors of childhood: Radiologic-pathologic correlation part 1. The 1st decade: from the radiologic pathology archives. *Radiographics* 2016;36:499-522.
 8. Chen WY, Lin CN, Chao CS, Yan-Sheng Lin M, Mak CW, Chuang SS, *et al.* Prenatal diagnosis of congenital mesoblastic nephroma in mid-second trimester by sonography and magnetic resonance imaging. *Prenat Diagn* 2003;23:927-31.