

Painful left bundle branch block syndrome treated successfully with permanent His bundle pacing



Prakash G. Suryanarayana, MD, David S. Frankel, MD, FHRS,
Francis E. Marchlinski, MD, FHRS, Robert D. Schaller, DO, FHRS

From the Section of Cardiac Electrophysiology, Cardiovascular Division, Department of Medicine, Hospital of the University of Pennsylvania, Philadelphia, Pennsylvania.

Introduction

Chest pain associated with the development of left bundle branch block (LBBB) that is unrelated to coronary ischemia has been recognized as “painful LBBB syndrome.”^{1,2} Specific LBBB patterns associated with this syndrome have been identified,² but its true prevalence in the general population is unknown owing to coexisting coronary artery disease (CAD) and lack of widespread awareness of such a clinical entity. This syndrome can cause disabling symptoms with significant activity limitation. The proposed mechanisms include dyssynchronous systolic motion of the septum and generalized interoceptive sensitivity.^{2,3}

Treatment options, which include submaximal exercise regimens, β -blockers, and right ventricular (RV) and biventricular pacing, have yielded only modest success.² Permanent His bundle pacing (HBP) has recently gained popularity, as emerging data have shown decreased rates of heart failure compared to traditional RV pacing as well as reversal of dyssynchrony-induced cardiomyopathy. Reestablishing normal physiologic conduction and avoiding electrical dyssynchrony by way of direct His bundle activation is possible owing to the proximal and focal nature of lesions causing intra- or infra-Hisian conduction abnormalities within longitudinally dissociated, predestined Purkinje fibers.^{4–8} In this way, HBP represents an appealing strategy for the treatment of painful LBBB syndrome and has yet to be reported.

Case report

A 62-year-old man with a past medical history significant for hypertension, typical right atrial flutter status post

KEYWORDS Aberrancy; Conduction system; Dyssynchrony; Painful left bundle branch block syndrome; Pacing; Permanent His bundle pacing; Resynchronization

(Heart Rhythm Case Reports 2018;4:439–443)

This work was supported in part by the F. Harlan Batrus Research Fund. Drs Schaller and Marchlinski receive lecture honoraria from and Dr Marchlinski is a consultant for Medtronic. **Address reprint requests and correspondence:** Dr Robert D. Schaller, Hospital of the University of Pennsylvania, 9 Founders Pavilion – Cardiology, 3400 Spruce St, Philadelphia, PA 19104. E-mail address: robert.schaller@uphs.upenn.edu.

radiofrequency ablation, and CAD status post percutaneous coronary intervention 5 years prior presented with 4 years of crushing chest pain and progressive shortness of breath upon minimal exertion. Repeat left heart catheterization showed no new obstructive lesions, and treatment for presumed coronary vasospasm with calcium channel blockers and vasodilators proved ineffective. Previous exercise stress testing and ambulatory monitoring showed rate-dependent LBBB with heart rates above 110 beats per minute (bpm) but more recently above only 90 bpm. LBBB corresponded immediately with symptom onset and resolution of aberrancy instantly provided relief, confirming the diagnosis of painful LBBB syndrome.

An electrophysiology (EP) study was performed with only local anesthetic given at the femoral access points, and the patient was blinded to the surface 12-lead electrocardiogram. Baseline AH and HV intervals were 110 ms and 54 ms, respectively. LBBB with a prolonged HV interval of 75 ms occurred intermittently with right atrial pacing rates above 85 bpm and correlated completely with symptoms (Figure 1). LBBB persisted with pacing rates above 90 bpm and resolved upon cessation of pacing. RV pacing along the mid septum manifesting as LBBB-type aberrancy produced similar symptoms. Attempts at para-Hisian pacing resulted in rare and intermittent engagement of the His-Purkinje system, which was insufficient to allow the opportunity to assess for resolution of symptoms. With confirmation of painful LBBB syndrome, attention was then turned to implantation of a dual-chamber pacemaker utilizing permanent HBP.

A 7F hemostatic peel-away sheath (SafeSheath, Pressure Products, San Pedro, CA) was introduced into the left axillary vein; through it, a nondeflectable 7F sheath (C315, Medtronic, Minneapolis, MN) was placed. A 4.1F bipolar, steroid-eluting, nonretractable screw-in lead (Select Secure 3830, Medtronic, Minneapolis, MN) was placed within the C315 sheath and advanced to the location of the His bundle. After a His deflection was noted, the lead was screwed into the myocardium and a His bundle injury current was seen with ventricular sensing of 1.5 mV. Bipolar threshold testing resulted in painless nonselective His bundle capture with a QRS width of 108 ms (Figure 2A), impedance of 550 ohms,

KEY TEACHING POINTS

- Painful left bundle branch block syndrome is an underappreciated disorder that results from mechanical dyssynchrony in the absence of myocardial ischemia.
- There has been no universally accepted treatment for this condition.
- Permanent His bundle pacing is an appealing and effective treatment strategy owing to the restoration of normal cardiac physiology.

and a His bundle capture threshold of 2.5 V @ 1 ms. Further decrease in output resulted in loss of His capture and exclusive RV capture with immediate onset of pain (Figure 2A). Of note, right bundle branch block (RBBB), which did not result in pain, developed at this point and persisted throughout the case (Figure 2B). Dual-chamber pacemaker implantation was completed. The postoperative radiograph is displayed in Supplemental Figure 1.

Postoperative lead testing remained unchanged with persistent and painless RBBB conduction and inability to induce LBBB at any atrial pacing rate. Because of this, the pacemaker was programmed to a long AV delay so as to encourage conduction with RBBB.

Within 1 week of discharge, the patient's symptoms returned and it was noted that the RBBB had resolved and

LBBB was once again present at rates above 90 bpm. Interestingly, ventricular capture above 2.5 V @ 1 ms now resulted in painless *selective* HBP (S-HBP) with a narrow QRS, and capture below 2.5 V @ 1 ms resulted in painful S-HBP without correction of the LBBB (Figure 3). Identical responses were demonstrated with both dual-chamber and ventricular-only pacing configurations. Utilizing a rate-adaptive AV delay feature to preserve battery longevity, the pacemaker was programmed to a longer AV delay at rates below 70 bpm to encourage narrow ventricular conduction and a shorter AV delay at rates above 70 bpm in order to employ HBP. The patient remains pain-free during follow-up.

Discussion

LBBB is known to be associated with hypertension, CAD, and cardiomyopathy,⁹ but "painful left bundle branch block syndrome" is a less recognized entity. Shvilkin and colleagues² reported the largest series of 50 patients, of which 46 were from the published literature, and describe a signature LBBB pattern characterized by a low S/T wave ratio (mean 1.47 ± 0.16) at the onset of painful LBBB.

In our patient, diagnosis of this condition was delayed by 4 years, likely owing to an underlying history of CAD and lack of awareness of this clinical entity. He experienced a gradual decrease in the heart rate at which rate-related LBBB occurred over the 4-year period, in keeping with a previously published report.¹⁰ The exact mechanism of chest pain and dyspnea has not been well elucidated, but altered ventricular activation pattern as observed by kinetography³ and cardiac

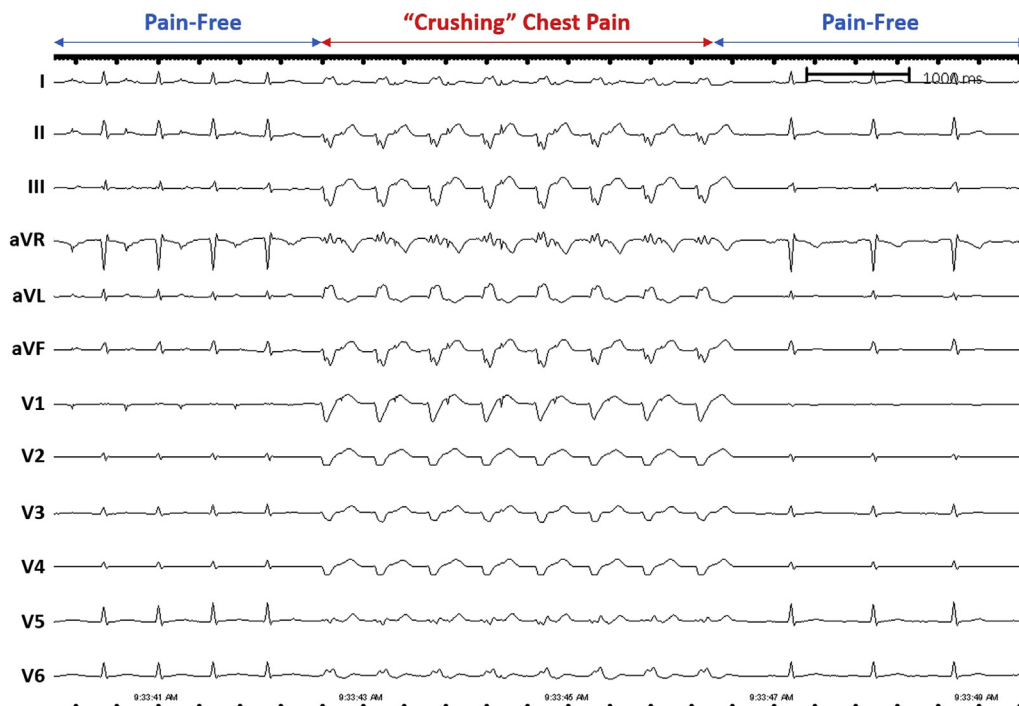


Figure 1 Right atrial pacing at a rate of 85 beats per minute with a narrow QRS and no pain with eventual transition to left bundle branch block and immediate symptom onset. Upon cessation of pacing and aberrancy resolution, the pain subsided.

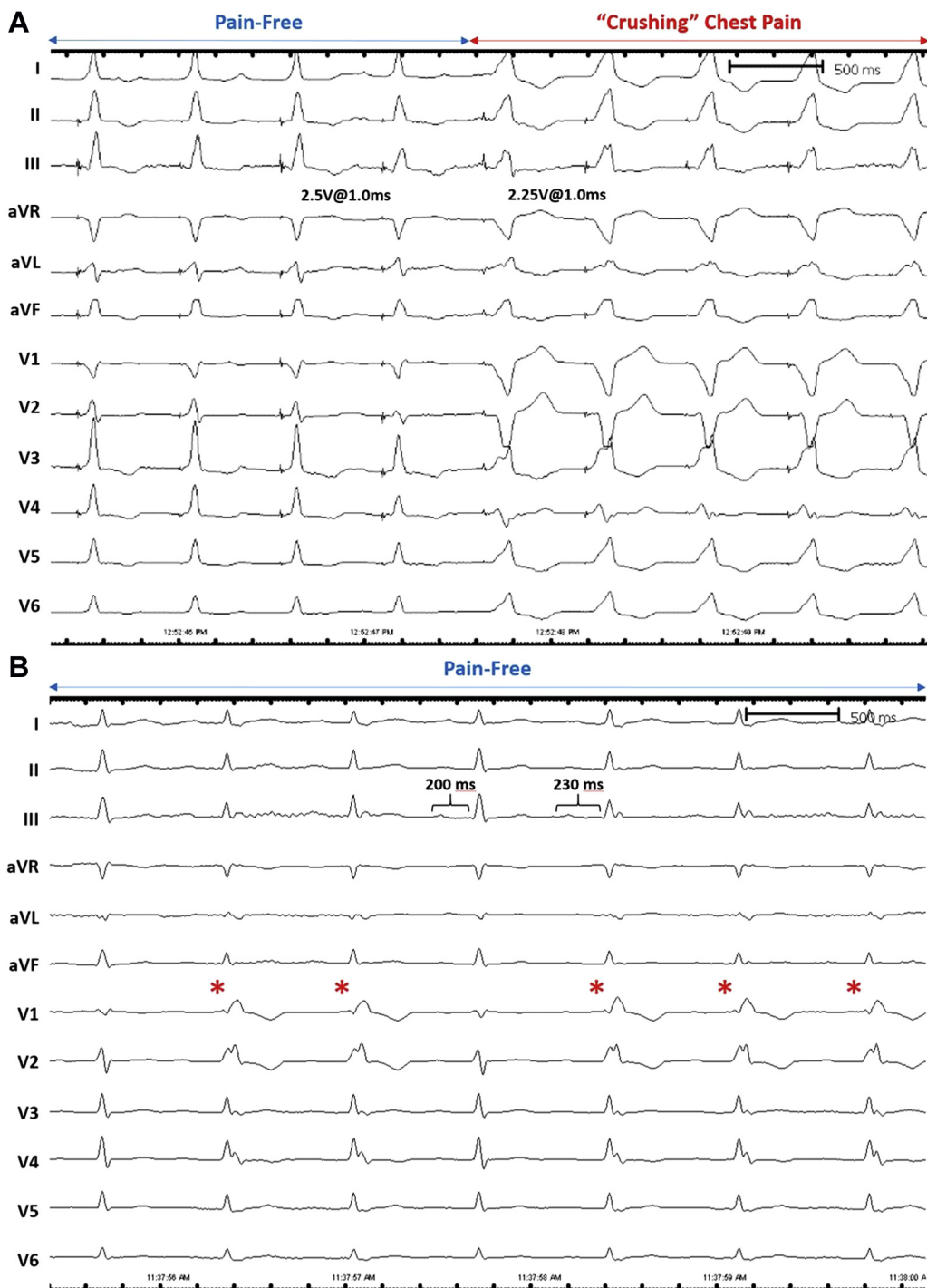


Figure 2 **A:** Nonselective His bundle pacing with an output of 2.5V @ 1.0 ms resulting in a narrow QRS of 108 ms and no pain. When the pacing output is decreased to 2.25 V @ 1.0ms, loss of His bundle capture occurs, the QRS widens, and pain is reported. **B:** Normal sinus rhythm with native ventricular conduction and development of persistent right bundle branch block (*asterisks*) after deployment of the His bundle pacing lead. Note that the PR interval increases from 200 ms to 230 ms with the onset of aberrant ventricular conduction, suggesting delay in the left bundle branch.

magnetic resonance imaging¹¹ in combination with increased generalized interoceptive awareness have been postulated as possible mechanisms.²

Thus far, no single therapy has been proven to be effective. Exercise training to achieve a higher threshold of LBBB onset/offset,¹² β -blockers, and pacemaker implantation utilizing targeted and patient-specific pacing sites all have limitations.

Sharma and colleagues¹³ recently published their findings concerning the role of permanent HBP in circumventing the intra-Hisian delay that leads to LBBB. Restoration of normal conduction physiology with HBP is an ideal solution to a syndrome caused by electrical dyssynchrony and completely resolved our patient's symptoms. Importantly, it was unnecessary to achieve selective His bundle capture for complete

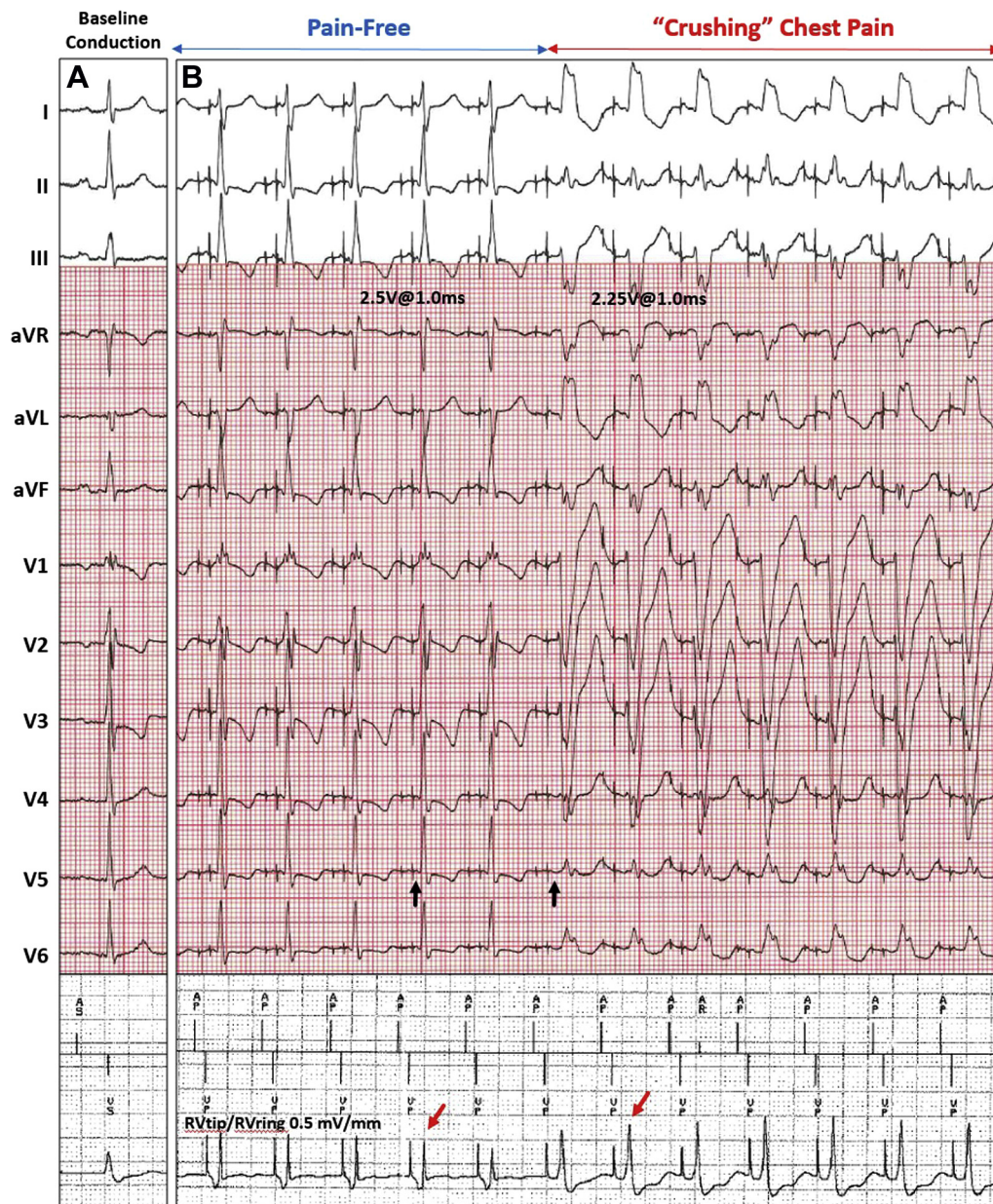

Figure 3 A: Baseline native QRS, which is narrow. B: Pacing at 2.5 V @ 1 ms results in selective His bundle pacing (HBP) with left bundle branch block (LBBB) correction, as evidenced by an initial isoelectric interval (black arrows) and a similar QRS morphology on 12-lead electrocardiogram. Note that there are subtle ventricular repolarization changes owing to a faster pacing rate. Pacing at 2.25 V @ 1 ms also results in selective HBP without LBBB correction and chest pain ensues. Identical responses were seen during both dual-chamber and ventricular-only pacing configurations. The selective nature of both manifestations is confirmed by a discrete local ventricular electrogram, as seen on the pacing lead (red arrows).

resolution of symptoms. By definition, nonselective His bundle pacing results in activation of the His bundle as well as the local RV myocardium to different degrees. The narrow QRS complex and output-dependent pacing morphology in this case suggests that the normal conduction system is being activated early on and is responsible for activation of the lateral left ventricular (LV) wall, consistent with prior work.¹⁴

Interestingly, our patient developed RBBB during lead fixation in the context of His bundle current of injury. Vijayaraman and colleagues¹⁵ have previously reported that chronic RBBB can occur in this context and only when a

His bundle current of injury is seen. Maintenance of RBBB and failure to see complete heart block at higher pacing rates suggests that the patient's rate-related LBBB was not "block" but, in fact, delay within the left bundle branch. This is consistent with the increase in PR interval seen during transition from narrow QRS to RBBB (Figure 2B). Of note, the patient did not have any symptoms with RBBB morphology at any rate owing to a lack of LV dyssynchrony. Accepting RBBB with back-up ventricular pacing proved a successful treatment strategy until the RBBB resolved and rate-related LBBB once again ensued. Forced S-HBP at all rates above 70 bpm utilizing a rate-adaptive AV delay pacing feature in

an effort to enhance battery longevity has resulted in complete suppression of the patient's symptoms. Vigilant follow-up remains crucial, as progression of LBBB to lower rates or development of complete heart block will require HBP at a fixed, shorter AV delay.

To our knowledge, this is the first time that permanent HBP has been utilized to treat painful LBBB syndrome. HBP remains an attractive and predictable option that should be considered when treating this syndrome. LV pacing by way of the coronary sinus system also appears to be a theoretical therapeutic option and requires further study. EP study with diagnostic confirmation as well as attempts at para-Hisian pacing to confirm efficacy are reasonable first steps. Exercise training may have an adjunctive role in increasing the threshold at which rate-related LBBB develops, thereby providing protection over and above the maximum tracking rate set by the pacemaker.

Conclusion

"Painful LBBB syndrome" is a rare and often unrecognized condition. Abrupt onset and offset of symptoms with transient development of LBBB should lead to a high index of clinical suspicion. Confirmatory EP testing should be performed, followed by consideration of permanent HBP as first-line therapy.

Appendix

Supplementary data

Supplementary data associated with this article can be found in the online version at <https://doi.org/10.1016/j.hrcr.2018.08.005>.

References

1. Loubeyre C, Tison E, Neuville C, Degroote P, Ducloux G. Painful left bundle-branch block during exertion. *Ann Cardiol Angeiol (Paris)* 1991;40:613–617.

2. Shvilkin A, Ellis ER, Gervino EV, Litvak AD, Buxton AE, Josephson ME. Painful left bundle branch block syndrome: Clinical and electrocardiographic features and further directions for evaluation and treatment. *Heart Rhythm* 2016;13:226–232.
3. Virtanen KS, Heikkilä J, Kala R, Siltanen P. Chest pain and rate-dependent left bundle branch block in patients with normal coronary arteriograms. *Chest* 1982;81:326–331.
4. Abdelrahman M, Subzposh FA, Beer D, Durr B, Naperkowski A, Sun H, Oren JW, Dandamudi G, Vijayaraman P. Clinical outcomes of His bundle pacing compared to right ventricular pacing. *J Am Coll Cardiol* 2018;71:2319–2330.
5. Sharma PS, Dandamudi G, Herweg B, Wilson D, Singh R, Naperkowski A, Koneru JN, Ellenbogen KA, Vijayaraman P. Permanent His-bundle pacing as an alternative to biventricular pacing for cardiac resynchronization therapy: A multicenter experience. *Heart Rhythm* 2018;15:413–420.
6. James TN, Sherf L. Fine structure of the His bundle. *Circulation* 1971;44:9–28.
7. El-Sherif N, Amay YLF, Schonfield C, Scherlag BJ, Rosen K, Lazzara R, Wyndham C. Normalization of bundle branch block patterns by distal His bundle pacing. Clinical and experimental evidence of longitudinal dissociation in the pathologic his bundle. *Circulation* 1978;57:473–483.
8. Teng AE, Lustgarten DL, Vijayaraman P, Tung R, Shivkumar K, Rabkin SW, Ajjola OA. Usefulness of His bundle pacing to achieve electrical resynchronization in patients with complete left bundle branch block and the relation between native QRS axis, duration, and normalization. *Am J Cardiol* 2016;118:527–534.
9. Rabkin SW, Mathewson FA, Tate RB. Natural history of left bundle-branch block. *Br Heart J* 1980;43:164–169.
10. Hertzzeanu H, Aron L, Shiner RJ, Kellermann J. Exercise dependent complete left bundle branch block. *Eur Heart J* 1992;13:1447–1451.
11. Jackson T, Sohal M, Chen Z, Child N, Sammut E, Behar J, Claridge S, Carr-White G, Razavi R, Rinaldi CA. A U-shaped type II contraction pattern in patients with strict left bundle branch block predicts super-response to cardiac resynchronization therapy. *Heart Rhythm* 2014;11:1790–1797.
12. Heinsimer JA, Skelton TN, Califf RM. Rate-related left bundle branch block with chest pain and normal coronary arteriograms treated by exercise training. *Am J Med Sci* 1986;292:317–319.
13. Sharma PS, Ellison K, Patel HN, Trohman RG. Overcoming left bundle branch block by permanent His bundle pacing: Evidence of longitudinal dissociation in the His via recordings from a permanent pacing lead. *HeartRhythm Case Rep* 2017;3:499–502.
14. Vijayaraman P, Dandamudi G, Zanon F, Sharma PS, Tung R, Huang W, Koneru J, Tada H, Ellenbogen KA, Lustgarten DL. Permanent His bundle pacing: Recommendations from a Multicenter His Bundle Pacing Collaborative Working Group for standardization of definitions, implant measurements, and follow-up. *Heart Rhythm* 2018;15:460–468.
15. Vijayaraman P, Dandamudi G, Ellenbogen KA. Electrophysiological observations of acute His bundle injury during permanent His bundle pacing. *J Electrocardiol* 2016;49:664–669.