



## Case report

# A case report of prepubescent idiopathic gigantomastia with pseudoangiomatous stromal hyperplasia

Rachael Johnson<sup>\*</sup>, Richard Haywood

Queen Elizabeth Hospital, Gayton Road, King's Lynn, Norfolk PE30 4ET, United Kingdom of Great Britain and Northern Ireland

## ARTICLE INFO

## Keywords:

Gigantomastia  
Pseudoangiomatous  
Stromal  
Hyperplasia  
Case report

## ABSTRACT

**Introduction:** This is an interesting case of a prepubescent female diagnosed and treated for gigantomastia, of unknown cause.

**Presentation of case:** Gigantomastia treated with surgical intervention with the final pathology being that of Pseudoangiomatous stromal hyperplasia.

**Discussion:** Hormonal manipulation, as a treatment, was considered before surgical intervention. It was discarded as deemed, in accordance to published cases, to be slow and inconsistent and would not allow the breast tissue to regress.

**Conclusion:** We describe our approach and successful surgical management, in such an unusual case, to add our experience to the limited reporting in the literature.

## 1. Introduction

Gigantomastia is a rare, benign condition in which the breasts undergo an excessive increase in size. It is most commonly pubertal or gestational, likely due to the massive hormonal fluctuations experienced during these periods [1,2] although, several cases of idiopathic gigantomastia have been published [3]. It is debilitating both physically and psychologically, causing pain, skin ulceration, loss of physical ability and social stigma [4,5].

Pseudoangiomatous stromal hyperplasia (PASH) is a proliferative benign breast condition [6] which is often an incidental microscopic finding on breast biopsy. However, it can be mass forming and is likely to be hormone sensitive as it expresses both oestrogen and progesterone receptors [7]. PASH typically occurs in pre-menopausal women and is rare in prepubescence or in association with gigantomastia [8].

## 2. Case presentation

This is the first case report of a prepubertal white British female developing idiopathic gigantomastia with associated PASH. This work has been reported in line with the SCARE 2020 criteria [9].

A prepubescent 13-year-old with a normal BMI of 19–20 (61.8 kg) presented with 6 months of rapid breast growth from a B cup to an unmeasurable size (Fig. 1). Her quality of life was grossly controlled by

the exceptional breast growth, being unable to undertake any significant activity such as standing for any length of time or walking without supporting the breast tissue. There was associated skin breakdown and infection due to tightness of the skin and the disproportionate blood supply to the breast tissue itself with prominent engorged veins to the chest wall (Fig. 2). Her hormonal profile (to include follicular stimulating hormone (FSH), luteinising hormone (LH), progesterone, thyroid function (TFTs), oestradiol, prolactin and growth hormone (GH)) was normal. An ultrasound scan of the breast tissue demonstrated diffusely hypochoic appearances and oedematous changes. A bilateral reduction mammoplasty, using the typical wise pattern technique, was conducted, by an experienced Consultant in Plastic Surgery, with removal of the nipple areolar complexes which were involved in the skin changes (Fig. 3). In total, 8.4 kg was removed with the histology described as gynaecomastoid usual hyperplasia and florid PASH (Fig. 4). The conclusion was that the appearances were in keeping with juvenile macromastia. It has now been six months since the reduction surgery and there has not been any evidence of re-growth of the breast tissue, thus obtaining an acceptable cosmetic outcome (Fig. 5). She has subsequently been assessed by clinical psychology and is considered to be well-adjusted since her surgery.

<sup>\*</sup> Corresponding author.

E-mail address: [Rachael.johnson@qehkl.nhs.uk](mailto:Rachael.johnson@qehkl.nhs.uk) (R. Johnson).

<https://doi.org/10.1016/j.ijscr.2022.107793>

Received 21 September 2022; Received in revised form 13 October 2022; Accepted 20 November 2022

Available online 21 November 2022

2210-2612/© 2022 The Authors. Published by Elsevier Ltd on behalf of IJS Publishing Group Ltd. This is an open access article under the CC BY-NC-ND license (<http://creativecommons.org/licenses/by-nc-nd/4.0/>).

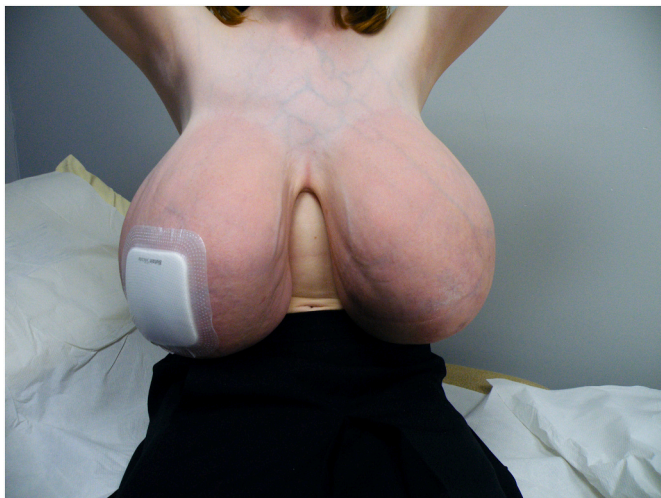

Fig. 1. Presentation of gigantomastia.

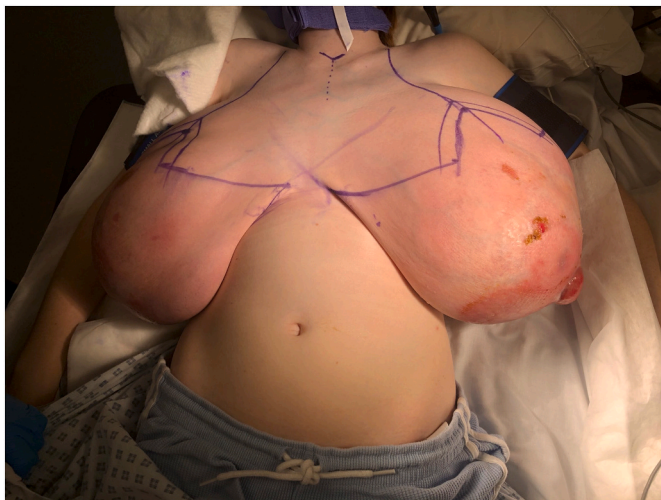

Fig. 2. Intra-operative surgical marking for a wise-pattern reduction mammoplasty.

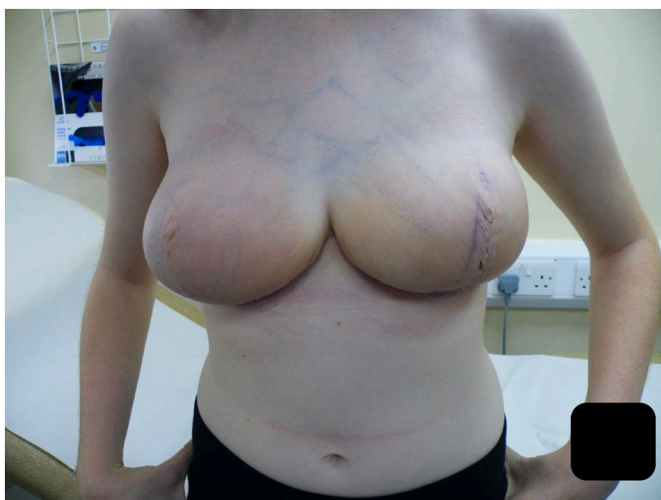

Fig. 3. 2 weeks post-operation.

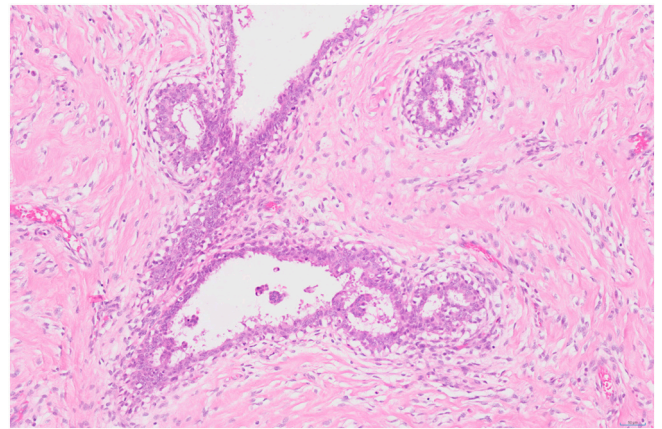


Fig. 4. Representative image of a duct space showing gynaecomastia-like usual type hyperplasia with finger-like tapered projections and prominent pseudo-angiomatic stromal hyperplasia in the surrounding stroma.

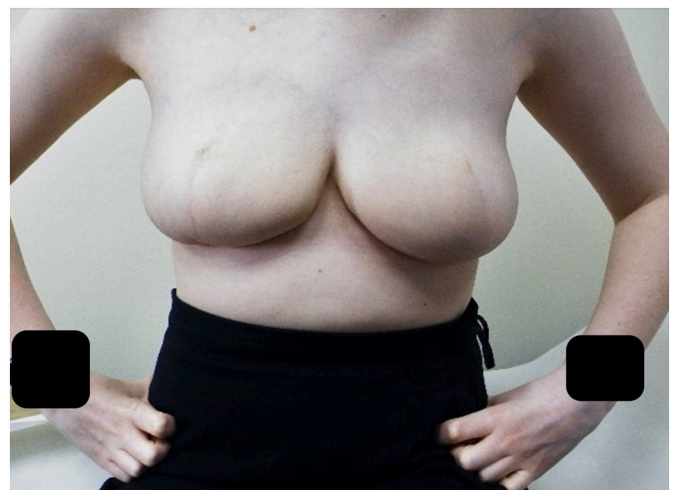


Fig. 5. 6 months post-operation.

### 3. Discussion

It is uncommon for gigantomastia to develop during prepubescence, and it is most likely that the patient was on the cusp of puberty with vast hormonal fluctuations during the breast growth. Due to this being a rare condition, there was a regional MDT approach to include Plastic and Breast consultant surgeons, a Professor of Endocrinology, a Paediatric consultant and a Clinical Psychologist. The option of hormonal blockade with Tamoxifen was discussed but discounted due to the likely impact on bone growth and unpredictability on whether it would affect pregnancy in the future. In addition, Tamoxifen would not allow breast tissue to regress, and surgery would still be required. The recognised treatment for gigantomastia is with surgical intervention, whether that be a bilateral breast reduction mammoplasty or mastectomy. Attempts with hormone manipulation are slow and inconsistent with any symptomatic relief from the enlarged breast tissue occurring only after a prolonged period of time [8]. According to the reports in the literature, gigantomastia is unlikely to recur after reduction surgery and this is, therefore, often the surgical option taken [1,10]. The surgical options were fully explored with the patient and her parents to include the unknown risk of re-growth, as the patient was pre-pubertal, and the need for further surgery. It was felt that keeping her own tissue to form the breast mounds, rather the disfigurement of mastectomies and reconstructions, outweighed this unknown risk of re-growth. Therefore, a bilateral breast

reduction, using a wise pattern technique, was chosen in order to preserve as natural a breast mound as possible, in an attempt, to avoid reconstructive surgery in the future. However, the patient and parents were carefully counselled about loss of the nipple areolar complex, due to its involvement in the skin changes, and the possibility of the need for delayed reconstruction with local flaps and tattooing. The final surgical histology, identifying the presence of PASH, is an unusual finding in prepubertal breast tissue. Although, as the growth of PASH is likely to be stimulated by hormones, it seems in keeping with the case presented in this report.

#### 4. Conclusion

This is an unusual case in which a prepubertal female developed gigantomastia with the underlying histology being that of PASH. Since the reduction mammoplasty surgery, she has entered puberty without evidence of any re-growth of the breast tissue which is consistent with other published cases. This work has been reported in line with the SCARE 2020 criteria [10].

#### Provenance and peer review

Not commissioned, externally peer-reviewed.

#### Patient consent

I confirm that written informed consent was obtained from the patient for publication of this case report and accompanying images. A copy of the written consent is available for review by the Editor-in-Chief of this journal on request.

#### Ethical approval

N/A.

#### Funding

N/A.

#### Guarantor

Rachael Johnson.

#### Research registration number

N/A.

#### CRediT authorship contribution statement

Manuscript compiled by Rachael Johnson with contributions from Richard Haywood.

#### Conflict of interest

There are no conflicts of interest financial or personal with other people or organisations that could inappropriately influence (bias) this work.

#### References

- [1] A. Dancey, M. Khan, J. Dawson, F. Peart, Gigantomastia: a classification and review of the literature, *J. Plast. Reconstr. Aesthet. Surg.* 61 (2008) 493–502.
- [2] P. Wolner-Hanssen, B. Palmer, N.O. Sjoberg, B. Astedt, Gigantomastia, *Acta Obstet. Gynecol. Scand.* 60 (1981) 525–527.
- [3] M.J. Cho, J.H. Yang, H.G. Choi, W.S. Kim, Y.B. Yu, K.S. Park, An idiopathic gigantomastia, *Ann. Surg. Treat. Res.* 88 (3) (2015) 166–169.
- [4] N.A. Beischer, J.H. Hueston, R.J. Pepperell, Massive hypertrophy of the breasts in pregnancy: report of 3 cases and review of the literature, 'never think you have seen everything', *Obstet. Gynecol. Surv* 44 (1989) 234–243.
- [5] C.J. Taylor, D.L. Chester, Bilateral breast reduction surgery in elderly women: a retrospective review of outcomes, *J. Plast. Reconstr. Aesthet. Surg.* 65 (2012) 304–311.
- [6] S.M. Wieman, J. Landercasper, J.M. Johnson, Tumoral pseudoangiomatic stromal hyperplasia of the breast, *Am. Surg.* 74 (2008) 1211–1214.
- [7] E. Bowman, G. Oprea, J. Okoli, Pseudoangiomatic stromal hyperplasia (PASH) of the breast: a series of 24 patients, *Breast J.* 18 (2012) 242–247.
- [8] A. Vashistha, M. Rundla, F. Khan, P. Om, Idiopathic gigantomastia with pseudoangiomatic stromal hyperplasia: a case report, *Int. J. Surg. Case Rep.* 77 (2020) 915–919.
- [9] R.A. Agha, T. Franchi, C. Sohrabi, G. Mathew, for the SCARE Group, The SCARE 2020 guideline: updating consensus Surgical CAse REport (SCARE) guidelines, *International Journal of Surgery* 84 (2020) 226–230.
- [10] A.G. Ship, Virginal and gravid mammary gigantism: recurrence after reduction mammoplasty, *Br. J. Plast. Surg.* 24 (1971) 396–401.