

Available online at [www.sciencedirect.com](http://www.sciencedirect.com)

ScienceDirect

journal homepage: [www.elsevier.com/locate/radcr](http://www.elsevier.com/locate/radcr)

## Case Report

# Hemoperitoneum identified by focused assessment with sonography for trauma following cardiopulmonary resuscitation ☆☆☆

Nina Liu, BS<sup>a</sup>, Kevin R. Roth, DO<sup>a,\*</sup>, Danielle A. Nesbit, DO<sup>a</sup>, Justin R. Giordano, DO<sup>a</sup>, Joseph J. Stirparo, MD<sup>b</sup>, Andrew H. Miller, DO<sup>a</sup>

<sup>a</sup>Lehigh Valley Health Network, Department of Emergency and Hospital Medicine/USF Morsani College of Medicine, Cedar Crest Boulevard & I-78, Allentown, PA 18103, USA

<sup>b</sup>Lehigh Valley Health Network, Department of Surgery/USF Morsani College of Medicine, Cedar Crest Boulevard & I-78, Allentown, PA 18103, USA

## ARTICLE INFO

## Article history:

Received 7 July 2021

Revised 16 September 2021

Accepted 18 September 2021

## Keywords:

Hemoperitoneum

FAST

CPR

## ABSTRACT

It is generally recognized that lives are saved by administering high-quality cardiopulmonary resuscitation (CPR) to patients in cardiac arrest. A focused assessment with sonography for trauma (FAST) examination is an effective and non-invasive method for detecting rare complications of CPR, such as hemorrhage from abdominal visceral injury. We report the case of a 56-year-old female suffering from intra-abdominal hemorrhage caused by a liver laceration following CPR. The hemoperitoneum was diagnosed by a FAST examination. Although severe complications of CPR are rare, they can be easily detected with the use of a FAST examination. A FAST examination should be considered as a post-resuscitation approach to assess for life-threatening complications in all patients following cardiopulmonary resuscitation.

© 2021 The Authors. Published by Elsevier Inc. on behalf of University of Washington.

This is an open access article under the CC BY-NC-ND license

(<http://creativecommons.org/licenses/by-nc-nd/4.0/>)

## Introduction

Chest compressions performed during CPR have been known to cause injury, most commonly thoracic wall injuries such as rib and sternal fractures [1]. Intraabdominal injuries, such

as hepatic lacerations, are rarely seen as a consequence of CPR [2]. Despite the infrequent occurrence of liver injuries, such a complication can cause major hemorrhage, and rapid decompensation. A focused assessment with sonography for trauma (FAST) examination is an effective and non-invasive method to rule out solid organ injury and bleeding following

☆ Acknowledgments: Authors would like to acknowledge Alexis Saladino and Nicholas S. Imperato for formatting and editing. This research did not receive any specific grant from funding agencies in the public, commercial, or not-for-profit sectors.

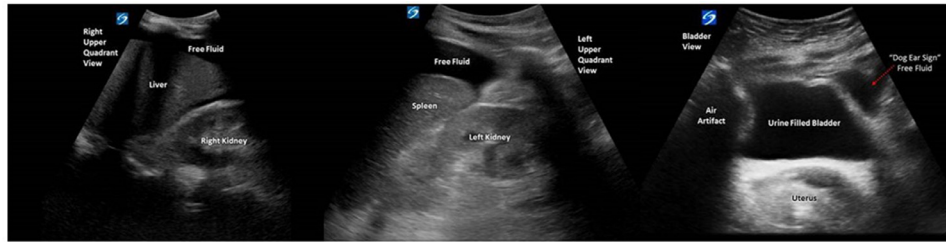☆☆ Competing Interests: The authors have no outside support information, conflicts or financial interest to disclose.

\* Corresponding author.

E-mail address: [Kevin.Roth@lvhn.org](mailto:Kevin.Roth@lvhn.org) (K.R. Roth).

<https://doi.org/10.1016/j.radcr.2021.09.046>

1930-0433/© 2021 The Authors. Published by Elsevier Inc. on behalf of University of Washington. This is an open access article under the CC BY-NC-ND license (<http://creativecommons.org/licenses/by-nc-nd/4.0/>)

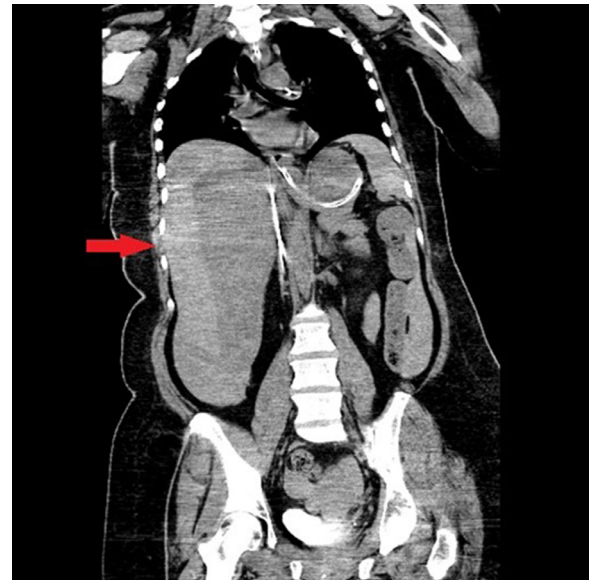


**Fig. 1 – (A-C) Representative images of free fluid demonstrated on a FAST examination.**

CPR, especially in hemodynamically unstable patients. We report a case of hemoperitoneum caused by liver laceration following cardiopulmonary resuscitation.

### Case report

A 56-year-old female with a history of hypertension and hyperlipidemia presented following an unwitnessed cardiac arrest. Her initial cardiac rhythm was noted to be ventricular fibrillation. She achieved return of spontaneous circulation (ROSC) following chest compressions, 2 rounds of defibrillation, and epinephrine, which were administered by emergency medical services. Upon arrival to the emergency department, the patient was unresponsive, unable to withdraw from painful stimuli, and had a Glasgow Coma Scale score of 3. Her vital signs included a blood pressure of 94 over 55 and a pulse of 120 beats per minute. An electrocardiogram showed diffuse ST depressions with a significantly elevated troponin of 0.72 ng/mL on her lab results. An initial computed tomography (CT) of her abdomen showed hepatomegaly and an intrahepatic hypodensity but no acute intra-abdominal or pelvic abnormality. Bedside transthoracic echocardiogram indicated anterior wall motion abnormality requiring cardiac catheterization. A drug eluting stent was placed after catheterization demonstrated a 99% stenosed proximal left anterior descending artery. She was then transferred to the intensive care unit for post-cardiac arrest therapeutic hypothermia. Shortly after her transfer, she became acutely hypotensive, and failed to respond to either vasopressors or intravenous fluid boluses. Her hemoglobin level fell from 12.9 g/dL at admission to 7.9 g/dL. Due to high suspicion for hemorrhagic shock in the setting of hemodynamic instability and acute anemia, anticoagulation was withheld, and blood products were administered. A bedside FAST examination (Fig. 1) revealed free fluid in the pelvis and upper abdominal quadrants bilaterally. A CT abdomen revealed a large volume hemoperitoneum from an unclear source requiring emergency exploratory laparotomy (Fig. 2). Surgeons found a liver laceration and ruptured hepatic cyst on the anterior surface of the right hepatic lobe. Following evacuation of the hemoperitoneum and control of the hemorrhage with abdominal packing, she began to stabilize hemodynamically. Following the surgery, interventional radiology completed an angiogram and embolization of her hepatic arteries for further hemostasis. Unfortunately, the patient



**Fig. 2 – Non-contrast computed tomography scan showing large volume hemoperitoneum.**

failed to make a significant neurologic recovery, and subsequently expired.

### Discussion

Complications from CPR are usually associated with rib and sternal fractures [3]. Major complications such as liver injury induced by resuscitation efforts occur in only 0.6% of cases [3]. An autopsy study of cardiac arrest patients found liver rupture in only 2.1% [4]. Even when they occur, it is more often from mechanical rather than manual CPR [5]. Injury to the liver is typically seen within the left lobe, due to its location, and proximity to the anatomic midline—both of which contribute to its susceptibility of injury from compressions [3].

Uniquely, our patient underwent manual chest compressions, and suffered a liver laceration to the right lobe. However, the presence of a ruptured hepatic cyst may explain why our patient was more susceptible to right lobe injury. The administration of anticoagulation prior to our patient's percutaneous coronary intervention may have led to progression of the hemorrhage and development of extensive hemoperitoneum.

The use of a FAST examination in this case demonstrates the utility and ease with which it can be used in patients with hemodynamic instability following CPR. Currently, the FAST examination is primarily used for medical assessments in the setting of traumatic injury [6]. Post-cardiac arrest care guidelines make no mention of this ultrasound examination. Chest X-rays are recommended to evaluate for complications of CPR but would be inadequate for evaluation of hepatic or another intra-abdominal organ injury [7]. Patients are often unresponsive following resuscitation, making an abdominal examination difficult to interpret. Hemorrhage from internal injuries can fail to be detected until patients become acutely hypotensive and rapidly decompensate, as seen with this case. Anticoagulation regimens for patients undergoing cardiac catheterization following cardiac arrest may contribute to the worsening of internal bleeding. In cases of hemodynamic instability following CPR, FAST examinations can diagnose intra-abdominal hemorrhage caused by solid organ injury [8,9].

While valuable in emergency situations, there are multiple limitations to the use of FAST examinations. Sensitivity has been reported as low as 42%, although most studies demonstrate higher sensitivities ranging from 69%–94% [10–13]. Patient body habitus and operator proficiency may impact the quality and diagnostic utility of ultrasound imaging [10,11].

## Conclusion

Although severe complications of CPR are rare, some are easily detected with the use of a FAST examination. A FAST examination should be considered as a post-resuscitation approach to assess for life-threatening complications in patients following cardiopulmonary resuscitation.

## Author contributions

All authors provided substantial contributions to manuscript content. All authors gave final approval of the version of the article to be published.

## Patient consent

Patient is deceased so written informed consent for publication of this case was not obtained.

## REFERENCES

- [1] Kashiwagi Y, Sasakawa T, Tampo A, Kawata D, Nishiura T, Kokita N, et al. Computed tomography findings of complications resulting from cardiopulmonary resuscitation. *Resuscitation* 2015;88:86–91. doi:[10.1016/j.resuscitation.2014.12.022](https://doi.org/10.1016/j.resuscitation.2014.12.022).
- [2] Buschmann CT, Tsokos M. Frequent and rare complications of resuscitation attempts. *Intensive Care Med* 2009;35(3):397–404. doi:[10.1007/s00134-008-1255-9](https://doi.org/10.1007/s00134-008-1255-9).
- [3] Meron G, Kurkciyan I, Sterz F, Susani M, Domanovits H, Tobler K, et al. Cardiopulmonary resuscitation-associated major liver injury. *Resuscitation* 2007;75(3):445–53. doi:[10.1016/j.resuscitation.2007.05.023](https://doi.org/10.1016/j.resuscitation.2007.05.023).
- [4] Krischer JP, Fine EG, Davis JH, Nagel EL. Complications of cardiac resuscitation. *Chest* 1987;92(2):287–91. doi:[10.1378/chest.92.2.287](https://doi.org/10.1378/chest.92.2.287).
- [5] Viniol S, Thomas RP, Gombert S, König AM, Betz S, Mahnken AH. Comparison of different resuscitation methods with regard to injury patterns in cardiac arrest survivors based on computer tomography. *Eur J Radiol* 2020;131:109244. doi:[10.1016/j.ejrad.2020.109244](https://doi.org/10.1016/j.ejrad.2020.109244).
- [6] American Institute of Ultrasound in Medicine; American College of Emergency Physicians. AIUM practice guideline for the performance of the focused assessment with sonography for trauma (FAST) examination. *J Ultrasound Med* 2014;33(11):2047–56. doi:[10.7863/ultra.33.11.2047](https://doi.org/10.7863/ultra.33.11.2047).
- [7] Peberdy AM, Callaway CW, Neumar RW, Geocadin RG, Zimmerman JL, Donnino M, et al. Part 9: post-cardiac arrest care: 2010 American Heart Association Guidelines for Cardiopulmonary Resuscitation and Emergency Cardiovascular Care. *Circulation* 2010;122(18\_suppl\_3):S768–86. doi:[10.1161/CIRCULATIONAHA.110.971002](https://doi.org/10.1161/CIRCULATIONAHA.110.971002).
- [8] Nashiki H, Miyate Y, Terui Y, Otani M. Focused assessment with sonography for trauma (FAST) identifies liver injury following cardiopulmonary resuscitation. *Case Reports* 2017;2017. doi:[10.1136/bcr-2017-221421](https://doi.org/10.1136/bcr-2017-221421).
- [9] Sharma P, Hernandez-Caballero C. Major liver trauma post-mechanical cardiopulmonary resuscitation: a list reported case of survival with normal cardiovascular and neurological outcome. *Oxf Med Case Reports* 2020. doi:[10.1093/omcr/omz144](https://doi.org/10.1093/omcr/omz144).
- [10] Miller MT, Pasquale MD, Bromberg WJ, Wasser TE, Cox J. Not so fast. *J Trauma Acute Care Surg* 2003;54(1):52–60. doi:[10.1097/00005373-200301000-00007](https://doi.org/10.1097/00005373-200301000-00007).
- [11] Lingawi SS, Buckley AR. Focused abdominal US in patients with trauma. *Radiology* 2000;217(2):426–9. doi:[10.1148/radiology.217.2.r00nv23426](https://doi.org/10.1148/radiology.217.2.r00nv23426).
- [12] Dolich MO, McKenney MG, Varela JE, Compton RP, McKenney KL, Cohn SM. 2,576 ultrasounds for blunt abdominal trauma. *J Trauma Acute Care Surg* 2001;50(1):108–12. doi:[10.1097/00005373-200101000-00019](https://doi.org/10.1097/00005373-200101000-00019).
- [13] Tso P, Rodriguez A, Cooper C, Militello P, Mirvis S, Badellino M, et al. Sonography in blunt abdominal trauma: a preliminary progress report. *J Trauma* 1992;33(1):39–43. doi:[10.1097/00005373-199207000-00009](https://doi.org/10.1097/00005373-199207000-00009).