



Oncology

Rare presentation of isolated bilateral testicular myeloid sarcoma: A case report

Alice Thomson^{a,*}, Brennan Timm^a, Simon Nazaretian^b, Peter Liodakis^{a,c}, Damien Bolton^a^a Department of Urology, Austin Health, Heidelberg, Victoria, Australia^b Clinical Director Anatomical Pathology VIC/SA, Australian Clinical Labs, Australia^c North Eastern Urology, Heidelberg, Victoria, Australia

ARTICLE INFO

Keywords:

Testicular neoplasms
Myeloid sarcoma
Acute myeloid leukaemia
Immunohistochemistry
Case report

ABSTRACT

Myeloid sarcoma (MS) of the testis is a rare soft tissue tumour which can herald the development of acute myeloid leukaemia (AML). The diagnosis of MS requires a high degree of suspicion as appropriate immunohistochemical staining must be performed to yield an early diagnosis. Whilst there is no consensus on treatment on MS involving the testis, most patients undergo orchidectomy and systemic chemotherapy, with or without radiation therapy. Early and aggressive treatment is key to achieving remission.

This case report describes a patient with bilateral testicular MS which heralded the development of AML, who underwent induction chemotherapy and achieved remission.

Introduction

Primary testicular malignancy makes up approximately 1% of male cancers in Western society, and 1–2% of cases have bilateral testicular involvement.¹ Testicular myeloid sarcoma (MS) is a highly aggressive extramedullary presentation of acute myeloid leukaemia (AML), secondary to rapid, uncontrolled expansion of immature blast cell populations beyond the bone marrow.² Extramedullary deposits are more commonly found elsewhere in the body such as the lymph nodes, skin, eye orbits and connective tissue of the neck. MS involvement of the testicles has only been recorded in 68 cases and in only four of those cases was it defined as the presenting symptom, where bilateral testicles were involved.² This case reviews the presentation and management of a rare case of bilateral testicular MS, preceding any diagnosis of AML or other blood dyscrasia.

Case presentation

A 67 year old male presented with a one week history of tender testicles bilaterally with newly palpable growing masses. The patient's medical history included hypertension and type 2 diabetes mellitus. He denied fevers, weight loss and had no history of undescended testicles or previous scrotal surgery. Examination demonstrated bilaterally tender testicles with firm central masses.

Ultrasound demonstrated hypervascular solid infiltrative masses within both testes (Fig. 1). Baseline bloods were all within normal limits as were alpha foetal protein (AFP) and human chorionic gonadotropin (hCG). Lactate dehydrogenase was mildly elevated at 272 U/L (Table 1).

A left inguinal orchidectomy was undertaken where histology was provisionally reported as non-Hodgkin lymphoma, and further immunohistochemistry (IHC) stains were required. Following review by a genitourinary pathologist, the diagnosis of MS of the testis was made (Table 1; Fig. 2). The case was reviewed at a multi-disciplinary meeting and the patient was subsequently transferred under the care of haematology at a tertiary hospital.

A fluorodeoxyglucose (FDG)-positron emission tomography (PET) demonstrated multiple sub-centimetre, subcutaneous nodules over the anterior chest wall which were not FDG-tracer-avid and no other lesions were defined. Notably the residual right testicular mass was also not FDG-tracer avid. An MRI brain was ordered due the patient's complaint of right jaw numbness, which demonstrated leukaemic invasion at the base of skull. A lumbar puncture was performed which demonstrated an expanded populations of monocytic cells which was suspicious for leukaemic involvement of the central nervous system.

He received induction chemotherapy of intrathecal 7 + 3 (cytarabine, methotrexate and dexamethasone). This was complicated by neutropenic colitis, an *Escherichia coli* and *Staphylococcus haemolyticus* bacteraemia, drug-induced hypersensitivity syndrome and severe

* Corresponding author. Department of Urology, 145 Studley Road, PO Box 5555, Heidelberg, Victoria, 3084, Australia.

E-mail address: alice.thomson@austin.org.au (A. Thomson).

<https://doi.org/10.1016/j.eucr.2021.101585>

Received 12 January 2021; Accepted 24 January 2021

Available online 28 January 2021

2214-4420/© 2021 The Authors.

Published by Elsevier Inc.

This is an open access article under the CC BY-NC-ND license

(<http://creativecommons.org/licenses/by-nc-nd/4.0/>).

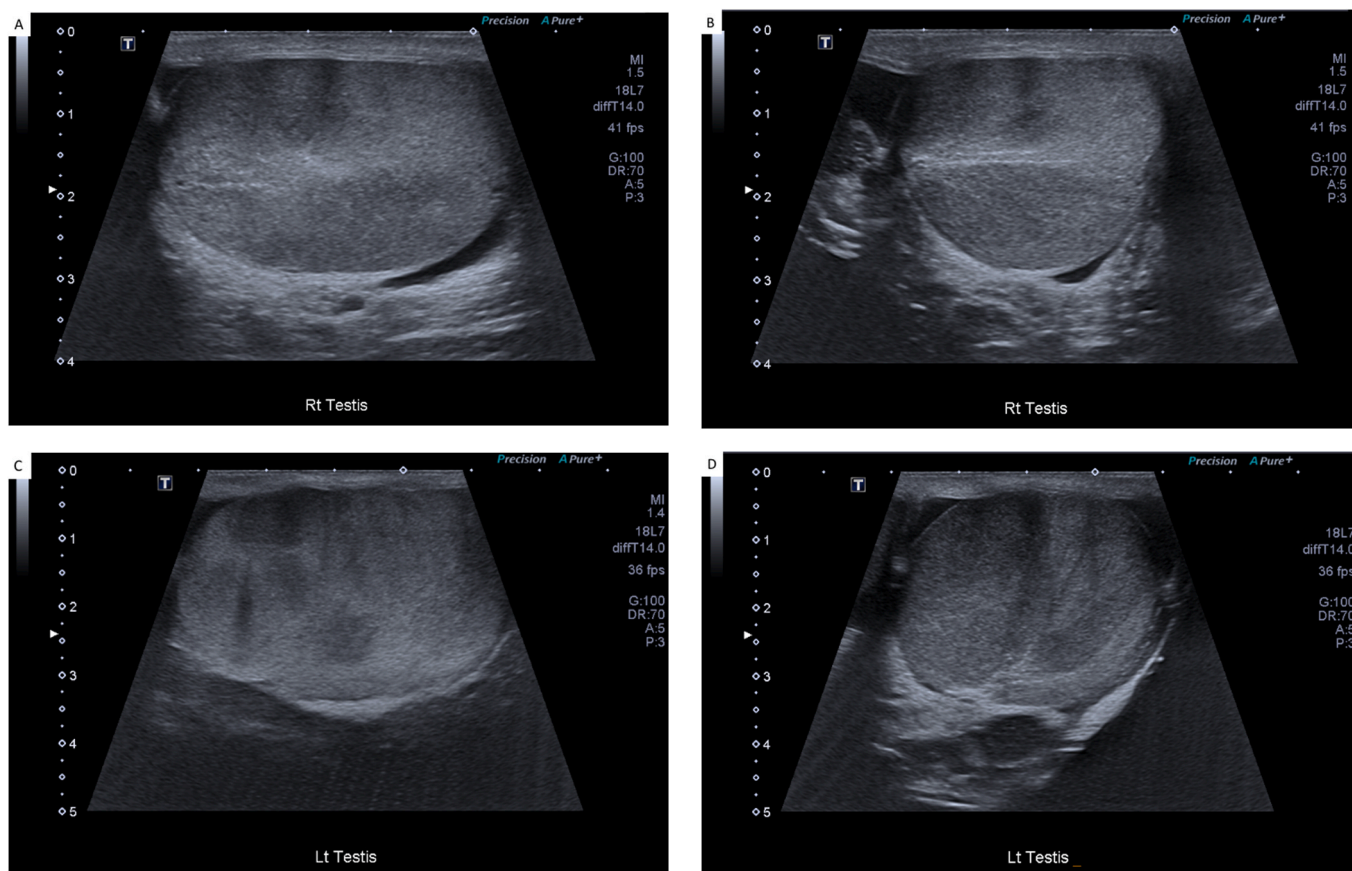


Fig. 1. Ultrasound imaging of the testes demonstrating bilateral hypervascular solid infiltrative masses. The right testis in longitudinal (A) and transverse view (B), and the left testis in longitudinal (C) and transverse views (D).

Table 1
Laboratory investigations.

	Marker	Result (reference range)
Blood	Beta-HCG	<1 IU/L (0–5 IU/L)
	AFP	2 µg/L (<11 µg/L)
	LDH	272 U/L (120–250 U/L)
Left testis immunohistochemistry	MPO	Negative
	Ly	Positive
	CD43	Positive

delirium requiring intubation and inotropic support for one week.

The patient improved clinically and returned home. Repeated FDG PET scan at did not demonstrate any avid lesions and the patient’s right testis returned to pre-morbid size where previously it had a palpable mass centrally.

Discussion

In an audit of the National Cancer Centre Database from 2004 to 2013, only 746 patients out of all patients with diagnosed with AML presented with MS of any site, accounting for 0.8% of all AML cases.³ A systematic review of 68 cases of testicular MS diagnosed over 30 years identified that unilateral and bilateral testicular involvement was equivalent, but only four cases had bilateral testicular involvement at presentation without any prior diagnosis of blood dyscrasia.²

Testicular masses are deemed malignant until histologically disproven, although some features of the presenting symptoms of testicular MS may be unique. Mass growth is often rapid (appearing over one week in the case of our patient), and may be more associated with pain, nausea and extreme tenderness on examination. Ultrasound is useful in

defining mass size and excluding epididymoorchitis as a differential, but lacks specificity and sensitivity to diagnose the type of malignancy.

The morphological appearance of MS is highly variable and is often similar to other lymphoid malignancies. IHC staining for chloroacetate esterase (CAE), CD43, myeloperoxidase (MPO) and lysozyme (Ly) characterises myeloid lineage and may reveal the correct diagnosis.²

Misdiagnosis continues to be of significant concern with these cancers, as noted by McIlwain et al., where six of eight cases of reviewed testicular MS were initially misdiagnosed.⁴ The most common misdiagnoses are lymphoma, infection, spermatocele and plasmacytoma. Flow cytometry’s increasing availability has made it easier to distinguish between morphological variants and further emergence of the use of cytogenetics as a diagnostic tool for haematological malignancies can have important prognostic and treatment indications.²

There is no consensus on the best course of treatment for testicular MS. Management is often multimodal utilising orchidectomy as a diagnostic and therapeutic tool, followed by a chemotherapeutic regimen and, in some cases, radiation therapy. Due to the highly aggressive nature of MS, an early diagnosis of testicular MS is associated with better survival outcomes for patients.⁵ The mean time to develop AML from the diagnosis of isolated MS may be five months, and as such it is typically recommended that extramedullary lesions are treated with upfront chemotherapy following an AML regimen immediately post diagnosis.³

There is an added layer of complexity for the treatment of cancer in reproductive organs due the effect of treatment on fertility. Whilst this was not a concern for the patient presented above, fertility counselling should be a consideration for patients with family planning in mind.

Conclusion

This is a rare presentation of bilateral testicular MS presenting prior

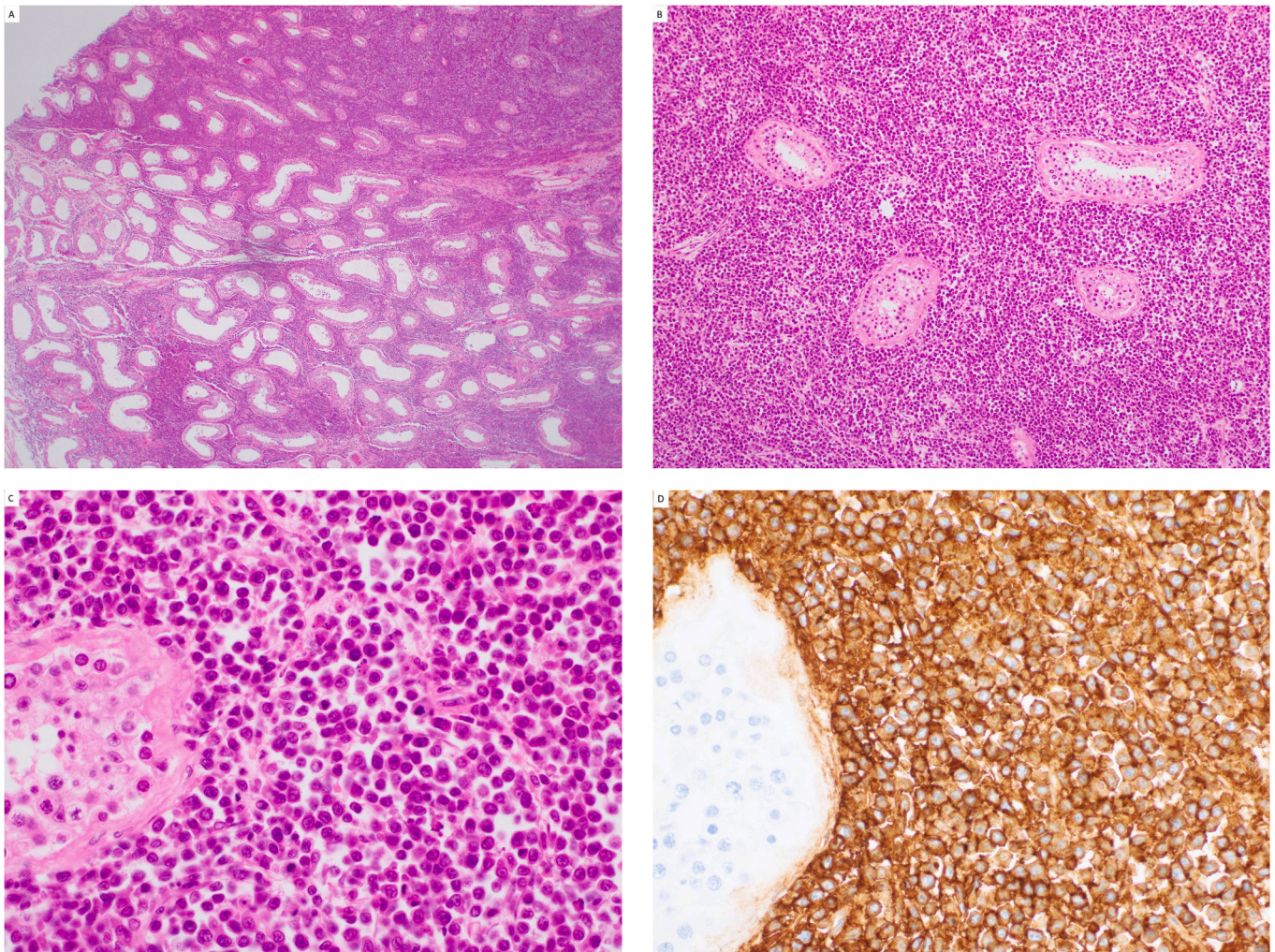


Fig. 2. Histology of specimen. Haematoxylin and eosin stain at low (20x) (A) and high (100x) (B) power show the infiltrative growth of haemopoietic lesions without the destruction otherwise seen in most other malignant neoplasms. High power (400x) view (C) shows the cytological features of the myeloid sarcoma and an adjacent benign residual tubule (bottom left of image). (D) Cell membrane staining of CD43 and cytoplasmic staining of lysozyme, diagnostic for myeloid sarcoma (400x).

to any diagnosis of AML or blood dyscrasia. This patient's early review by a genitourinary pathologist who had knowledge of the appropriate IHC stains led to rapid diagnosis, upfront treatment and early remission. This highlights the utility of being aware of testicular MS and appropriate IHC stain choice to ensure a correct and prompt diagnosis to allow for treatment, resulting in a positive treatment outcome.

Consent

Informed consent was obtained from the patient on which this case report was written.

Declaration of competing interest

The authors declare they have no conflict of interest.

References

1. Laguna MP, Albers P, Algaba F, et al. Testicular cancer. EAU guidelines. Published, Accessed <https://uroweb.org/guideline/testicular-cancer/>; 2020. Accessed October 10, 2020.
2. Sahu KK, Sherif AA, Mishra AK, Lal A, Singh A. Testicular myeloid sarcoma: a systematic review of the literature. *Clin Lymphoma, Myeloma & Leukemia*. 2019;19(10):603–618. <https://doi.org/10.1016/j.clml.2019.04.013>.
3. Goyal G, Bartley AC, Patnaik MM, Litzow MR, Al-Kali A, Go RS. Clinical features and outcomes of extramedullary myeloid sarcoma in the United States: analysis using a national data set. *Blood Canc J*. 2017;7(8). <https://doi.org/10.1038/bcj.2017.79>.
4. McIlwain L, Sokol L, Moscinski LC, Saba HI. Acute myeloid leukemia mimicking primary testicular neoplasm. Presentation of a case with review of literature. *Eur J Haematol*. 2003;70(4):242–245. <https://doi.org/10.1034/j.1600-0609.2003.00050.x>.
5. Paydas S, Zorludemir S, Ergin M. Granulocytic sarcoma: 32 cases and review of the literature. *Leuk Lymphoma*. 2006;47(12):2527–2541. <https://doi.org/10.1080/10428190600967196>.