

Received: 2016.10.24
Accepted: 2016.12.05
Published: 2017.07.04

The Reliability of Panoramic Radiography Versus Cone Beam Computed Tomography when Evaluating the Distance to the Alveolar Nerve in the Site of Lateral Teeth

Authors' Contribution:
Study Design A
Data Collection B
Statistical Analysis C
Data Interpretation D
Manuscript Preparation E
Literature Search F
Funds Collection G

BCEF 1 Gabrielė Česaitienė
BEF 2 Kęstutis Česaitis
ADEG 2 Jonas Junevičius
ACDE 1 Tadas Venskutonis

1 Clinical Department of Dental and Oral Diseases, Lithuanian University of Health Sciences, Kaunas, Lithuania
2 Clinical Department of Dental and Maxillofacial Orthopedics, Lithuanian University of Health Sciences, Kaunas, Lithuania

Corresponding Author: Gabrielė Česaitienė, e-mail: gcesaitiene@gmail.com
Source of support: Departmental sources

Background: The aim of this study was to compare the reliability of panoramic radiography (PR) and cone beam computed tomography (CBCT) in the evaluation of the distance of the roots of lateral teeth to the inferior alveolar nerve canal (IANC).





Material/Methods: 100 PR and 100 CBCT images that met the selection criteria were selected from the database. In PR images, the distances were measured using an electronic caliper with 0.01 mm accuracy and white light x-ray film reviewer. Actual values of the measurements were calculated taking into consideration the magnification used in PR images (130%). Measurements on CBCT images were performed using i-CAT Vision software. Statistical data analysis was performed using R software and applying Welch's t-test and the Wilcoxon test.

Results: There was no statistically significant difference in the mean distance from the root of the second premolar and the mesial and distal roots of the first molar to the IANC between PR and CBCT images. The difference in the mean distance from the mesial and distal roots of the second and the third molars to the IANC measured in PR and CBCT images was statistically significant.

Conclusions: PR may be uninformative or misleading when measuring the distance from the mesial and distal roots of the second and the third molars to the IANC.

MeSH Keywords: **Cone-Beam Computed Tomography • Endodontics • Mandibular Nerve • Paresthesia • Radiography, Panoramic**

Full-text PDF: <http://www.medscimonit.com/abstract/index/idArt/902083>

 1980  2  7  23



Background

The radiological examination techniques that are most commonly used in odontology are intraoral and panoramic radiography [1]. Their main drawback is that they generate two-dimensional (2D) images of three-dimensional (3D) structures, which inevitably results in overlapping of the anatomical structures, causing so-called “anatomic noise”. Cone beam computed tomography (CBCT) is a more recent technique capable of generating 3D images of teeth and their surrounding maxillo-facial structures [2,3]. This radiological examination technique uses lower radiation doses, compared to regular computed tomography, and helps to avoid overlapping of the anatomical structures in sagittal, frontal, and axial CBCT images [1,4,5].

During endodontic treatment, radiological examination is necessary for the evaluation of the anatomy and the number of dental root canals as well as the relationship of dental roots with adjacent anatomical structures – the maxillary sinus, the mental foramen, and the inferior alveolar nerve canal (IANC). Over-instrumentation of the root canal during endodontic treatment may result in damage to the inferior alveolar nerve (IAN). Nerve healing via scarification causes direct temporary paresthesia [6]. Aggressive preparation of the root canal destroys the root apex, and thus medications, irrigation solutions, and filling materials used during the treatment may come into direct contact with the inferior alveolar nerve (IAN) [7]. Sodium hypochlorite is the most commonly used irrigant, which, upon contact with periapical tissues, may cause edema, pain, and numbness and necrosis of the IAN and the mental nerve [8]. Another important point in the treatment of premolars and molars with chronic periapical periodontitis is the extrusion of the infected root canal debris towards IANC or the mental foramen. This may affect the protective perineurium of the nerve and cause nerve conduction impairment [9]. Filling materials (such as gutta-percha and various sealants) may cause paresthesia via mechanical or chemical mechanisms [10,11]. Their minimal extrusion through the root apex is usually well-tolerated by periapical tissues, yet extensive exposure of the nerve structures with these substances may have a toxic effect causing sensory changes, including anesthesia, hypoesthesia, paresthesia, or dysesthesia [12]. All these complications are related to improper evaluation of the distance between the dental roots and the IANC [13,14].

In dentists' everyday practice, the relationship between the root apex and the IANC during manipulations in the area of premolars and molars is usually analyzed on panoramic radiographs. However, distortions characteristic of 2D images seriously impede the evaluation or make it impossible altogether. This study, was aimed to assess whether PR is a reliable tool for the evaluation of the distance of the roots of lateral teeth to the IANC, and what possible error PR images cause, compared to 3D images.

Material and Methods

During this retrospective study, 120 PR and 120 CBCT images (i-CAT; Imaging Sciences International Inc., USA) were selected from the database.

Image selection criteria were the following: 1) both radiography techniques applied to the same patient; 2) good quality of the images; 3) no history of orthodontic surgery or orthodontic treatment of the mandible; and 4) no history of mandibular fracture. In total, PR and CBCT images of 100 patients met the inclusion criteria.

PR was performed using i-CAT (Imaging Sciences International Inc.) tomography scanner with the following settings: 94 kV voltage, 5 mA current, and 16 s exposure time.

CBCT scanning was performed using i-CAT (Imaging Sciences International Inc.) tomography scanner with the following settings: 120 kV voltage and 3–8 mA current. All CBCT images were performed using 0.2 mm voxel size resolution.

In order to reduce the error in interpretation of the results of the study, a single researcher experienced in working with i-CAT Vision software was calibrated and analyzed the images. CBCT and PR images of 10 patients not included into the study were analyzed. The analysis was repeated after two weeks.

In the analyzed images, the distance from the root apex of the second premolar and the root apices of all molars to the IANC was measured. In total, 147 second premolars, 93 mesial roots of the first molars, 92 distal roots of the first molars, 123 mesial roots of the second molars, 114 distal roots of the second molars, 57 mesial roots of the third molars, and 41 distal roots of the third molars were analyzed. Teeth with a single root were assigned to the mesial root group.

PR images were put on white light x-ray film reviewer and using an electronic caliper with 0.01 mm accuracy measurements of the distances were done. The actual values of the measurement were calculated taking into consideration the magnification used in PR images (130%).

Measurements in CBCT images were performed using i-CAT Vision software (Imaging Science International Inc., version 1.9.3.13). The filters were set to the normal position, only contrast and lighting were adjusted. The measurements were performed in transverse (buccal-lingual) jawbone sections orthogonal to the horizontal plane (Figures 1, 2). Analyses were performed using a 23-inch flat screen monitor with 1,920×1,080-pixel resolution, in a dimly lit room, and with no time limitations.

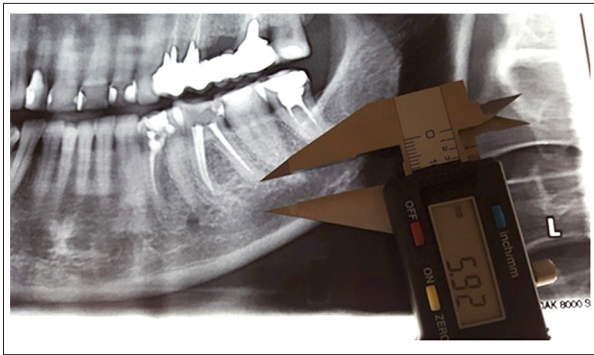


Figure 1. Sample of measurements in PR images placed on white light x-ray film reviewer (first molar group).

Results

The evaluation of the mean values of measurements on CBCT and PR images before and after two weeks showed no statistically significant difference ($p>0.05$) (Table 1). In total, 420 teeth were evaluated. The sample consisted of 55% female and 45% male patients. The patients' ages ranged from 25–81 years, the mean age and standard deviation was 50.19 ± 11.22 years, the median age was 51 years, and the mode age was 55 years. The comparison of the mean distances from the root apices of the studied teeth to the IANC between PR and CBCT images showed that there was no statistically significant difference between CBCT and PR images concerning the mean distance from the root apex of the second premolar ($p=0.24$), or the apices of the mesial ($p=0.59$), and distal ($p=0.74$) roots of the first molar to the IANC. Meanwhile, a statistically significant

difference ($p<0.01$) was detected between CBCT and PR images concerning the mean distance from the apices of the mesial and distal roots of the second and third molars to the IANC (Table 2). This is also shown in figures presenting data distribution (Figures 3–7).

Discussion

Second premolars were included into this study in addition to all molars, based on the results of a study by Afkhami et al. that showed that in 67% of cases, the mental foramen was located at the second premolar, in 24% – it was located between the first and the second premolars, in 6% – it was located at the first premolar, and in the remaining 3% – it was located beyond the second premolar [15]. These findings are important for dentists' and endodontic daily practice, as they may help avoid neural sensory impairment during anesthesia or therapeutic procedures. Therefore, it was decided to measure this distance as well. In addition, studies that identified specific attributes of PR evaluation based on clinical situation of suspicion of a short distance between the group of lateral teeth and the IANC failed to provide an objective result expressed in millimeters, and thus these results are significant only with respect to teeth that are located especially close to the IANC. In endodontics, over-instrumentation of the root canal may extend beyond the minimal distance described by Tantanapornkul et al., which may cause a break in the continuity of the IANC margin on PR [16].

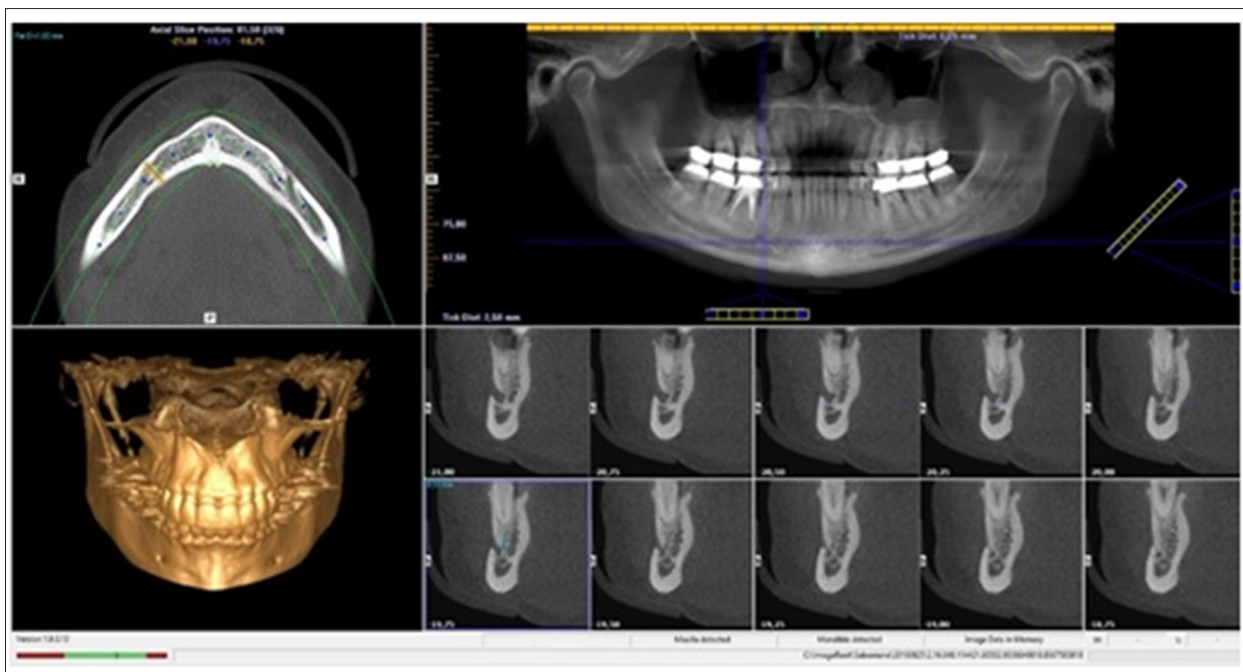


Figure 2. Sample of measurements in i-CAT Vision software (second premolars group).

Table 1. The researcher’s calibration of CBCT and PR.

Variable	CBCT		PR	
	Paired difference V mm [95% CI]	p value	Paired difference V mm [95% CI]	p value
Root of second premolar	0.004 [-0.26–0.27]	0.753	0.217 [-0.50–0.6]	0.128
Mesial root of first molar	0.066 [-0.31–0.18]	0.495	0.307 [-0.19–0.72]	0.145
Distal root of first molar	0.061 [-0.27–0.15]	0.609	0.000 [-0.15–0.32]	1.000
Mesial root of second molar	0.117 [-0.39–0.16]	0.501	0.135 [-0.42–0.15]	0.205
Distal root of second molar	0.101 [-0.36–0.08]	0.293	0.158 [-0.36–0.05]	0.149
Mesial root of first molar	0.120 [-0.61–0.16]	0.382	0.169 [-0.42–0.08]	0.055
Distal root of second molar	0.216 [-0.51–0.14]	0.110	0.135 [-0.48–0.21]	0.098

CBCT – cone beam computed tomography; PR – panoramic radiograph; V – mean value; CI – confidence interval; p – level of significance; mm – millimeters.

Table 2. Mean distances from the roots of different teeth to the IANC with standard deviations.

	CBCT (V mm ±SD)	PR (V mm ±SD)
Root of second premolar	5.70±3.12	5.64±3.42
Mesial root of first molar	5.91±3.10	5.84±3.41
Distal root of first molar	5.30±2.74	4.93±2.71
Mesial root of second molar	4.63±3.14	3.05±2.55
Distal root of second molar	4.59±3.03	3.45±2.84
Mesial root of first molar	3.36±2.70	1.49±1.60
Distal root of second molar	3.78±2.87	1.84±1.99

CBCT – cone beam computed tomography; PR – panoramic radiograph; V – mean value; SD – standard deviation; mm – millimeters.

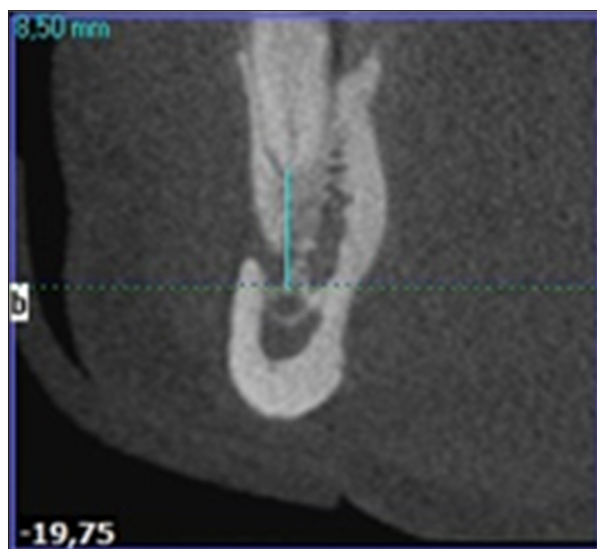


Figure 3. Sample of measurements in i-CAT Vision software (second premolars group).

In endodontics, dental X-rays are used most frequently – but the paralleling technique is not always employed. Measurements on images generated by applying the bisecting angle technique become inaccurate. The visibility of the IANC is poorer because of the difference in bone density, and the visibility of the mental foramen – because of the position or the size of the film or the sensor [17].

Statistical data analysis was performed using R software (R core team, GNU GPL v2). The obtained results were evaluated by applying Welch’s t-test and the Wilcoxon test. The level of significance was set at $p \leq 0.05$.

Inaccuracies on PR images occur for a variety of reasons, including patient movement during the procedure, incorrect initial positioning of the patient’s head, or incorrect position of the tongue (not pressed against the palate). In addition, significant changes in the image of the posterior teeth may result from

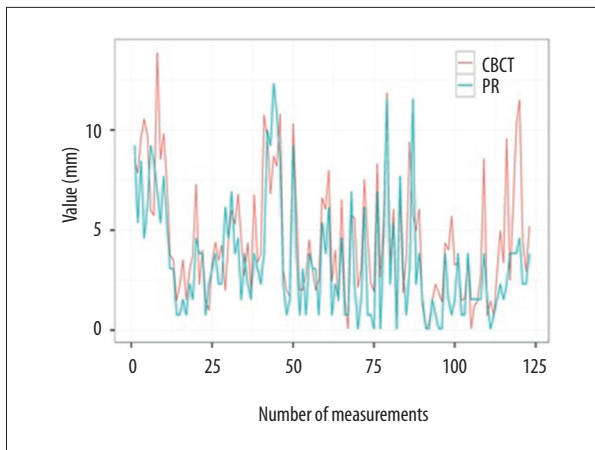


Figure 4. Distribution of the values of the mesial root of the second molar on CBCT and PR, measuring the distance from the root apex to the IANC. CBCT – cone beam computed tomography; PR – panoramic radiograph.

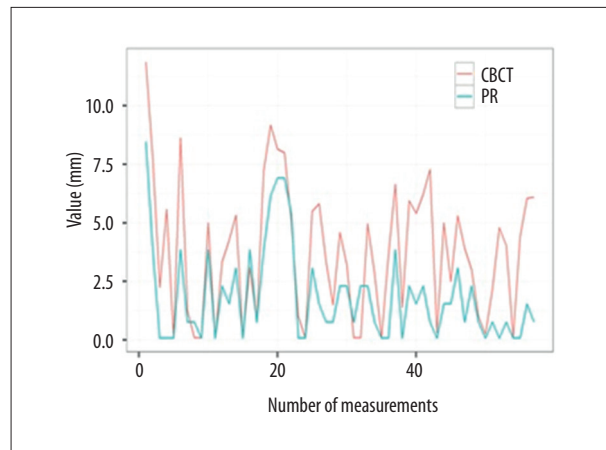


Figure 6. Distribution of the values of the mesial root of the third molar on CBCT and PR, measuring the distance from the root apex to the IANC. CBCT – cone beam computed tomography; PR – panoramic radiograph.

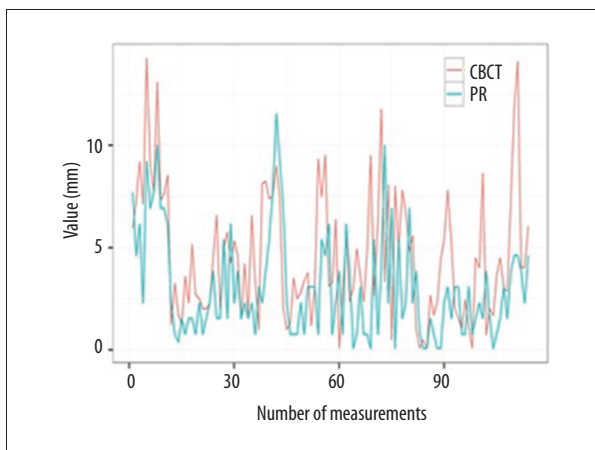


Figure 5. Distribution of the values of the distal root of the second molar on CBCT and PR, measuring the distance from the root apex to the IANC. CBCT – cone beam computed tomography; PR – panoramic radiograph.

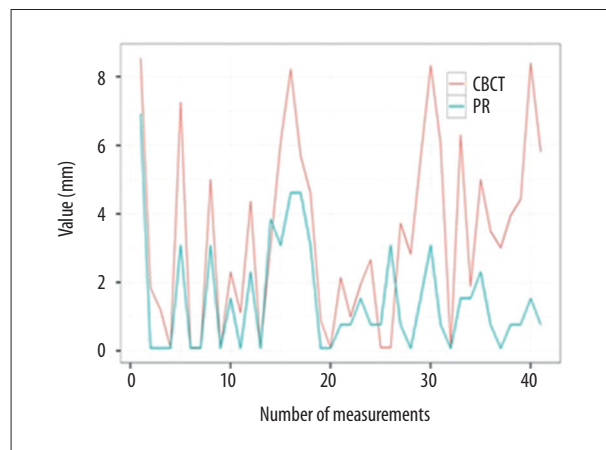


Figure 7. Distribution of the values of the distal root of the third molar on CBCT and PR, measuring the distance from the root apex to the IANC. CBCT – cone beam computed tomography; PR – panoramic radiograph.

the deviation of the tooth in the bone from the perpendicular axis of the jaw. These events might have affected the results of this study as well. It is easier for the operator to position the patient's head correctly during PR than during dental x-ray, it was decided to perform measurements on PR images [18].

Blurring in CBCT images may be caused by movements of the head or the jaws, or by swallowing. Metal objects, dental restorations, orthodontic appliances, jewelry, or metal implants located close to the examined teeth create beam-like artifacts that negatively affect the image quality [19].

100 patients X-ray image pairs were selected, there were only 57 mesial roots and 41 distal roots of the third molars; however, a statistically significant difference was detected between

the measurements performed on PR and CBCT images. The results of this study are in line with those obtained by Ghaeminia et al. who assigned evaluated teeth into risk groups based on PR image measurements. When the measurements were checked with CBCT, 60.4% of the teeth were reassigned to a different risk group. This proves that measurement errors on PR images are real [20].

Because the sample size was too small for anatomical studies, the evaluation of the distance from the roots of the lateral teeth to the IANC was limited to a comparative analysis of PR and CBCT images. Burklein et al. presented the results of their anatomical studies involving over 3,000 measured roots (N=3,127). The distance between root apices and the IANC in the group of female patients was almost half that observed

in the group of male patients [21]. In this study sample, the comparison of measurements between the male and female groups yielded similar results. In the group of female patients, the distance from the mesial and distal roots of the second molar to the IANC was statistically significantly shorter on both CBCT and PR. This finding was in line with the results published by Kovisto et al., which corroborate the findings obtained by Burklein et al., indicating that sex influences the distance of the roots of lateral teeth to the IANC [21,22]. These authors also found that age affected the measurements as well. The results of a study by Kovisto et al. showed that shorter distances to the IANC were typical in patients younger than 18 years of age, whereas according to Burklein et al., shorter distance was characteristic of patients younger than 35 years of age. In this study, no statistically significant differences between the age groups were found, but these results cannot be considered reliable because of the small sample size [21,22].

Performing PR for the purposes of endodontic treatment would not be expedient according to the ALARA (as low as reasonably achievable) principle because radiation exposure during

PR reaches 2.7–24.3 μSv and the exposure during CBCT reaches 11–674 μSv [23]. However, if the patient already has a PR image, it is advisable to consider the position of the teeth intended for treatment with respect to the IANC.

Conclusions

Panoramic radiography may be a reliable tool when measuring the distance from the root of the second premolar and the mesial and distal roots of the first molar to the IANC, but PR data may be uninformative or misleading when measuring the distance from the mesial and distal roots of the second and the third molars to the IANC. Therefore, in this situation, CBCT should be used for the evaluation whenever possible. It is also noteworthy that the distance between the roots of the aforementioned teeth and the IANC visible in PR images looks shorter than it really is, which could result in a patient's fear of possible complicated treatment, as well as additional stress for the dentist during the procedure.

References:

- Boeddinghaus R, Whyte A: Current concepts in maxillofacial imaging. *Eur J Radiol*, 2008; 66: 396–418
- Robinson S, Suomalainen A, Kortensniemi M: Mu-CT. *Eur J Radiol*, 2005; 56: 185–91
- White SC, Pharoah MJ: The evolution and application of dental maxillofacial imaging modalities. *Dent Clin North Am*, 2008; 52: 689–705
- Venskutonis T, Plotino G, Juodžbalys G, Mickevičienė L: The Importance of cone-beam computed tomography in the management of endodontic problems: A review of the literature. *J Endod*, 2014; 40: 1895–901
- Huybrechts B, Bud M, Bergmans L et al: Void detection in root fillings using intraoral analogue, intraoral digital and cone beam CT images. *Int Endod J*, 2009; 42: 675–85
- Gluskin AH: Mishaps and serious complications in endodontic obturation. *Endod Top*, 2005; 12: 52–70
- Tilotta-Yasukawa F, Millot S, El Haddioui A et al: Labiomandibular paresthesia caused by endodontic treatment: An anatomic and clinical study. *Oral Surg Oral Med Oral Pathol Oral Radiol Endod*, 2006; 102(4): 47–59
- Gernhardt CR, Eppendorf K, Kozłowski A, Brandt M: Toxicity of concentrated sodium hypochlorite used as an endodontic irrigant. *Int Endod J*, 2004; 37(4): 272–80
- Poveda R, Bagán JV, Fernández JM, Sanchis JM: Mental nerve paresthesia associated with endodontic paste within the mandibular canal: Report of a case. *Oral Surg Oral Med Oral Pathol Oral Radiol Endod*, 2006; 102(5): 46–49
- Escoda-Francoli J, Canalda-Sahli C, Soler A et al: Inferior alveolar nerve damage because of overextended endodontic material: A problem of sealer cement biocompatibility? *J Endod*, 2007; 33(12): 1484–89
- Renton T: Prevention of iatrogenic inferior alveolar nerve injuries in relation to dental procedures. *Dent Update*, 2010; 37: 350–63
- Blanas N, Kienle F, Sándor GK: Inferior alveolar nerve injury caused by thermoplastic gutta-percha overextension. *J Can Dent Assoc*, 2004; 70(6): 384–87
- Varinauskas V, Nimčenko T, Kubilius R: Case report: Inferior alveolar nerve injury due to root canal treatment, diagnosis and treatment possibilities. *Sveikatos Mokslai*, 2011; 21(2): 89–95
- Gonzalez MM, Torres-Lagares D, Gutiérrez-Pérez JL, Segura-Egea JJ: Inferior alveolar nerve paresthesia after overfilling of endodontic sealer into the mandibular canal. *J Endod*, 2010; 36(8): 1419–21
- Afkhami F, Haraji A, Boostani HR: Radiographic localization of the mental foramen and mandibular canal. *J Dent*, 2013; 10(5): 436–42
- Tantanapornkul W, Okouchi K, Fujiwara Y et al: A comparative study of cone beam computed tomography and conventional panoramic radiography in assessing the topographic relationship between the mandibular canal and impacted third molars. *Oral Surg Oral Med Oral Pathol Oral Radiol Endod*, 2007; 103: 253–59
- Gupta T: Localization of important facial foramina encountered in maxillo-facial surgery. *Clin Anat*, 2008; 21(7): 633–40
- Ngeow WC, Yuzawati Y: The location of the mental foramen in selected Malay population. *J Oral*, 2003; 45(3): 171–75
- Scarfe WC, Farman AG: What is cone-beam CT and how does it work? *Dent Clin North Am*, 2008; 52: 707–30-v
- Ghaemini H, Meijer GJ, Soehardi A et al: The use of cone beam CT for removal of wisdom teeth changes the surgical approach compared with panoramic radiography: A pilot study. *Int J Oral Maxillofac Surg*, 2011; 40: 834–39
- Burklein S, Grund C, Schafer E: Relationship between root apices and the mandibular canal: a cone beam computed tomographic analysis in a German population. *J Endod*, 2015; 41(10): 1696–700
- Kovisto T, Ahmad M, Bowles WR: Proximity of the mandibular canal to the tooth apex. *J Endod*, 2011; 37(3): 311–15
- SEDEXCT Project. Radiation Protection 172. Evidence Based Guidelines on Cone Beam CT for Dental and Maxillofacial Radiology, 2011