KJU Korean Journal of Urology

www.kjurology.org
http://dx.doi.org/10.4111/kju.2014.55.1.2

Review Article

Laparoendoscopic Management of Midureteral Strictures

Christos Komninos[1,2], Kyo Chul Koo[1], Koon Ho Rha[1]

[1]Department of Urology, Urological Science Institute, Yonsei University College of Medicine, Seoul, Korea, [2]Department of Urology, General Hospital of Nikaia 'St. Panteleimon', Athens, Greece

The incidence of ureteral strictures has increased worldwide owing to the widespread use of laparoscopic and endourologic procedures. Midureteral strictures can be managed by either an endoscopic approach or surgical reconstruction, including open or minimally invasive (laparoscopic/robotic) techniques. Minimally invasive surgical ureteral reconstruction is gaining in popularity in the management of midureteral strictures. However, only a few studies have been published so far regarding the safety and efficacy of laparoscopic and robotic ureteral reconstruction procedures. Nevertheless, most of the studies have reported at least equivalent outcomes with the open approach. In general, strictures more than 2 cm, injury strictures, and strictures associated either with radiation or with reduced renal function of less than 25% may be managed more appropriately by minimally invasive surgical reconstruction, although the evidence to establish these recommendations is not yet adequate. Defects of 2 to 3 cm in length may be treated with laparoscopic or robot-assisted uretero-ureterostomy, whereas defects of 12 to 15 cm may be managed either via ureteral reimplantation with a Boari flap or via transuretero-ureterostomy in case of low bladder capacity. Cases with more extended defects can be reconstructed with the incorporation of the ileum in ureteral repair.

Keywords: *Laparoscopy; Reconstructive surgical procedures; Robotics; Ureter*

This is an Open Access article distributed under the terms of the Creative Commons Attribution Non-Commercial License (http://creativecommons.org/licenses/by-nc/3.0) which permits unrestricted non-commercial use, distribution, and reproduction in any medium, provided the original work is properly cited.

Article History:
received 30 December, 2013
accepted 8 January, 2014

Corresponding Author:
Koon Ho Rha
Department of Urology, Urological Science Institute, Yonsei University College of Medicine, 50 Yonsei-ro, Seodaemun-gu, Seoul 120-752, Korea
TEL: +82-2-2228-2310
FAX: +82-2-312-2538
E-mail: khrha@yuhs.ac

INTRODUCTION

Ureteral stricture is a common cause of luminal narrowing of the ureter, which results in upper urinary tract obstruction and renal damage if left untreated [1]. The midureter extends from the upper to the lower border of the sacrum [2]. Factors that may contribute to the development of ureteral strictures include surgical procedures (iatrogenic strictures), stone passage, radiation therapy, penetrating traumatic injuries, and idiopathic disorders [2]. Briefly, ureteral strictures can be divided into benign or malignant, as well as ischemic or nonischemic. It is of paramount importance to distinguish the cause of a ureteral stricture because the management of ureteral strictures varies depending on stricture etiology, location, and length. Wolf Jr et al. [3] defined a stricture as ischemic when it follows surgery (e.g., hysterectomy) or radiation therapy, whereas the stricture is considered nonischemic if it is secondary to stone passage or a congenital abnormality. Ischemic strictures tend to be associated with fibrosis and scar formation and thus are less likely to respond to endoureterotomy [3]. Malignant strictures are caused by a primary ureteral malignancy or extrinsic mechanical compression by a tumor and are best treated with surgery, indwelling long-term metallic stents, or percutaneous nephrostomy tubes [4].

During recent years, an increasing incidence of iatrogenic strictures has been observed, owing to the widespread use of laparoscopy and upper urinary tract endoscopy [5]. Parpala-Sparman et al. [5] analyzed the data of 72 patients suffering from ureteral injury and reported that most of the injuries occurred following gynecological (64%) or general surgery (25%) procedures, especially if a laparoscopic approach was performed.

In general, midureteral strictures can be managed by either an endoscopic approach or surgical reconstruction, in-

© The Korean Urological Association, 2014

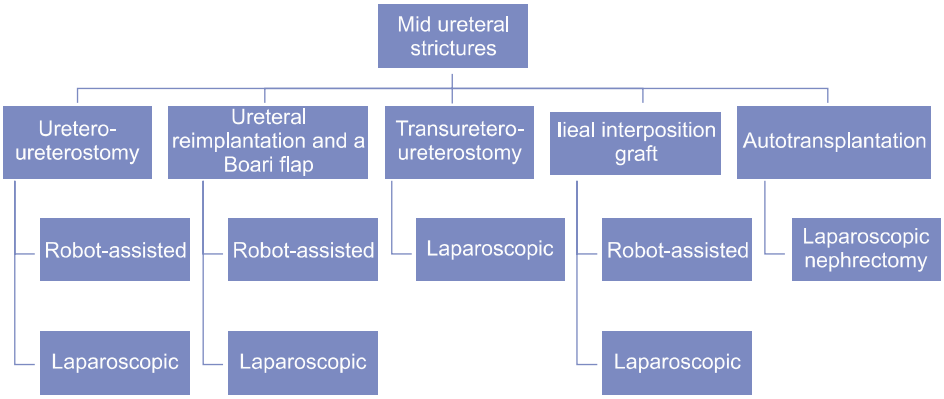

FIG. 1. Minimally invasive reconstruction options of midureteral strictures.

TABLE 1. Overall studies on management of midureteral pathologic features

Author	Year	No. of Pts	Procedure	OR (min)	EBL (mL)	LOS (d)	Recur	Follow-up (mo)
Lee et al. [16]	2013	2	RUU	163	238	3.0	0	6
Lee et al. [8]	2013	3	RUU	227	208	2.6	1	16
Buffi et al. [15]	2011	5	RUU	135	NR	3.0	0	8
Hemal et al. [12]	2010	7	RUU	110	50	3.0	0	28
Lee et al. [13]	2010	3	RUU	136	NR	3.0	0	24
Baldie et al. [14]	2012	3	RUU	223	100	1.3	0	15
		1	RBF	283	300	4.0	0	2
Simmons et al. [11]	2007	3	LUU LBF	NR	86	2.6	0	23
Nezhat et al. [10]	1998	8	LUU	NR	100	NR	1	2–6
Piaggio and Gonzalez [24]	2007	3	LTUU	263	47	3.0	0	6
Musch et al. [22]	2013	5	RBF	287	NR	14.0	2	14
Castillo et al. [18]	2013	30	LBF	161	123	4.8	1	32
Yang et al. [21]	2011	2	RBF	NR	150	5.0	0	NR
		1	RUU	306		8.0	0	20
Schimpf et al. [20]	2008	1	RBF	172	0	2.0	0	12
Rassweiler et al. [19]	2007	4	LBF	253	268	8.0	0	NR
Wagner et al. [26]	2008	1	RIIG	540	0	5.0	0	48
Gill et al. [25]	2000	1	LIIG	480	200	4.0	NR	NR

Pt, patient; OR, operative time; EBL, estimated blood loss; LOS, length of stay; Recur, recurrence of stricture; RUU, robot-assisted laparoscopic uretero-ureterostomy; RBF, robot-assisted laparoscopic Boari flap; LUU, laparoscopic uretero-ureterostomy; LBF, laparoscopic Boari flap; LTUU, laparoscopic transuretero-ureterostomy; LIIG, laparoscopic ileal interposition graft; RIIG, robot-assisted laparoscopic ileal interposition graft; NR, not reported.

cluding open or minimally invasive (laparoscopic/robotic) techniques [2]. With the spread of laparoscopic training and the advancement of robotic technology, minimally invasive surgical ureteral reconstruction is increasing worldwide [6-26] (Fig. 1). The advantages are negligible scars, less pain, and faster convalescence. In addition, robotic assistance offers some major benefits to urologic surgeons when performing this complex procedure, such as instrument flexibility during the reconstruction of the ureter, magnified visualization, and tremor elimination. Although ureteral reconstruction is increasingly being performed through minimally invasive approaches, clinical experience in laparoscopic and robot-assisted laparoscopic ureteral reconstruction is still limited worldwide.

A summary of the principal studies of the laparoscopic and robotic management of midureteral strictures is presented in Table 1.

WHEN TO PERFORM LAPAROSCOPIC/ROBOTIC RECONSTRUCTION

The success of any treatment modality may depend on the length of the ureteral stricture, the cause of the stenosis, and the location of the stricture [2]. In general, an initial attempt at endoscopic management is indicated in most patients with ureteral strictures, because the potential morbidity and the recovery period are generally less with these procedures [3,4]. Additionally, a failed endoscopic procedure does not appear to influence the success of subsequent surgical repair. Although balloon dilation and endoureter-

otomy for ureteral strictures have high success rates, these do not duplicate the very high success rates (91%–97%) achieved through surgical repair [27].

An indication of the need for ureteral surgical reconstruction is the occurrence of ureteral stricture in a functional kidney. Surgical reconstruction is frequently offered after failed endoscopic management. Repeated endoscopical incisions are more likely to fail, and therefore, surgical repair is recommended. For ischemic strictures or strictures that develop shortly after external injury, surgery may be the first choice of treatment. Moreover, strictures more than 2 cm and those associated either with radiation or with reduced renal function less than 25% may be managed more appropriately by surgical reconstruction, because of the high failure rate in this group of patients treated endoscopically [1,3,28].

Ureteral stricture in a nonfunctional kidney is an absolute contraindication for ureteral reconstruction. Additionally, a history of previous extensive intra-abdominal surgeries and morbid obesity are relative contraindications to laparoscopic/robotic ureteral reconstruction, because they may inhibit the ability to establish the operative domain and limit the full range of motion of the instruments [7].

CLINICAL EVALUATION

Patients should be evaluated with a urinalysis, urine culture, serum creatinine and electrolytes, renal ultrasound, computed tomography of the abdomen and pelvis, and diuretic renal scans in order to determine kidney function and the cause of obstruction. Moreover, a mercaptoacetyltriglycine renal scan provides a baseline for follow-up examinations after surgery. Antegrade and retrograde pyelography will usually provide sufficient information regarding the ureteral anatomy and length of the stricture and allow concomitant placement of a ureteral stent. Subsequent ureteroscopy with biopsy and cytology should be carried out in any patient for whom the etiology of stricture is not well established [2].

MINIMALLY INVASIVE SURGICAL TECHNIQUES

The options for surgical reconstruction of midureteral strictures are uretero-ureterostomy (UU), transureteroureterostomy (TUU), and ureteral reimplantation with a Boari flap [2,6-26]. The principles of laparoscopic and robotic ureteral reconstruction include the preservation of a good vascular supply, the complete excision of pathological lesions, good drainage, and a wide spatulated, watertight, mucosa-to-mucosa, tension-free anastomosis. Defects of 2 to 3 cm in length may be managed with UU, whereas defects of 12 to 15 cm may be better managed via TUU or ureteral reimplantation with a Boari flap [7]. Additional length (3–4 cm) can be given by mobilizing the ipsilateral kidney and performing a downward nephropexy, with securing of the posterior kidney capsule to the psoas fascia by use of several absorbable sutures [8]. Care should be taken to avoid injury to the genitofemoral nerve and the femoral nerve in the vicinity when placing the sutures [8]. In the case of extensive ureteral strictures, renal autotransplantation or ureteral substitution using the ileum may be required [1].

1. Uretero-ureterostomy

UU is the most common repair performed in the midureter in both laparoscopic and robotic studies. The patient is positioned in the dorsal lithotomy and moderate to steep Trendeleburg position. The steps of the procedure consist of the mobilization of the ureter, excision of the diseased segment, spatulation of the ureteral ends, and end-to-end anastomosis by using 4-0 or 5-0 polyglactin sutures, in either an interrupted or a running fashion. Spatulation should be carried out at least 5 mm on both the distal and proximal ureteral segments. Particular care should be taken to avoid directly grasping or applying monopolar cautery to the ureter to preserve the periureteric mesentery and blood supply. After completion of the posterior portion of the anastomosis, a double pigtail stent must be introduced through the ureter, across the anastomosis, cephalic into the renal pelvis and caudally into the bladder. A peritoneal or omental flap may be wrapped around the completed anastomosis, so as to maximize the ureteral blood supply and enhance postoperative healing. In case of difficulties in identifying the ureter, it is suggested to first identify a healthy segment of the ureter and to then trace the ureter circumferentially toward the diseased segment. Concomitant downward nephropexy may assist in achieving a tension-free anastomosis [8]. Contraindications to performing UU are long ureteral strictures, which do not allow a tension-free end-to-end anastomosis.

The first successful laparoscopic uretero-ureterostomy (LUU) was reported by Nezhat et al. [9] in 1992. The same authors 6 years later retrospectively analyzed the data of eight patients who had undergone LUU and reported that seven subjects were found to have patent anastomosis in a short-term follow up of 6 months [10].

In a review of all published LUU reports from 1990 to 2006, De Cicco et al. [29] suggested that the outcomes following LUU were comparable with those for the open procedure regarding recurrence ratios. However, the authors reported that the literature data are scant and heterogeneous and do not permit solid conclusions.

Simmons et al. [11] also described their experience with laparoscopic ureteral reconstruction in patients with benign ureteral stricture disease. The authors retrospectively compared laparoscopically versus open procedures and reported that the open group had greater estimated blood loss (EBL) and longer length of hospital stay (LOS), but the patency success was almost 100% and was not significantly different between the two groups.

Hemal et al. [12] retrospectively analyzed the data of seven patients who had undergone RUU and also reported an excellent operative success after an average follow-up period of 28 months. According to this study, the mean operative time was 110 minutes, mean EBL was 50 mL, mean

LOS was 3 days, and there were neither surgical complications nor recurrences of ureteral strictures. These results were also supported by Lee et al. [13] in case series of three adults with greater than 24 months of follow-up.

In a large single-institution study of robotic ureteral stricture repair, Baldie et al. [14] announced their experience with midrobotic ureteral reconstruction in comparison with a cohort of patients who had undergone pure laparoscopic ureteral reconstruction. The authors reported comparable short-term results in both series. Additionally, they observed that patients who had been treated with UU had shorter operative times and lengths of hospitalizations than did subjects who had undergone ureteral reimplantation. One patient in the RUU group developed a recurrent stricture that was treated by balloon dilatation.

Overall, despite the relatively limited number of patients and studies available, these reports demonstrate that laparoscopically and robotically performed UU is efficient and safe with outcomes comparable to the open approach. A common difficulty during the robotic procedure is the intraoperative localization of the ureteral stricture owing to the lack of tactile feedback. Therefore, various techniques have been described in an effort to overcome this limitation. The injection of normal saline through a preoperatively placed ureteral catheter and the subsequent hydronephrosis has been reported to facilitate identification of the stricture location [14].

Buffi et al. [15] described a novel technique for the precise definition of the site and extension of the stricture by using a flexible ureterenoscope. According to this technique, a double surgical approach with a robot-assisted laparoscopic access and flexible ureterenoscopy was performed. After the laparoendoscopic identification of the ureter, a flexible ureterenoscope was inserted into the ureter over a previously placed guidewire. Once the ureteral stenosis was reached, the laparoendoscopic light was lowered and the ureter was transilluminated to clearly identify the stricture with laparoscopic and endoscopic images. Afterward, the stenotic ureter was excised at the level of the lower edge and then the ureter was opened on the upper part to clearly identify all stenotic segments and healthy tissue. The authors reported that this technique was feasible in all five patients who underwent robot-assisted laparoendoscopic uretero-ureterostomy (RUU), with no significant complications, acceptable operative time, and no ureteral stricture recurrences after 8 months of follow-up. The limitation of this method is that only the lower margin of the stricture can be localized during the procedure.

In order to localize the upper margin of the stricture as well, Lee et al. [16] presented an interesting technique to intraoperatively localize ureteral strictures during RUU by use of indocyanine green (ICG) visualization under near-infrared light. The authors inserted a 6-Fr ureteral catheter preoperatively and then used the catheter intraoperatively to inject 10 mL of diluted ICG above and below the level of stenosis. The authors reported that the absence or decreased fluorescence of the diseased ureter clearly delineated the upper and lower margins of the ureteral stricture. Postoperatively, all cases were clinically successful after 6 months of follow-up.

2. Boari flap

The Boari flap technique can be considered in long ureteral obstructed segments with a subsequent large ureteral defect following the stricture's excision. The main principle is to bridge the large gap with a tabularized L-shaped bladder flap. Therefore, the bladder is mobilized, and an anterior bladder flap is created with an apex of approximately 2 cm and a base of 4 cm, beginning about 2 cm distal from the bladder neck and extending to the ipsilateral posterior dome [17]. The flap length should be 3 to 4 cm longer than the estimated ureteral defect if a nonrefluxing anastomosis is planned. Additionally, the ratio of flap length to base width should not be greater than 3:1 to avoid flap ischemia [2]. Afterwards, the apex of the flap is anastomosed to the spatulated ureter by using an interrupted 4-0 polyglactin suture.

Typically, the Boari flap is accompanied by fixation of the bladder dome to the ipsilateral psoas tendon to decrease tension and stabilize the bladder. Several absorbable sutures are placed in a direction parallel to the genitofemoral nerve to avoid entrapment of it. The superior and midvesical arteries on the contralateral side may need to be ligated to provide additional mobility. A small bladder capacity is likely to be associated with inadequate Boari flap creation, warranting consideration in the preoperative surgical planning [2].

The Boari flap was initially described in humans in 1947 [30]. Fugita et al. [17] were the first to describe three cases with long ureteral obstructions that underwent laparoscopic Boari flap procedures. The procedures were successfully performed in all patients, without any complications, and no stricture recurrence was observed after a mean follow-up time of 11 months.

In a large multi-institutional study, Castillo et al. [18] reported the outcomes of 30 patients who were treated with a laparoscopic Boari flap. The mean length of ureteral resection was 7 cm (range, 5–20 cm), mean operative time was 161 minutes, and severe complications occurred in three patients. The overall success rate was 96% with a mean follow-up of 32 months.

Recently, Rassweiler et al. [19] compared the outcomes of four patients who had been treated by the laparoscopic Boari flap technique with two subjects who had undergone open Boari flap reconstruction for similar pathologies. The authors reported that although a longer operative time (253 minutes vs. 220 minutes) was observed in the laparoscopic group, EBL was lower (268 mL vs. 725 mL) and LOS (8 days vs. 17 days) was shorter. The success rate was 100% after laparoscopy.

Robotic Boari flap creation was initially performed by Schimpf and Wagner [20] in a 75-year-old woman suffering from an iatrogenic stricture. The operative time was 172 minutes and the hospitalization time was 2 days with no

recurrence after 12 months of follow-up. Additional series have been reported since then [21,22].

Overall, most of the studies have demonstrated that the combined vesicopsoas-hitch with Boari flap technique can be safely performed with a high success rate, shorter hospitalization, and minimal complications for the treatment of wide ureteral defects in the mid third of the ureter.

3. Transuretero-ureterostomy

Extensive strictures of the mid ureter may be treated with TUU. After ligation of the distal ureteral portion, the proximal end (donor ureter) is transposed across the midline through a retroperitoneal tunnel, created with blunt dissection and anastomosed to the contralateral ureter (recipient ureter). Only the portion of recipient ureter needed for the anastomosis is exposed in order to preserve the periureteral tissue and avoid vascular damage. A longitudinal ureterotomy at the medial aspect of the recipient ureter is performed to match the lumen of the donor ureter. The anastomosis is carried out with running 5-0 or 6-0 absorbable monofilament sutures. A double-J ureteral stent is usually passed from the donor renal pelvis, through the anastomosis, and into the bladder.

The obvious disadvantage of this procedure is the involvement of the contralateral normal kidney and ureter [2]. Therefore, the accepting ureter must be unobstructed and not be affected by any disease process that will put both kidneys postoperatively at risk. In addition, if reflux to the recipient ureter is present, it should be identified preoperatively with a voiding cystography and corrected simultaneously [2]. The insufficient length of the donor ureter (proximal stricture) to reach the contralateral ureter is the only absolute contraindication. TUU is also contraindicated for retroperitoneal fibrosis, for upper tract transitional cell carcinoma, and for patients with recurrent nephrolithiasis.

The laparoscopic feasibility of the procedure was initially demonstrated in swans, in which eight of nine procedures were successfully completed [23]. In humans, Piaggio and Gonzalez [24] described their initial experience regarding transperitoneal laparoscopic transuretero-ureterostomy in 2007. The authors applied this technique in three children. Mean operative time, EBL, and LOS were 263 minutes, 47 mL, and 3 days, respectively. According to the authors, the postoperative course was uneventful except for a urinary leak in one case immediately postoperatively, which was resolved in less than 24 hours. None of the patients developed recurrent stricture after a mean follow-up of 6 months.

4. Ileal interposition graft

Long-segment ureteral strictures can be reconstructed by using the ileum. Incorporation of the ileum in ureteral repair is reserved for selective cases in which a defect cannot be bridged by other methods or the bladder is unsuitable for reconstruction. An appropriate segment of the ileum is delivered to the retroperitoneum via a small window in the colonic mesentery. The ileum is anastomosed to the renal pelvis or proximal ureter in an end-to-side, single-layer technique with either a running or interrupted Vicryl sutures (4-0 or 5-0) in an isoperistaltic orientation between the renal pelvis and the bladder for adequate urine transport. Ileocystostomy is usually performed in a double-layered technique on the posterior bladder wall about 2 cm craniolaterally to the native ureteral orifice to avoid extensive angulation and possible obstruction of the ileum during bladder filling. In general, to avoid metabolic problems, the length of the ileal segment should be as short as possible and at least 15 cm away from the ileocecal valve. Contraindications for ileal ureteral substitution are baseline renal insufficiency with a serum creatinine of greater than 2 mg/dL, bladder dysfunction, radiation enteritis, or inflammatory bowel disease. Follow-up should include serum chemistry to diagnose hyperchloremic metabolic acidosis [31].

In 2000, Gill et al. [25] reported successful laparoscopic ileal ureter replacement in an 87-year-old man suffering from upper tract transitional cell carcinoma. The bowel-to-bowel anastomosis was performed extracorporeally. Total operative time was 8 hours, EBL was 200 mL, and LOS was 4 days.

More recently, Wagner et al. [26] reported their experience in robot-assisted laparoscopic ileal ureter replacement in a patient with recurrent ureteral strictures due to stone disease. Total operative time was 9 hours with minimal blood loss. The patient was discharged home 5 days postoperatively and did not develop recurrent disease after 48 months of follow-up.

5. Autotransplantation

Autotransplantation of the kidney is recommended in patients with extensive ureteral strictures and either an absent or a poorly functional contralateral kidney. It can also be considered in cases in which ureteral substitution or repair is not feasible. In patients with a nonfunctional ipsilateral kidney, laparoscopic nephrectomy constitutes the appropriate treatment. The kidney is harvested laparoscopically with maximal renal vessel length. Subsequently, the renal vessels are anastomosed to the iliac vessels by using open surgical techniques and a ureteral reimplantation is carried out. It has been demonstrated that laparoscopic or robotic nephrectomy provides reduced postoperative analgesic need and faster recovery compared with the open techniques [2].

POSTOPERATIVE MANAGEMENT

The drain should be left in place until its output is low and the drain creatinine level suggests no urine leak. The urethral catheter should be removed approximately 5 to 7 days later in case of bladder incision, whereas 1 to 2 days are sufficient if UU has been performed. Some authors suggest performing cystography before catheter removal [14].

The optimal duration for stenting is still undetermined.

The rationale for the use of stents after ureteral reconstruction is to promote ureteral healing, prevent extravasation of urine, and avoid restricturing. However, stents can also cause inflammation that may prevent adequate healing or promote the formation of scar tissue if they left for a long period of time. Kerbl et al. [32] found no difference in the healing of ureteral strictures regardless of whether a 1-, 3-, or 6-week period of stenting was selected. Most authors recommend removing the ureteral stent approximately 4 to 6 weeks after the procedure.

Diuretic renal scintigraphy should be performed after at least 3 months postoperatively to assess the patency of the repair [7]. The most significant long-term risk associated with the surgical repair of ureteral strictures is recurrent obstruction. Therefore, all patients should undergo evaluation of the upper urinary tract every 6 months after surgery and probably up to 1 to 2 years. Recurrent strictures can be initially managed by balloon dilation or endoureterotomy before considering surgical revision.

CONCLUSIONS

Despite the fact that pure laparoscopy and robotics seems to offer important advantages in the treatment of midureteral strictures, only a small number of case series have been published regarding these challenging procedures. Therefore, it is difficult to arrive at a conclusion and produce any recommendations regarding the efficacy and safety of these techniques in the management of midureteral strictures, although most of the studies report equivalent success and complication rates between laparoscopic, robot-assisted, and open techniques.

However, for the time being, the management of ureteral strictures with either the laparoscopic or robotic approach depends on the surgeon's preference according to surgical experience and the cost of the procedure. The management of ureteral strictures by pure laparoscopy is technically demanding; however, robotics offers major benefits to overcome the technical complexities that are prohibitive in laparoscopic surgery, especially the intracorporeal suturing and knot tying for reconstruction. Important factors for achieving the best surgical outcome include selection of the most appropriate surgical technique, based on the history, location, and length of stricture, as well as accomplishment of a tension-free anastomosis by using well-vascularized ureteral tissue.

CONFLICTS OF INTEREST

The authors have nothing to disclose.

REFERENCES

1. Hafez KS, Wolf JS Jr. Update on minimally invasive management of ureteral strictures. J Endourol 2003;17:453-64.
2. Nakada SY, Hsu TH. Management of upper urinary tract obstruction. In: Kavoussi LR, Novick AC, Partin AW, Peters CA. Cambpell-Walsh urology. 10th ed. Philadelphia: Elsevier Saunders; 2012. p.1122-68.
3. Wolf JS Jr, Elashry OM, Clayman RV. Long-term results of endoureterotomy for benign ureteral and ureteroenteric strictures. J Urol 1997;158(3 Pt 1):759-64.
4. Kachrilas S, Bourdoumis A, Karaolides T, Nikitopoulou S, Papadopoulos G, Buchholz N, et al. Current status of minimally invasive endoscopic management of ureteric strictures. Ther Adv Urol 2013;5:354-65.
5. Parpala-Sparman T, Paananen I, Santala M, Ohtonen P, Hellstrom P. Increasing numbers of ureteric injuries after the introduction of laparoscopic surgery. Scand J Urol Nephrol 2008; 42:422-7.
6. Phillips EA, Wang DS. Current status of robot-assisted laparoscopic ureteral reimplantation and reconstruction. Curr Urol Rep 2012;13:190-4.
7. Windsperger AP, Duchene DA. Robotic reconstruction of lower ureteral strictures. Urol Clin North Am 2013;40:363-70.
8. Lee Z, Llukani E, Reilly CE, Mydlo JH, Lee DI, Eun DD. Single surgeon experience with robot-assisted ureteroureterostomy for pathologies at the proximal, middle, and distal ureter in adults. J Endourol 2013;27:994-9.
9. Nezhat C, Nezhat F, Green B. Laparoscopic treatment of obstructed ureter due to endometriosis by resection and ureteroureterostomy: a case report. J Urol 1992;148:865-8.
10. Nezhat CH, Nezhat F, Seidman D, Nezhat C. Laparoscopic ureteroureterostomy: a prospective follow-up of 9 patients. Prim Care Update Ob Gyns 1998;5:200.
11. Simmons MN, Gill IS, Fergany AF, Kaouk JH, Desai MM. Laparoscopic ureteral reconstruction for benign stricture disease. Urology 2007;69:280-4.
12. Hemal AK, Nayyar R, Gupta NP, Dorairajan LN. Experience with robot assisted laparoscopic surgery for upper and lower benign and malignant ureteral pathologies. Urology 2010;76:1387-93.
13. Lee DI, Schwab CW, Harris A. Robot-assisted ureteroureterostomy in the adult: initial clinical series. Urology 2010;75:570-3.
14. Baldie K, Angell J, Ogan K, Hood N, Pattaras JG. Robotic management of benign mid and distal ureteral strictures and comparison with laparoscopic approaches at a single institution. Urology 2012;80:596-601.
15. Buffi N, Cestari A, Lughezzani G, Bellinzoni P, Sangalli M, Scapaticci E, et al. Robot-assisted uretero-ureterostomy for iatrogenic lumbar and iliac ureteral stricture: technical details and preliminary clinical results. Eur Urol 2011;60:1221-5.
16. Lee Z, Simhan J, Parker DC, Reilly C, Llukani E, Lee DI, et al. Novel use of indocyanine green for intraoperative, real-time localization of ureteral stenosis during robot-assisted ureteroureterostomy. Urology 2013;82:729-33.
17. Fugita OE, Dinlenc C, Kavoussi L. The laparoscopic Boari flap. J Urol 2001;166:51-3.
18. Castillo OA, Travassos J, Escobar J F, Lopez-Fontana G. Laparoscopic ureteral replacement by Boari flap: multi-institutional experience in 30 cases. Actas Urol Esp 2013;37:658-62.
19. Rassweiler JJ, Gozen AS, Erdogru T, Sugiono M, Teber D. Ureteral reimplantation for management of ureteral strictures: a retrospective comparison of laparoscopic and open techniques. Eur Urol 2007;51:512-22.
20. Schimpf MO, Wagner JR. Robot-assisted laparoscopic Boari flap ureteral reimplantation. J Endourol 2008;22:2691-4.
21. Yang C, Jones L, Rivera ME, Verlee GT, Deane LA. Robotic-assisted ureteral reimplantation with Boari flap and psoas hitch: a single-institution experience. J Laparoendosc Adv Surg Tech A

2011;21:829-33.
22. Musch M, Hohenhorst L, Pailliart A, Loewen H, Davoudi Y, Kroepfl D. Robot-assisted reconstructive surgery of the distal ureter: single institution experience in 16 patients. BJU Int 2013; 111:773-83.
23. Dechet CB, Young MM, Segura JW. Laparoscopic transureteroureterostomy: demonstration of its feasibility in swine. J Endourol 1999;13:487-93.
24. Piaggio LA, Gonzalez R. Laparoscopic transureteroureterostomy: a novel approach. J Urol 2007;177:2311-4.
25. Gill IS, Savage SJ, Senagore AJ, Sung GT. Laparoscopic ileal ureter. J Urol 2000;163:1199-202.
26. Wagner JR, Schimpf MO, Cohen JL. Robot-assisted laparoscopic ileal ureter. JSLS 2008;12:306-9.
27. Netto Junior NR, Ferreira U, Lemos GC, Claro JF. Endourological management of ureteral strictures. J Urol 1990;144:631-4.
28. Seseke F, Heuser M, Zoller G, Plothe KD, Ringert RH. Treatment of iatrogenic postoperative ureteral strictures with Acucise endoureterotomy. Eur Urol 2002;42:370-5.
29. De Cicco C, Ret Davalos ML, Van Cleynenbreugel B, Verguts J, Koninckx PR. Iatrogenic ureteral lesions and repair: a review for gynecologists. J Minim Invasive Gynecol 2007;14:428-35.
30. Ockerblad NF. Reimplantation of the ureter into the bladder by a flap method. J Urol 1947;57:845-7.
31. Chung BI, Hamawy KJ, Zinman LN, Libertino JA. The use of bowel for ureteral replacement for complex ureteral reconstruction: long-term results. J Urol 2006175:179-83.
32. Kerbl K, Chandhoke PS, Figenshau RS, Stone AM, Clayman RV. Effect of stent duration on ureteral healing following endoureterotomy in an animal model. J Urol 1993;150:1302-5.