

## CLINICAL EXPERIENCE

# SARS-CoV-2 tracheitis in laryngectomised patients: A consecutive case-series study

## 1 | INTRODUCTION

After total laryngectomy (TL), the changes in the physiology of the tracheal epithelium due to the direct air passage through the stoma, loss of nasal humidification and impairment of the mucociliary clearance may increase the risk of lower respiratory tract infections.<sup>1,2</sup> Tracheitis represents a challenging condition with urgent management and hospitalisation and can be complicated by significant crusting and airway occlusion.

Total laryngectomy patients represent a unique challenge during the SARS-CoV-2 pandemic. On the one hand, they have a higher exposure to the contagion through respiratory droplets and aerosols, and a high risk of mortality due to the elderly age and comorbidities.<sup>3</sup> On the other hand, they carry a high risk of transmitting viral particles to healthcare staff through the tracheostoma.

SARS-CoV-2 antigens have been identified in tracheal epithelial cells of infected patients.<sup>4</sup> Also, evidences of acute and chronic tracheitis due to SARS-CoV-2 involvement of the tracheal mucosa have been shown in post-mortem examinations.<sup>5</sup> A previous study<sup>6</sup> demonstrated signs of a tracheobronchitis in a COVID-19+ patient, detected by lung scintigraphy. These reports, together with the experience collected during the pandemic peak, prompted us to conduct a review of patients who presented at our institution for acute tracheitis after TL and concomitant SARS-CoV-2 infection.

Herein, we describe the clinical features of a series of TL patients who contracted SARS-CoV-2 and developed severe tracheitis, focusing on its management, clinical course and histological features.

## 2 | METHODS

This is a retrospective study on patients subjected to TL who presented with acute tracheitis and concomitant positive testing for SARS-CoV-2. Patients were hospitalised at the University Hospital of Modena between September 2020 and January 2021.

Inclusion criteria were as follows: patients subjected to TL, patients who underwent SARS-CoV-2 status assessment by combined nasal and tracheal swab and tested positive, patients who required

hospitalisation, patients whose diagnosis of tracheitis was confirmed by means of an otolaryngologist evaluation including fibre-optic tracheoscopy or tracheobronchoscopy, and patients whose full clinical data were available. Were excluded from the study patients requiring hospitalisation, and who developed SARS-CoV-2 infection during their hospital stay (testing negative at admission).

Patients' demographic, clinical and surgical information was retrospectively reviewed from clinical charts. Local Ethics Committee approval was obtained on December 2020 (576/2020/OSS/AOUMO). Written informed consent was obtained from all patients. The study was conducted following the CARE guidelines.<sup>7</sup>

## 3 | RESULTS

Six patients were hospitalised for tracheitis after TL and tested positive for COVID-19 during the reporting period. Five cases were considered eligible, and a retrospective analysis of their clinical charts was performed. One patient was excluded for missing clinical data. Detailed clinical and laboratory data are reported in [Table 1](#).

The median age of patients was 77 years (range = 64–82 years). The median time from TL was 2 years (range = 1–9 years). All patients referred at the emergency room (ER) of our institution. The diagnosis of SARS-CoV-2 infection was made in the ER. All patients presented with significant oxygen desaturation at admission ( $O_2$  level <90%), three had fever and cough, one had thoracic pain, and one had bleeding from the tracheostoma. All patients underwent at least one CT scan examination of the chest. In all cases, a prompt ENT assessment, including fibre-optic evaluation through the stoma, was performed, allowing a diagnosis of tracheitis and aspiration/removal of secretions or crusts. Five patients were hospitalised at the infectious disease unit and one at the pneumology unit. No patient involved in the study needed recovery at the intensive care unit (ICU), except for patient #3 who had a brief ICU stay, concomitant with the rapid deterioration of his conditions.

In four cases, a pulmonary involvement was detected, whereas in one case, no signs or symptoms of pulmonary involvement were demonstrated. Bubble-humidified oxygen was provided via mask

over the tracheostoma in all cases, as well as aerosol administration of mucolytics and hyaluronic acid solutions. In all cases, intravenous pharmacological therapy, including wide-spectrum antibiotics and high-dose steroids, was administered. In 4 cases, anticoagulants (low molecular weight heparin at a prophylactic dose) were also indicated.

In three patients, microbiologic analysis of the tracheobronchial aspiration material was available, resulting in two cases in a multi-agent bacterial superinfection and no infection detected in one case. In four patients, a serological assessment for testing other respiratory viruses (influenza A virus, respiratory syncytial virus, rhinoviruses, parainfluenza viruses, adenoviruses, bocaviruses and metapneumovirus) was performed, with negative results.

All patients were evaluated daily by an otolaryngologist to assess the degree of airway obstruction and possibly to remove secretions, crusts and tracheobronchial plugs. Four patients showed variable degree of haemorrhagic component of the tracheitis. In three cases, a rigid bronchoscopy was required for the management of the airway occlusion and removal of distal bronchial plugs and blood clots (Figure 1). A tracheal tissue sample was collected in two cases and demonstrated an erosive inflammatory pattern on histopathological analysis (Figure 2).

Four patients progressively improved their general conditions and were discharged after a mean duration of 32 days (median = 38; range: 6–54 days). One patient died, 6 days after hospitalisation, due to critical pulmonary failure with rapid desaturation. At the time of data collection, no patient in the series re-presented for crusting, stoma stenosis or other long-term complications.

### Key Points

- SARS-CoV-2 is a possible cause of acute severe tracheitis in laryngectomees.
- In our series, the clinical picture was characterised by a haemorrhagic tracheitis with a slow resolution pattern.
- We observed a histological pattern of erosive inflammation of the respiratory epithelium.
- Planned tracheobronchoscopy and tracheal toilettes are recommended to prevent critical obstruction of the airway, which can be fatal in patients with associated impairment of lung function caused by SARS-CoV-2 infection.
- The present cases highlight the need for close interdisciplinary working and communication in the management of airway complications of COVID-19 infection.

## 4 | DISCUSSION

In the present paper, we described a series of five laryngectomees presenting with tracheitis characterised by a severe pattern, in terms of both duration and management challenges. Several criticalities were noticed in those patients: the haemorrhagic component, the detrimental role of oxygen therapy on the tracheal mucosa, the difficulty in ventilating patients with concomitant pulmonary

TABLE 1 Description of the clinical features of patients affected by SARS-CoV-2 tracheobronchitis after total laryngectomy

Patient No.	#1	#2	#3	#4	#5
Age	77	72	82	81	64
Years from TL	1	2	7	9	1
OD (<90%)	Yes	Yes	Yes	Yes	Yes
Other symptoms	Fever	None	Fever	Thoracic pain	Fever, active bleeding from trachea
Hospital ward	Infectious disease	Infectious disease	Infectious disease, ICU	Infectious disease	Pneumology
Pulmonary	Yes	No	Yes	Yes	Yes
Haemorrhagic tracheitis	Yes	Yes	No	Yes	Yes
LMWH	Yes	No	Yes	Yes	Yes
Oxygen therapy	Yes	Yes	Yes	Yes	Yes
Microbiology	MSSA +E. Coli	MSSA	-	Negative	Negative
Viral co-infection	Negative	Negative	-	Negative	Negative
Need for invasive procedure in OR	No	Yes (Bronchoscopy)	No	Yes (Bronchoscopy)	Yes (Bronchoscopy)
Tissue sampling	No	Yes	No	Yes	No
Hospital stay	5 weeks	5 weeks	6 days	7 weeks	12 days
Outcome	Recovered	Recovered	Dead	Recovered	Recovered

Note: Pulmonary: SARS-CoV-2 pneumonia on admission; Microbiology: bacterial cultural test from trachea and bronchi; Viral co-infection: serology and antigenic tests (see text) for associated respiratory viruses.

Abbreviations: E. Coli, Escherichia coli; Hosp. ward, hospital ward; LMWH, treatment with low molecular weight heparin; MSSA, methicillin-susceptible Staphylococcus aureus; N, patient number; OD, oxygen desaturation; OR, operatory room; Other symptoms, other symptoms or signs on admission; TL, total laryngectomy.

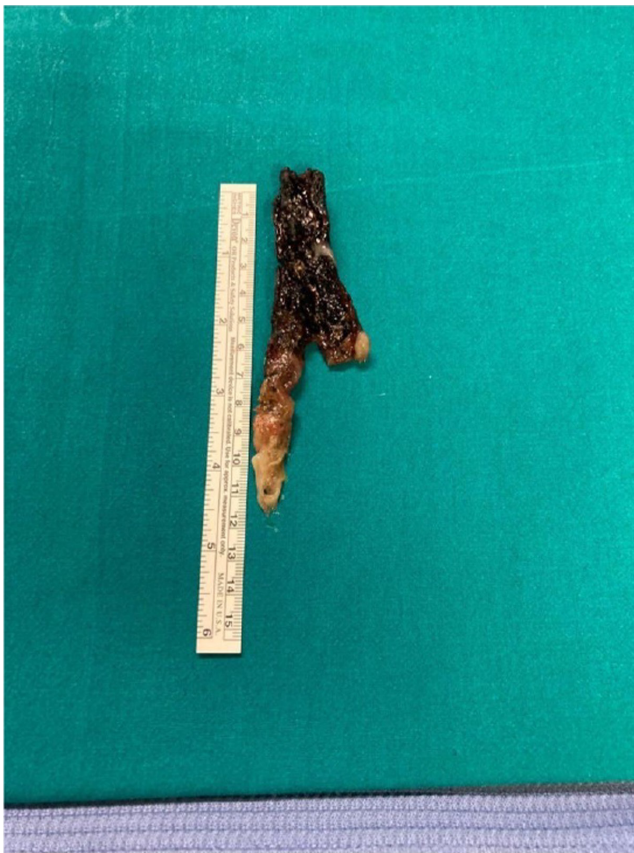involvement due to tracheal obstruction and finally the management of tracheobronchial obstruction. The latter aspect needs special attention: due to the increased aerosolising risk, laryngectomees have the potential to become 'superspreaders' and transmitting viral particles to healthcare staff.<sup>3</sup> Evidences demonstrated that multidisciplinary team members (otolaryngologists, anaesthesiologists, emergency physicians, intensivists, nurses and speech therapists) treating patients with tracheostomy are at elevated risk of COVID-19 infection, with an odds ratio of 4.2.<sup>8</sup> Tracheostomy increases risk of aerosolisation because of the shorter distance from the high viral density alveolar surface to the stoma. When the circuit is disconnected for suctioning, nebulisation of medication, or

tracheostomy tube change, they are considered high-risk aerosol-generating procedures.<sup>8</sup>

When emergency procedures related to bulky obstructing clots are required, there may be insufficient time for staff to wear appropriate personal protective equipment. Therefore, we suggest planning an elective, daily, precautionary flexible tracheoscopy, to avoid acute airway obstruction, in the setting of SARS-CoV-2-associated pneumonia. In addition, we advocate for minimised tracheal intubation where possible to further reduce tracheal complications. Human angiotensin-converting enzyme II (ACE2) has been identified as a functional receptor for SARS-CoV-2. The tracheal epithelium expresses high levels of ACE2 receptors in humans, and sustained viral replication in the tracheal epithelium has been shown in animal models.<sup>4</sup> A report by Paderno et al.<sup>9</sup> described two cases of COVID-19+ laryngectomised patients who presented with respiratory distress due to a concomitant severe pulmonary involvement and tracheal inflammation. Similar to our series, one patient had a fatal outcome and the paper focused on the potential higher risk for a worse outcome of this patient's population; evidences from the present cases allowed us to support these considerations.

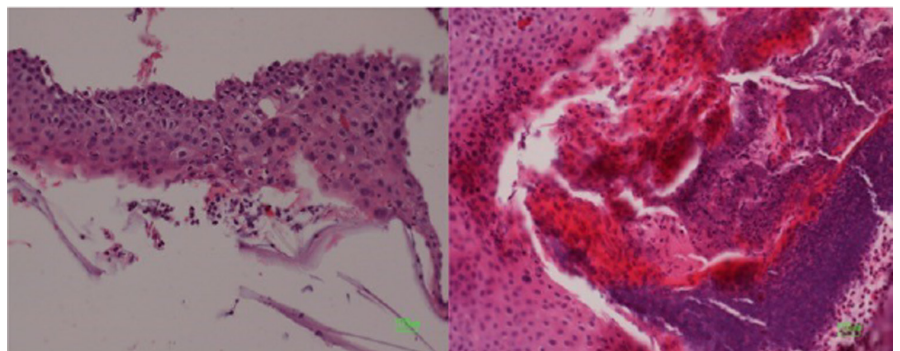
Histological samples demonstrated a diffuse inflammation along with epithelial erosion. The erosive pattern of COVID-19-related tissue damage has already been described<sup>10</sup>: two cases of ulcerative lesions of larynx and upper trachea were described in patients with a resolution of clinical, radiological and bronchoscopic respiratory disease. This histopathological aspect, along with the haemorrhagic component, could be partially responsible for the long mean duration of the disease in these patients. In the light of the histological features, we can hypothesise two mechanisms, which can play a role in the haemorrhagic phenotype. Indeed, the erosive mucosal damage associated with the endothelial dysfunction caused by SARS-CoV-2 may explain the airway bleeding in these patients, which can be exacerbated by anticoagulants. The principal differences between haemorrhagic and conventional tracheitis are the presence of easily bleeding mucosa and respiratory obstruction related mainly to blood clots (mixed with mucus and crusts) in the former entity. The clinical presentation was dyspnoea and haemoptysis from the trachea with coughing.

The present cases highlight the need for close interdisciplinary working and communication in the management of airway complications of COVID-19 infection. Careful joint planning between



**FIGURE 1** Tracheal plug. Bulky tracheal plug removed from patient #5, the procedure was performed by urgent rigid bronchoscopy

**FIGURE 2** Photomicrographs of tracheal biopsy. Tracheal biopsy, 10x magnification, haematoxylin-eosin stain. Superficial fragments of squamous epithelium with acute inflammation, neutrophilic granulocyte infiltrate and erosive aspects



anaesthesiologist, pneumologist and ENT surgeons is critical, and despite it, these patients have a high risk for poor outcome.

The main drawback of this series was the retrospective analysis. Due to the rarity of the condition, this series shares experiences from a small complex cohort who underwent heterogeneous clinical procedures, and in whom a causal effect of COVID-19, though likely, could not always be established. Nonetheless, the clinical insights and experience shared here may be important for future management seeking to avoid critical obstruction of the airway in similar patients.

## KEYWORDS

airway obstruction, case series, SARS-CoV-2, total laryngectomy, tracheitis, tracheobronchitis

## ACKNOWLEDGEMENTS

Open Access Funding provided by Università degli Studi di Modena e Reggio Emilia within the CRUI-CARE Agreement. [Correction added on 24 May 2022, after first online publication: CRUI funding statement has been added.]

## CONFLICT OF INTEREST

The authors have no conflict of interest to declare

## ETHICAL APPROVAL

Local Ethics Committee approval was obtained on December 2020 (576/2020/OSS/AOUMO)

## AUTHOR CONTRIBUTIONS

IJF and DL study design and drafting the article; FS and SV data collection; FM and GM data collection and data interpretation; AM critical review of the article from pneumological perspective.

## DATA AVAILABILITY STATEMENT

The data that support the findings of this study are available on request from the corresponding author. The data are not publicly available due to privacy or ethical restrictions.

Ignacio Javier Fernandez<sup>1</sup> 

Federico Spagnolo<sup>1</sup>

Sara Valerini<sup>1</sup>

Francesco Mattioli<sup>1</sup>

Gabriele Molteni<sup>2</sup>

Alessandro Marchioni<sup>3</sup>

Daniela Lucidi<sup>1</sup>

<sup>1</sup>Otolaryngology Head and Neck Surgery Department, University of Modena and Reggio-Emilia, Modena, Italy

<sup>2</sup>Otolaryngology Head and Neck Surgery Department, University of Verona, Verona, Italy

<sup>3</sup>Pneumology Department, University of Modena and Reggio-Emilia, Modena, Italy

## Correspondence

Ignacio Javier Fernandez, Otolaryngology Head and Neck Surgery Department, University of Modena and Reggio-Emilia, Policlinico di Modena, Via del Pozzo 71, 41124 Modena, Italy.

Emails: [ignaciojavier.fernandez@unimore.it](mailto:ignaciojavier.fernandez@unimore.it);  
[ignafernandez@yahoo.it](mailto:ignafernandez@yahoo.it)

## ORCID

Ignacio Javier Fernandez  <https://orcid.org/0000-0002-9120-6586>

## REFERENCES

- Maurizi M, Paludetti G, Almadori G, Ottaviani F, Todisco T. Mucociliary clearance and mucosal surface characteristics before and after total laryngectomy. *Acta Otolaryngol (Stockh)*. 1986;102:136-145.
- van den Boer C, van Harten MC, Hilgers FJ, van den Brekel MW, Retel VP. Incidence of severe tracheobronchitis and pneumonia in laryngectomized patients: a retrospective clinical study and a European-wide survey among head and neck surgeons. *Eur Arch Otorhinolaryngol*. 2014;271:3297-3303.
- Parrinello G, Missale F, Sampieri C, Carobbio ALC, Peretti G. Safe management of laryngectomized patients during the COVID-19 pandemic. *Oral Oncol*. 2020;107:104-142.
- Trypsteen W, Van Cleemput J, Wv S, Gerlo S, Vandekerckhove L. On the whereabouts of SARS-CoV-2 in the human body: a systematic review. *PLoS Pathog*. 2020;16(10):e1009037.
- Bradley BT, Maioli H, Johnston R, et al. Histopathology and ultrastructural findings of fatal COVID-19 infections in Washington State: a case series. *Lancet*. 2020;396:320-332.
- Verger A, Bahloul A, Melki S, et al. Tracheobronchitis signs observed on ventilation lung scintigraphy during the course of COVID-19 infection. *Eur J Nucl Med Mol Imaging*. 2020;47:2709-2710.
- Gagnier JJ, Kienle G, Altman DG, Moher D, Sox H, Riley D, CARE Group. The CARE guidelines: consensus-based clinical case report guideline development. *J Clin Epidemiol*. 2014;67:46-51.
- Meister KD, Pandian V, Hillel AT, et al. Multidisciplinary safety recommendations after tracheostomy during COVID-19 pandemic: State of the art review. *Otolaryngol Head Neck Surg*. 2020;164(5):984-1000.
- Paderno A, Fior M, Berretti G, et al. COVID-19 and total laryngectomy—a report of two cases. *Ann Otol, Rhinol Laryngol*. 2021;130:104-107.
- Oliver CM, Campbell M, Dulan O, et al. Appearance and management of COVID-19 laryngotracheitis: two case reports. *F1000Res*. 2020;29(9):310.

**How to cite this article:** Fernandez IJ, Spagnolo F, Valerini S, et al. SARS-CoV-2 tracheitis in laryngectomised patients: A consecutive case-series study. *Clin Otolaryngol*. 2022;47:203–206. <https://doi.org/10.1111/coa.13858>