


Changes in cardiac sympathetic nerve activity on ^{123}I -metaiodobenzylguanidine scintigraphy after MitraClip therapy

Keisuke Fukuda^{1*} , Seiji Hasegawa¹, Tomonori Kawamura¹, Naoto Waratani¹, Kumiko Hirata^{1,2}, Akihiro Higashimori¹ and Yoshiaki Yokoi¹

¹Department of Cardiology, Kishiwada Tokushukai Hospital, 4-27-1 Kamori-cho, Kishiwada, Osaka, 596-8522, Japan; and ²Department of Medical Science, Osaka Educational University, Osaka, Japan

Abstract

Aims In patients with heart failure, over-activation of the cardiac sympathetic nerve (CSN) function is associated with severity of heart failure and worse outcome. The effects of MitraClip therapy on the CSN activity in patients with mitral regurgitation (MR) remained unknown. In this study, we evaluated the impact of the MitraClip therapy on CSN activity assessed by ^{123}I -metaiodobenzylguanidine (MIBG) scintigraphy.

Methods and results We enrolled consecutive patients with moderate-to-severe (3+) or severe (4+) MR who were scheduled to undergo MitraClip procedure in this prospective observational study. MIBG scintigraphy was performed at baseline and 6 months after the MitraClip procedure to evaluate the heart–mediastinum ratio and washout rate (WR). Changes in these MIBG parameters were analysed. Of the 13 consecutive patients, 10 were successfully treated with MitraClip procedure and completed follow-up assessment. With regard to the MIBG parameters, changes in the early and delayed heart–mediastinum ratio from baseline to 6 months were not significant (2.16 ± 0.42 to 2.06 ± 0.34 , $P = 0.38$ and 1.87 ± 0.39 to 1.83 ± 0.39 , $P = 0.43$, respectively), whereas WR was significantly decreased ($38.6 \pm 3.9\%$ to $32.6 \pm 3.9\%$, $P = 0.002$).

Conclusions The CSN activity of the WR on MIBG imaging was improved 6 months after MitraClip therapy in patients with 3+ or 4+ MR.

Keywords Cardiac sympathetic nerve activity; MIBG scintigraphy; Mitral regurgitation; MitraClip

Received: 19 November 2020; Revised: 23 January 2021; Accepted: 4 February 2021

*Correspondence to: Keisuke Fukuda, Department of Cardiology, Kishiwada Tokushukai Hospital, 4-27-1 Kamori-cho, Kishiwada, Osaka, 596-8522, Japan.

Tel: +81-72-445-9915; Fax: +81-72-445-9793. Email: fukudateam54@gmail.com

Introduction

A dysfunction of cardiac sympathetic nerve (CSN) activity is associated with risk of serious cardiac events or death in patients with heart failure (HF).^{1,2} Cardiac ^{123}I -metaiodobenzylguanidine (MIBG) scintigraphy can non-invasively assess the CSN activity.³ Among parameters of myocardial MIBG imaging, a meta-analysis showed that a low delayed heart–mediastinum ratio (H/M) and a high washout rate (WR) were associated with a higher incidence of cardiac event and poor prognosis.^{4–6}

In patients with chronic HF, specific medical therapy and cardiac devices have contributed to the improvement in CSN activity, cardiac function, and clinical outcome.^{7–11} Recently, percutaneous mitral valve repair using MitraClip system (Abbot Vascular, Santa Clara, California) for moderate to severe (3+) or severe (4+) mitral regurgitation (MR) is relatively safe and effective in patients with HF.^{12,13} Many studies have investigated the clinical outcome, laboratory data, haemodynamic changes, or cardiac function assessed by transthoracic echocardiography (TTE) in patients who underwent the MitraClip procedure.^{14–19} However, no study

has examined the effects of MitraClip procedure on the CSN activity in patients with symptomatic MR.

The present study aimed to examine the impact of MitraClip therapy on CSN activity assessed by MIBG imaging in patients with 3+ or 4+ MR.

Methods

Patient population

The present study was a single-centre prospective observational study at Kishiwada Tokushukai Hospital. This observational study was approved by the institutional review board. All patients provided a written informed consent to undergo the interventions and the tests. A total of 13 consecutive patients with symptomatic degenerative or functional more than 3+ MR despite the use of guideline-directed medical therapy who underwent the MitraClip procedure were enrolled from December 2018 to May 2019.

The MIBG scintigraphy was performed at baseline within a week before and at 6 months after the MitraClip procedure. All patients underwent clinical examination, routine laboratory testing including plasma brain natriuretic peptide (BNP), and TTE at the same time. In addition, changes in the medications for HF, which is known to influence the CSN activity on MIBG imaging, were investigated. Patients (i) with active cancer or Parkinson's disease; (ii) taking medications known to interact with MIBG as previously described²⁰; (iii) for whom MIBG scintigraphy could not be performed; (iv) with unstable conditions, such as cardiac shock or acute decompensated HF; and (v) who were not successfully treated with MitraClip were excluded from the analysis.

MitraClip procedure

The MitraClip procedure was performed as previously described.²¹ All procedures were performed via the right femoral vein approach under general anaesthesia using transoesophageal echocardiography and fluoroscopic guidance under general anaesthesia. After trans-septal puncture, the 24-F MitraClip delivery steerable system was advanced into the left atrium. Both leaflets were grasped, and the clip was closed. Meanwhile, reduction in regurgitation severity was assessed using colour Doppler echocardiography. If the reduction in MR was inadequate with 1 clip, the same clip was repositioned or a second clip was placed.

¹²³I-metaiodobenzylguanidine scintigraphy

Anterior planer images were obtained 15 min (early) and 3 h (delayed) after intravenous injection of 111 MBq (3 mCi) of

¹²³I-MIBG with the patient resting. The images were taken by PRISM-IRIX (Picker Corp., Cleveland, Ohio/Shimadzu Corp., Kyoto), a triple headed gamma camera with a low-energy, general-purpose collimators. An experienced radiology technician who was blinded to the patients' information analysed the images based on the region of interest (ROI) to obtain the semi-quantitative parameters for tracer distribution using a smart MIBG software (Fujifilm Toyama Chemical Co.), which was developed to semi-automatically determine the H/M and correct them to the standard medium-energy collimator conditions.²² On anterior planar images, the ROIs are drawn over the heart and the mediastinum. The mean count density in each ROI is obtained and the H/M ratio is calculated. WR without background subtraction and time-decay correction was calculated as follows: early heart ROI (mean count/pixel) – delayed heart ROI (mean count/pixel)/early heart ROI (mean count/pixel) × 100. Normal values of H/M and WR in our laboratory are 2.2 and 30, respectively.

Transthoracic echocardiographic assessment

Transthoracic echocardiographic (TTE) imaging at baseline and 6 months after the MitraClip procedure were performed using a commercially available ultrasound system (Vivid E90, GE Healthcare, Chicago, Illinois). All measurements were made according to the current guidelines.²³ The severity of MR was graded as mild (1+), moderate (2+), moderate to severe (3+), or severe (4+) using the criteria of the American Society of Echocardiography.²⁴

Statistical analysis

Categorical variables were presented as counts. Continuous variables were expressed as mean ± SD or as median [interquartile range (IQR)]. Differences between baseline and post-MitraClip procedure values were analysed using the Wilcoxon signed-rank test or χ^2 test. Wilcoxon signed-rank test was used to compare the averages of continuous variables, while χ^2 test was used to compare the proportions of categorical variables between groups. A *P* value of <0.05 was considered significant. Statistical analyses were performed using JMP ver. 9.03 (SAS Institute Japan Ltd., Tokyo, Japan).

Results

Patient population

The baseline characteristics of patients are shown in *Table 1*. A total of 13 patients were enrolled in this study. MIBG

Table 1 Baseline demographics

	Total N = 10
Age (years)	83 (6)
Male	5
Body mass index (kg/m ²)	19.77 (2.7)
STS replacement mortality risk (%)	14.14 (5.6)
CSHA-CFS scale	3 (2–5.25)
Functional MR	6
Comorbidities	
Atrial fibrillation	8
Hypertension	7
Diabetes mellitus	1
Dyslipidaemia	3
Myocardial infarction	0
Prior stroke	1
Chronic kidney disease	7
COPD	0
NYHA functional class	
I	0
II	2
III	5
IV	3
Treatment history	
Previous PCI	1
Previous CABG	1
Previous CRT	0
Medications	
Beta-blocker	6
ACEI/ARB	6
Aldosterone antagonist	5
Diuretics	8

Values are *n*, mean (SD), or median (25th–75th percentile). ACEI/ARB, angiotensin-converting enzyme inhibitor/angiotensin II receptor blocker; CABG, coronary artery bypass grafting; CFS, clinical frailty scale; COPD, chronic obstructive pulmonary disease; CRT, cardiac resynchronization therapy; CSHA, Canadian Study of Health and Aging; MR, mitral regurgitation; NYHA, New York Heart Association; PCI, percutaneous coronary intervention; STS, Society of Thoracic Surgery coronary.

scintigraphy could not be performed in three patients due to the following reasons: procedural complications such as single leaflet detachment (*n* = 1), death during follow-up (*n* = 1), and inability to visit the hospital (*n* = 1). Finally, 10 patients (mean age: 83(6) years, 4 male) successfully treated with MitraClip procedure completed 6 months of follow-up assessment and MIBG scintigraphy. Medication changes in all class were not significant between baseline and at 6 months follow-up. No cardiac devices were newly implanted, and no patients had new-onset or developed coronary artery disease in the follow-up period.

Changes in clinical, laboratory, and transthoracic echocardiographic data 6 months after MitraClip procedure

Changes in clinical, laboratory, and TTE data are shown in *Table 2*. All patients significantly improved in New York Heart Association (NYHA) functional class after the MitraClip procedure. There were no significant changes in BNP from baseline

Table 2 Changes after MitraClip

	N = 10 Baseline	N = 10 6 months	P value
NYHA classification III to IV	8	2	0.02
MR grade	3 (3–4)	2 (1–2)	0.01
Medications			
Beta-blocker	6	6	1.00
ACEI/ARB	6	6	1.00
Aldosterone antagonist	5	5	1.00
Diuretic	8	9	1.00
Cardiac devices			
CRT	0	0	1.00
Laboratory data			
Haemoglobin (g/dL)	11.6 (1.7)	12.0 (2.0)	0.33
eGFR (mL/min/1.73 m ²)	46.9 (16.6)	46.8 (17.87)	0.96
BNP level (pg/mL)	390.6 (287.3)	402.1 (256.5)	0.85
Transthoracic echocardiographic data			
EF (%)	50.4 (13.6)	48.4 (8.7)	0.47
LA diameter (mm)	51 (6.7)	51 (8.8)	0.87
LVDd (mm)	53.9 (9.8)	52.7 (8.7)	0.52
LVDs (mm)	39.3 (10.5)	39.5 (9.2)	0.86
LVEDV (mL)	109.9 (47.4)	101.9 (48.1)	0.22
LVESV (mL)	57.3 (36.3)	54.4 (31.7)	0.42
CO (L/min)	4.9 (1.3)	4.46 (1.7)	0.56
CI (L/min/m ²)	3.4 (0.9)	3.1 (1.0)	0.63
RVP (mmHg)	35 (13)	32 (11)	0.55

Values are *n*, mean (SD), or median (25th–75th percentile).

BNP, brain natriuretic peptide; CI, cardiac index; CO, cardiac output; EF, ejection fraction; eGFR, estimated glomerular filtration rate; LA, left atrium; LVDd, left ventricular end-diastolic diameter; LVDs, left ventricular end-systolic diameter; LVEDV, left ventricular end-diastolic volume; LVESV, left ventricular end-systolic volume; RVP, right ventricular pressure; other abbreviations as in *Table 1*.

to 6 months (390.6 ± 287.3 pg/mL to 402.1 ± 256.6 pg/mL, $P = 0.85$). As measured by TTE, the severity of MR were significantly improved at 6 months follow-up (3 [IQR: 3–4] to 2 [IQR: 1–2]; $P = 0.012$), whereas the size of left atrium (LA) and left ventricle (LV) and results of LV functional assessment were not significantly changed.

Changes in ¹²³I-metaiodobenzylguanidine parameters

Figure 1 shows a representative image of improvement in CSN activity on MIBG imaging at baseline and 6 months after MitraClip procedure in 86-year-old women with severe degenerative MR who successfully underwent MitraClip procedure.

Compared between baseline and follow-up, all injection-acquisitions delays were within 5 min in early and delayed image at both baseline and follow-up. MIBG parameters at baseline and at 6 months after the MitraClip procedure are shown in *Table 3* and *Figure 2*. Both early and delayed H/M did not significantly changed (2.16 ± 0.42 to 2.06 ± 0.34 , $P = 0.38$ and 1.87 ± 0.39 to 1.83 ± 0.39 , $P = 0.43$, respectively), whereas WR was significantly decreased ($38.6 \pm 3.9\%$ to $32.6 \pm 3.94\%$, $P = 0.002$) from baseline to 6 months.

Figure 1 Cardiac sympathetic nerve activity on ¹²³I-metaiodobenzylguanidine (MIBG) image at baseline (left side) and 6 months (right side). Improvement of cardiac sympathetic nerve activity on MIBG after MitraClip therapy.

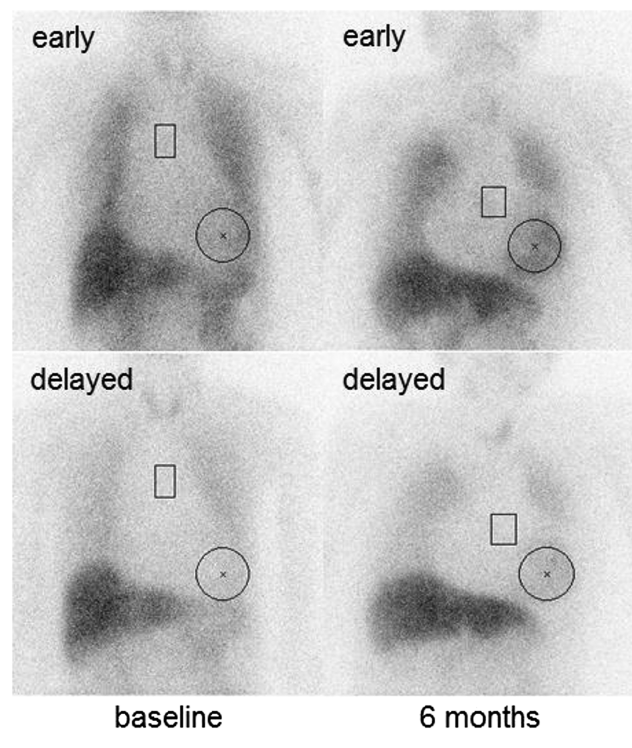


Table 3 Changes in MIBG parameters (N = 10)

		Baseline N = 10	6 months N = 10	P value
MIBG	Early H/M	2.16 (0.42)	2.06 (0.34)	0.38
	Delayed H/M	1.8 (0.39)	1.83 (0.39)	0.43
	WR	38.6 (3.9)	32.6 (3.94)	<0.01

Values are mean (SD).

H/M, heart–mediastinum ratio; WR, washout rate.

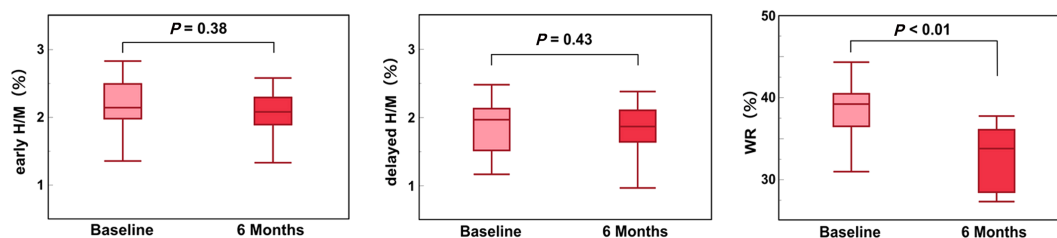
Discussion

This study investigated the changes in the CSN activity assessed by MIBG imaging 6 months after MitraClip procedure in patients with grade 3+ or 4+ MR. Our findings showed a significant improvement in the CSN activity as a decreased in WR in patients who underwent MitraClip procedure.

Two large randomized trials of transcatheter mitral valve repair with MitraClip system for MR reported that MitraClip is a safe procedure, can help reduce MR, and can improve the clinical outcomes.^{12,13} Many studies including those two trials investigated the HF symptoms, haemodynamic changes, cardiac function assessed by echocardiogram, and prognosis of patients who underwent MitraClip procedure. On the contrary, studies on the CSN activity in MR or the impact on CSN activity after treatment for MR are limited.^{25–28} Moreover, no studies have investigated the CSN activity in patients who underwent MitraClip procedure. To the best of our knowledge, this is the first study to report the impact of the after MitraClip procedure on the CSN activity.

In MIBG parameters, a delayed H/M reflects CSN terminal function and WR reflects retention of norepinephrine by sympathetic neurons, indicating sympathetic nerve tone.¹ A low delayed H/M is associated with a higher incidence of cardiac events but not with cardiac death. A higher WR is associated with both cardiac death and cardiac events in patients with HF.⁴ The H/M ratio and WR were significantly correlated with left atrial (LA) dimension in patients with mitral valve prolapse.²⁹ Moreover, delayed H/M was significantly decreased in MR patients compared with no MR patients and increased WR and CSN activity was positively correlated with cardiac index (CI) but negatively correlated with pulmonary capillary wedge pressure, LV ejection fraction (LVEF), and LV volume indexes.²⁶ Our findings demonstrated that the WR had significantly ameliorated 6 months after MitraClip procedure, whereas LA dimension, LVEF, LV end-diastolic volume, and end-systolic volume did not show a significant improvement. However, in LVEF, cardiac output, and CI, decreasing trends might be consistent with the early effects of increased

Figure 2 Changes in ¹²³I-metaiodobenzylguanidine parameters. Washout rate (WR) was significantly decreased (P < 0.01). H/M, heart–mediastinum ratio.



afterload after MR reduction.^{30,31} In our study, CI was calculated by echocardiography, but a change in the precise CI was not known because catheterization was not performed.

Improvements of delayed H/M after drug therapeutic intervention were more described in several studies than improvement of WR.^{32,33} There was a discrepancy between those studies and our result. One interpretation is that pharmacological intervention is more likely to improve the CSN terminal function reflected by a delayed H/M than the CSN tone reflected by WR. It suggests that there are differences in the effect on the CSN activity between haemodynamic improvement of MR and pharmacological intervention to HF. However, our studies included too small number of patients to identify the mechanism for the changes in MIBG parameters. Thus, the underlying mechanisms for an improved WR but not improved delayed H/M due to a reduction in MR after MitraClip procedure remained unclear.

The pathophysiology of HF due to either degenerative or functional MR is very complex, implying that the practical severity in patients with MR cannot be simply assessed by haemodynamic parameters, echocardiographic findings, or biomarkers. Moreover, patients who are candidates for MitraClip procedure often have multiple comorbidities or take optimized drugs for HF. Therefore, the CSN activity easily assessed by MIBG parameters can comprehensively evaluate the severity of HF, risk stratification, and the therapeutic effect of MitraClip procedure. The clinical benefit of improving the MIBG parameters remains unclear. However, angiotensin-converting enzyme inhibitors, beta-receptor antagonists, spironolactone, and cardiac resynchronization therapy have shown to improve the cardiac function and prognosis. These beneficial effects were associated with an increased H/M and a decreased WR.^{7–11} Thus, the degree of improvement in MIBG parameters by the MitraClip procedure for MR might predict the positive effect on prognosis. In patients with HF due to MR, MIBG scintigraphy may be useful in evaluating the effectiveness and the risk for cardiovascular events after MitraClip therapy.

Our study has several limitations. First, we only analysed a small number of patients and a single side character. The presented results, therefore, are insufficient to understand the precise mechanisms of the change of CSN activity in patients who underwent the MitraClip procedure. In addition, we did not perform single-photon emission computed tomography. This investigation could give us further information to understand better the role of innervation in MR. The correlation between the impact of medications known to influence on the CSN activity and the effect of a reduction of MR was unclear. Second, this study included both degenerative and functional MR. The differences in the aetiology of MR might provide different effects of MR reduction on the cardiac function or the CSN activity. Third, the results of a longer term follow-up were not evaluated, and the duration of the beneficial effects of the MitraClip procedure on the CSN activity were unclear. Further studies of greater patient numbers and a longer follow-up time are needed to clarify the effect of MitraClip procedure on CSN activity in degenerative or functional MR and association with clinical benefit of the improvement in CSN activity by MitraClip therapy.

Conclusion

In patients with HF due to MR, the CSN activity assessed by MIBG imaging improved as the WR decreased after the MitraClip procedure for 3+ or 4+ MR, whereas echocardiographic findings or biomarkers did not improve.

Conflict of interest

None declared.

References

- Carrió I, Cowie MR, Yamazaki J, Udelson J, Camici PG. Cardiac sympathetic imaging with *m*IBG in heart failure. *JACC Cardiovasc Imaging* 2010; **3**: 92–100.
- Shah AM, Bourgoun M, Narula J, Jacobson AF, Solomon SD. Influence of ejection fraction on the prognostic value of sympathetic innervation imaging with iodine-123 MIBG in heart failure. *JACC Cardiovasc Imaging* 2012; **5**: 1139–1146.
- Patel AD, Iskandrian AE. MIBG imaging. *J Nucl Cardiol* 2002; **9**: 75–94.
- Verberne HJ, Brewster LM, Somsen GA, van Eck-Smit BL. Prognostic value of myocardial ¹²³I-metaiodobenzylguanidine (MIBG) parameters in patients with heart failure: a systematic review. *Eur Heart J* 2008; **29**: 1147–1159.
- Jacobson AF, Senior R, Cerqueira MD, Wong ND, Thomas GS, Lopez VA, Agostini D, Weiland F, Chandna H, Narula J, ADMIRE-HF Investigators. Myocardial iodine-123 metaiodobenzylguanidine imaging and cardiac events in heart failure. Results of the prospective ADMIRE-HF (AdreView Myocardial Imaging for Risk Evaluation in Heart Failure) study. *J Am Coll Cardiol* 2010; **55**: 2212–2221.
- Nakata T, Nakajima K, Yamashina S, Yamada T, Momose M, Kasama S, Matsui T, Matsuo S, Travin MI, Jacobson AF. A pooled analysis of multicenter cohort studies of ¹²³I-*m*IBG imaging of sympathetic innervation for assessment of long-term prognosis in heart failure. *JACC Cardiovasc Imaging* 2013; **6**: 772–784.
- Nakata T, Wakabayashi T, Kyuma M, Takahashi T, Tsuchihashi K, Shimamoto K. Cardiac metaiodobenzylguanidine activity can predict the long-term efficacy of angiotensin-converting enzyme inhibitors and/or beta-adrenoceptor blockers

- in patients with heart failure. *Eur J Nucl Med Mol Imaging* 2005; **32**: 186–194.
8. Kasama S, Toyama T, Kumakura H, Takayama Y, Ichikawa S, Suzuki T, Kurabayashi M. Spironolactone improves cardiac sympathetic nerve activity and symptoms in patients with congestive heart failure. *J Nucl Med* 2002; **43**: 1279–1285.
 9. Erol-Yilmaz A, Verberne HJ, Schrama TA, Hrudova J, de Winter RJ, van Eck-Smit BL, de Bruin R, Bax JJ, Schalij MJ, Wilde AA, Tukkie R. Cardiac resynchronization induces favorable neurohumoral changes. *Pacing Clin Electrophysiol* 2005; **28**: 304–310.
 10. Nishioka SA, Martinelli Filho M, Brandão SC, Giorgi MC, Vieira ML, Costa R, Mathias W, Meneghetti J. Cardiac sympathetic activity pre and post resynchronization therapy evaluated by 123I-MIBG myocardial scintigraphy. *J Nucl Cardiol* 2007; **14**: 852–859.
 11. Curcio A, Cascini GL, De Rosa S, Pasceri E, Veneziano C, Cipullo S, Saccomanno M, Santarpia G, Cuda G, Indolfi C. ¹²³I-MIBG imaging predicts functional improvement and clinical outcome in patients with heart failure and CRT implantation. *Int J Cardiol* 2016; **207**: 107–109.
 12. Feldman T, Kar S, Elmariyah S, Smart SC, Trento A, Siegel RJ, Apruzzese P, Fail P, Rinaldi MJ, Smalling RW, Hermiller JB, Heimansohn D, Gray WA, Grayburn PA, Mack MJ, Lim DS, Ailawadi G, Herrmann HC, Acker SA, Silvestry FE, Foster E, Wang A, Glower DD, Mauri L, EVEREST II Investigators. Randomized comparison of percutaneous repair and surgery for mitral regurgitation: 5-year results of EVEREST II. *J Am Coll Cardiol* 2015; **66**: 2844–2854.
 13. Stone GW, Lindenfeld J, Abraham WT, Kar S, Lim DS, Mishell JM, Whisenant B, Grayburn PA, Rinaldi M, Kapadia SR, Rajagopal V, Sarembok IJ, Brieke A, Marx SO, Cohen DJ, Weissman NJ, Mack MJ. Transcatheter mitral-valve repair in patients with heart failure. *N Engl J Med* 2018; **379**: 2307–2318.
 14. Foster E, Kwan D, Feldman T, Weissman NJ, Grayburn PA, Schwartz A, Rogers JH, Kar S, Rinaldi MJ, Fail PS, Hermiller J, Whitlow PL, Herrmann HC, Lim DS, Glower DD, EVEREST Investigators. Percutaneous mitral valve repair in the initial EVEREST cohort: evidence of reverse left ventricular remodeling. *Circ Cardiovasc Imaging* 2013; **6**: 522–530.
 15. Lim DS, Reynolds MR, Feldman T, Kar S, Herrmann HC, Wang A, Whitlow PL, Gray WA, Grayburn P, Mack MJ, Glower DD. Improved functional status and quality of life in prohibitive surgical risk patients with degenerative mitral regurgitation after transcatheter mitral valve repair. *J Am Coll Cardiol* 2014; **64**: 182–192.
 16. Barth S, Hautmann MB, Kerber S, Gietzen F, Zacher M, Halbfass P, Müller P, Schade A, Deneke T, Diegeler A, Schieffer B, Hamm K. Hemodynamic improvement at three months after MitraClip® treatment in end-stage heart failure patients with functional mitral regurgitation. *J Heart Valve Dis* 2016; **25**: 475–482.
 17. Patzelt J, Zhang Y, Magunia H, Jorbenadze R, Droppa M, Ulrich M, Cai S, Lausberg H, Walker T, Wengenmayer T, Rosenberger P, Schrieck J, Seizer P, Gawaz M, Langer HF. Immediate increase of cardiac output after percutaneous mitral valve repair (PMVR) determined by echocardiographic and invasive parameters: Patzelt: increase of cardiac output after PMVR. *Int J Cardiol* 2017; **236**: 356–362.
 18. Kaneko H, Neuss M, Weissenborn J, Butter C. Role of right ventricular dysfunction and diabetes mellitus in N-terminal pro-B-type natriuretic peptide response of patients with severe mitral regurgitation and heart failure after MitraClip. *Int Heart J* 2017; **58**: 225–231.
 19. Avenatti E, Little SH, Barker CM, Nagueh SF. Changes in left atrial function after transcatheter mitral valve repair. *Am J Cardiol* 2018; **122**: 1204–1209.
 20. Feldman T, Kar S, Rinaldi M, Fail P, Hermiller J, Smalling R, Whitlow PL, Gray W, Low R, Herrmann HC, Lim S, Foster E, Glower D, EVEREST Investigators. Percutaneous mitral repair with the MitraClip system: safety and midterm durability in the initial EVEREST (Endovascular Valve Edge-to-Edge Repair Study) cohort. *J Am Coll Cardiol* 2009; **54**: 686–694.
 21. Stefanelli A, Treglia G, Bruno I, Rufini V, Giordano A. Pharmacological interference with ¹²³I-metaiodobenzylguanidine: a limitation to developing cardiac innervation imaging in clinical practice? *Eur Rev Med Pharmacol Sci* 2013; **17**: 1326–1333.
 22. Okuda K, Nakajima K, Hosoya T, Ishikawa T, Konishi T, Matsubara K, Matsu S, Kinuya S. Semi-automated algorithm for calculating heart-to-mediastinum ratio in cardiac iodine-123 MIBG imaging. *J Nucl Cardiol* 2011; **18**: 82–89.
 23. Lang RM, Badano LP, Mor-Avi V, Afilalo J, Armstrong A, Ernande L, Flachskampf FA, Foster E, Goldstein SA, Kuznetsova T, Lancellotti P, Muraru D, Picard MH, Rietzschel ER, Rudski L, Spencer KT, Tsang W, Voigt JU. Recommendations for cardiac chamber quantification by echocardiography in adults: an update from the American Society of Echocardiography and the European Association of Cardiovascular Imaging. *J Am Soc Echocardiogr* 2015; **28**: 1–39.
 24. Zoghbi WA, Enriquez-Sarano M, Foster E, Grayburn PA, Kraft CD, Levine RA, Nihoyannopoulos P, Otto CM, Quinones MA, Rakowski H, Stewart WJ, Waggoner A, Weissman NJ, American Society of Echocardiography. Recommendations for evaluation of the severity of native valvular regurgitation with two-dimensional and Doppler echocardiography. *J Am Soc Echocardiogr* 2003; **16**: 777–802.
 25. Imamura Y, Ando H, Mitsuoka W, Egashira S, Masaki H, Ashihara T, Fukuyama T. Iodine-123 metaiodobenzylguanidine images reflect intense myocardial adrenergic nervous activity in congestive heart failure independent of underlying cause. *J Am Coll Cardiol* 1995; **26**: 1594–1599.
 26. Tsutsui H, Ando S, Kubota T, Kuroiwa-Matsumoto M, Egashira K, Sasaki M, Kuwabara Y, Koyanagi S, Yasui H, Takeshita A. Abnormalities of cardiac sympathetic neuronal and left ventricular function in chronic mitral regurgitation: assessment by iodine-123 metaiodobenzylguanidine scintigraphy. *Am J Card Imaging* 1996; **10**: 14–22.
 27. Kishi F, Nomura M, Uemura E, Kageyama N, Kujime S, Kaji M, Noda Y, Kondo N, Kawaguchi T, Ozaki Y, Koshiba K, Yamaguchi K, Nakaya Y, Ito S. Evaluation of myocardial sympathetic nerve function in patients with mitral valve prolapse using iodine-123-metaiodobenzylguanidine myocardial scintigraphy. *J Med* 2004; **35**: 187–199.
 28. Grossman PM, Linares OA, Supiano MA, Oral H, Mehta RH, Starling MR. Cardiac-specific norepinephrine mass transport and its relationship to left ventricular size and systolic performance. *Am J Physiol Heart Circ Physiol* 2004; **287**: H8788–H8788.
 29. Terada K, Sugihara H, Shiga K, Ohtsuki K, Ito K, Taniguchi Y, Azuma A, Kohno Y, Miyao K, Nakagawa M. Clinical evaluation of ¹²³I-metaiodobenzylguanidine myocardial scintigram in patients with valvular heart disease. *J Cardiol* 1995; **25**: 247–253 [Article in Japanese].
 30. Asch FM, Grayburn PA, Siegel RJ, Kar S, Lim DS, Zaroff JG, Mishell JM, Whisenant B, Mack MJ, Lindenfeld J, Abraham WT, Stone GW, Weissman NJ, COAPT Investigators. Echocardiographic outcomes after transcatheter leaflet approximation in patients with secondary mitral regurgitation: the COAPT trial. *J Am Coll Cardiol* 2019; **74**: 2969–2979.
 31. Suri RM, Schaff HV, Dearani JA, Sundt TM 3rd, Daly RC, Mullany CJ, Sarano ME, Orszulak TA. Determinants of early decline in ejection fraction after surgical correction of mitral regurgitation. *J Thorac Cardiovasc Surg* 2008; **136**: 442–447.
 32. Somsen GA, van Vlies B, de Milliano PA, Borm JJ, van Royen EA, Ender E, Lie KI. Increased myocardial [123I]-metaiodobenzylguanidine uptake after enalapril treatment in patients with chronic heart failure. *Heart* 1996; **76**: 218–222.
 33. Cohen-Solal A, Rouzet F, Berdeaux A, Le Guludec D, Abergel E, Syrota A, Merlet P. Effects of carvedilol on myocardial sympathetic innervation in patients with chronic heart failure. *J Nucl Med* 2005; **46**: 1796–1803.