

Oncology

Embolization of an angiomyolipoma in a crossed fused renal ectopia

Waseem Tayeb^{a,*}, Raghad Aldibane^b, Almamoon Justaniah^c, Hattan Badr^a^a Department of Surgery, Division of Urology, King Abdullah Medical City, Makkah, Saudi Arabia^b Umm Al-Qura University, Makkah, Saudi Arabia^c Department of Medical Imaging and Intervention, King Abdullah Medical City, Makkah, Saudi Arabia

ARTICLE INFO

Keywords:

Angiomyolipoma
Crossed fused ectopia
Partial nephrectomy
Case report

ABSTRACT

: Crossed fused ectopic kidney represents a rare congenital malformation, and development of an angiomyolipoma (AML) in a crossed fused ectopia is even rarer. There is no clear association between both entities. However, approximately half of crossed fused renal ectopic patients may develop infections, obstruction and/or nephrolithiasis. Nevertheless, they are very rarely associated with carcinoma. To our knowledge, this is the first case of AML in crossed fused renal ectopia. In this report, we present a patient with a left renal angiomyolipoma in a crossed fused renal ectopia managed by embolization. In addition, a literature review for relevant cases will be provided.

Introduction

Crossed fused ectopic kidney is a rare congenital malformation with a prevalence of 1 in 1000 live births. Both kidneys are located on one side of the midline and often fused with inferior ectopia. Since most patients are asymptomatic, renal angiomyolipoma (AML) most often seen in autopsy with a varying incidence of 1 in 2000 to 1 in 7500. However, it can also be found in different ways in clinical practice,¹ with a male predominance of 3:2. In most instances, the left kidney is crossed and merged with the right kidney between the lower pole of the orthotopic kidney and the superior pole of the ectopic kidney. Fusion anomalies of the kidney are rarely associated with benign or malignant renal tumors.² There is no clear association between AML and crossed fused ectopic kidney, which is usually managed by nephron-sparing surgery. In this report, we present a patient with a left renal angiomyolipoma in a crossed fused renal ectopia with literature review.

Case presentation

A 45-year-old non-smoker female was referred to a tertiary care center with an incidentally discovered left renal mass in a crossed fused renal ectopia. The patient reported a history of an intermittent left loin pain for 6 months, with irrelevant medical and surgical history. There were no constitutional symptoms, family history of malignancy or similar congenital anomalies. General physical examination and routine laboratory workup were within the normal range. The serum creatinine

was 0.75 mg/dL and hemoglobin level was 13.3 g/dL. All vital signs were within average and the patients was clinically free.

A hyperechoic mass was seen on ultrasound, which was further evaluated by a contrast-enhanced computed tomography (CT). The CT revealed a 10 × 10 × 9.7 cm non-enhanced hyperdense heterogeneous mass arising from the left superior pole of a crossed fused renal ectopia, with HU of less than −20. This exophytic mass encased one of the pelvic calyces, consistent with AML. There was no evidence of hydronephrosis or obstructive uropathy (Fig. 1). After consulting Interventional Radiology, the consensus was to proceed with embolization. Under local anesthesia, a left renal arteriogram was performed via a right common femoral arterial approach. The arteriogram demonstrated the large AML supplied by a second order branch from the superior renal artery, with no renal parenchymal supply (Fig. 2). Therefore, a super-selective embolization was performed. Post embolization arteriogram was performed demonstrating complete embolization of the AML with preservation of the renal parenchyma (Fig. 2). The patient tolerated the procedure without adverse events and discharged in a good general condition, with stable vital signs. On a 3-month follow up, the patient reported no complaint, with a serum creatinine of 0.73 mg/dL. A follow-up CT scan revealed reduction in the AML size which measured 7.6 × 7 × 6 cm (Fig. 3).

Discussion

Crossed fused renal ectopia occurs secondary to failure of both

* Corresponding author. Department of Surgery, Division of Urology King Abdullah Medical City at Holy Capital, Makkah, Saudi Arabia.

E-mail address: waseemtayeb@yahoo.com (W. Tayeb).

<https://doi.org/10.1016/j.eucr.2020.101297>

Received 28 May 2020; Received in revised form 8 June 2020; Accepted 10 June 2020

Available online 10 June 2020

2214-4420/© 2020 The Authors.

Published by Elsevier Inc.

This is an open access article under the CC BY-NC-ND license

(<http://creativecommons.org/licenses/by-nc-nd/4.0/>).

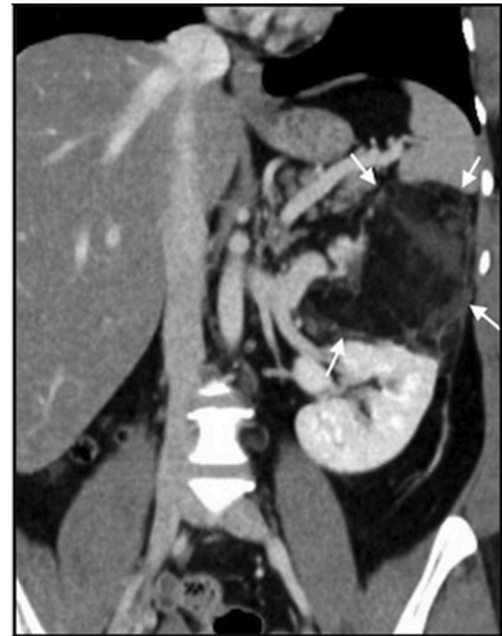
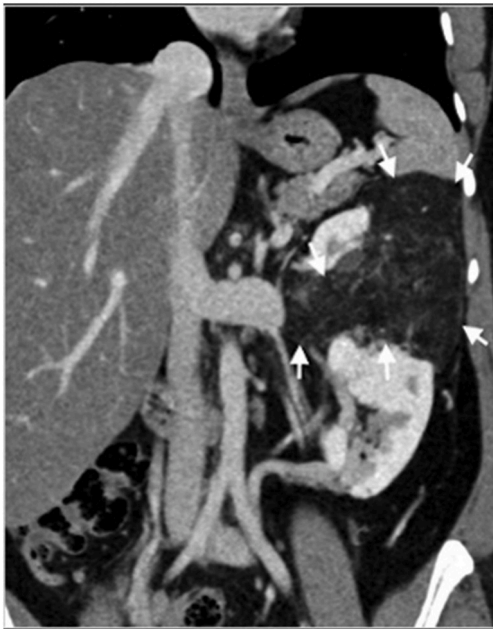


Fig. 1. Pre-procedural Coronal CT with IV contrast in the venous phase demonstrating a hypodense, fat predominant, enhancing mass in the superior pole of the left crossed fused ectopic kidney, measuring 10 × 10 × 9.7 cm (arrows).

Fig. 3. 3-Month follow up coronal CT image with IV contrast in the venous phase demonstrating reduction in the AML size. Note the preserved normal enhancement of the renal parenchyma.

kidneys to ascend to their normal position. It seems to result from aberrant development of the metanephric blastema and the ureteric bud during the 4th to 8th week of gestation. The precise occurrence of cross fused renal ectopia has not been known since the vast majority of patients are asymptomatic, but hypertension has been documented in some cases.

It represents a clinically important entity, where approximately half of patients may develop complications, such as infections (pyelonephritis), obstruction (hydronephrosis) and nephrolithiasis, but they are very rarely associated with carcinoma.^{1,3} Despite renal AMLs are more likely to grow, most of them can be treated by active surveillance,⁴ depending on tumor size and symptoms.⁵ Tumors that are symptomatic or have a hemorrhagic potential require either selective embolization or surgical intervention such as partial nephrectomy, enucleation or wedge resection. Observation with interval follow-up CT scans or ultrasound

imaging is the conservative treatment of choice for asymptomatic tumors unless malignancy is suspected.⁵ The mainstream of renal AML treatment is selective embolization, which is usually less morbid and associated with minimal postoperative adverse events when compared with surgical approaches. The rates of post-embolization syndrome, including fever and flank pain, were significantly low, but they are common and can be treated conservatively.⁴ Furthermore, no deaths have been reported in relation to embolization therapy, and renal function remains almost unaltered after the intervention.

Alternatively, a partial nephrectomy approach has higher complication rates, but it is related with a lower incidence of recurrence.⁵ In this index case, a super-selective embolization of the second order branch from superior left renal artery was performed due to the large tumor size and for the optimal preservation of renal function in crossed fused ectopic kidney.

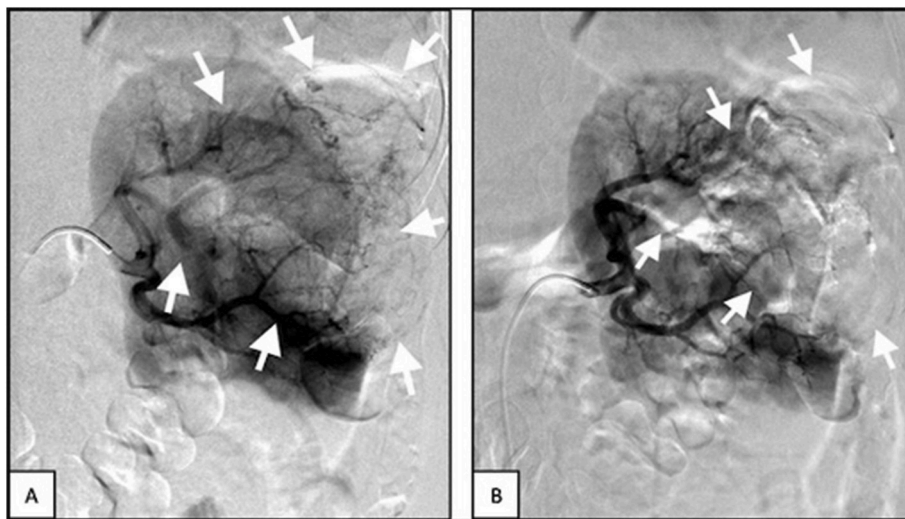


Fig. 2. Digital subtraction arteriography of the left kidney demonstrating the AML with abnormal arteries (A) (arrows). Post embolization arteriogram demonstrating lack of enhancement of the AML with preservation of the renal parenchymal enhancement (B).

Conclusion

Renal angiomyolipoma is a benign kidney tumor that doesn't have clear correlation with crossed fused ectopic kidney. Super-selective embolization of segmental arteries supplying the lesion is known to be the effective and minimally invasive. It is well tolerated and is associated with minor complications, despite the recurrent relapses relative to the surgical alternatives. To our knowledge, this is the first case of an AML in crossed fused ectopic kidney.

Consent form

A written consent was obtained from the patient for publication of

this case report and accompanying images.

References

1. Bhattar R, Maheshwari A, Tomar V, Yadav SS. Crossed fused ectopic kidney: a case report. *J Clin Diagn Res.* 2017;11(8):PD11–P12.
2. Modi P, Rizvi SJ, Gupta R, Patel S. Retroperitoneoscopic nephrectomy for crossed-fused ectopic kidney. *Indian J Urol.* 2009;25(3):401–403.
3. Shaikh TP, Ansari S, Vu T, Mandhane N, Karandikar S. Cross fused ectopic kidney a rare congenital malformation with review of literature. *Int J Sci Rep.* 2015;1(3).
4. Wang SF, Lo WO. Benign neoplasm of kidney: angiomyolipoma. *J Med Ultrasound.* 2018;26(3):119–122.
5. Urciuoli P, D'Orazi V, Livadoti G, et al. Treatment of renal angiomyolipoma: surgery versus angioembolization. *G Chir.* 2013;34(11-12):326–331.