

Review Article

Operative Strategy of Ruptured Abdominal Aortic Aneurysms and Management of Postoperative Complications

Hiroyuki Ito, MD, PhD

In addition to traditional open surgical repair (OSR), endovascular aneurysm repair (EVAR) is currently another strong option to treat RAAA. All vascular surgeons who try to save RAAA patients must be deeply versed in both OSR and EVAR. In this article, current trend of RAAA treatment and abdominal compartment syndrome, which has been most important postoperative complication, are reviewed. (This is a translation of *Jpn J Vasc Surg* 2019; 28: 127–132.)

Keywords: abdominal aortic aneurysm, ruptured, endovascular surgery, stent graft, compartment syndrome

Introduction

Ruptured abdominal aortic aneurysm (RAAA) is a life-threatening condition that often results in a fatal outcome within a short period of time after a rupture. In principle, the only life-saving treatment for RAAA is emergency surgery; however, the outcome of surgical therapy remains unsatisfactory with reported postoperative mortality rates ranging from 30% to 70%. Moreover, the overall mortality of RAAA reportedly exceeds 80%¹⁾ when deaths before arrival at hospitals and postmortem diagnoses of

RAAA are included.

In the present article, we described emergency treatment methods, global trends in RAAA treatment, management of abdominal compartment syndrome (ACS) as an important postoperative complication, and lastly we discussed the prognostic prediction of RAAA.

Therapeutic Modalities for RAAA

Preoperative management in the emergency unit

While open surgical repair (OSR) remains the primary modality for emergency treatment of RAAA, emergency endovascular aneurysm repair (EVAR) is also performed now in several institutions across Japan. In Europe and the United States, the effectiveness of emergency EVAR for RAAA has been recognized earlier, and improvements in treatment for RAAA outcomes by EVAR have already been noted in the early 2000s.^{2,3)}

For diagnosing RAAA, plain computed tomography (CT) is practically enough, and it is possible to determine device sizing for performing EVAR. In patients with hemodynamic instability, the use of contrast agents should be avoided because they increase the risk of postoperative renal failure. In patients with stable hemodynamics, contrast-enhanced CT can provide information that facilitates EVAR.


Notably, sudden deterioration in hemodynamics immediately after CT scan are often encountered; therefore, multiple physicians capable of cardiopulmonary resuscitation should be available while examinations are in progress.

As preoperative management, the general condition should be maintained at a blood pressure as low as possible (systolic pressure: 70–90 mmHg) until the proximal neck of the aortic aneurysm is successfully controlled because excessive catecholamine administration, blood transfusion, and fluid replacement are likely to worsen bleeding from the aortic aneurysm.⁴⁾ The latest Society for Vascular Surgery (SVS) guideline recommends that door-to-intervention time be set within 90 min.⁵⁾

At advanced emergency units, aortic blockage balloons,

Division of Vascular Surgery, Cardiovascular and Aortic Center, Saiseikai Fukuoka General Hospital, Fukuoka, Fukuoka, Japan

Received: June 2, 2019; Accepted: June 4, 2019
Corresponding author: Hiroyuki Ito, MD, PhD. Division of Vascular Surgery, Cardiovascular and Aortic Center, Saiseikai Fukuoka General Hospital, 1-3-46 Tenjin, Chuo-ku, Fukuoka, Fukuoka 810-0001, Japan
Tel: +81-92-771-8151, Fax: +81-92-716-0185
E-mail: ito-hiroyuki@saiseikai-hp.chuo.fukuoka.jp
This is a translation of *Jpn J Vasc Surg* 2019; 28: 127–132.

 ©2019 The Editorial Committee of Annals of Vascular Diseases. This article is distributed under the terms of the Creative Commons Attribution License, which permits use, distribution, and reproduction in any medium, provided the credit of the original work, a link to the license, and indication of any change are properly given, and the original work is not used for commercial purposes. Remixed or transformed contributions must be distributed under the same license as the original.

which are relatively easy to insert, are often used in conditions such as traumatic intraperitoneal hemorrhage to achieve temporary hemostasis; however, wiring through the aortic aneurysm and proximal neck is often difficult even under fluoroscopy in RAAA cases because of large size of RAAA and the tortuosity of the aorta. Therefore, aortic blockage balloons should always be inserted under fluoroscopic guidance, and should never be inserted blindly.

OSR for RAAA

In principle, OSR is the gold standard treatment for RAAA. First, the patient undergoes disinfection of the abdomen and chest, is covered with surgical drapes, and at the same time, is anesthetized for immediate start of surgery.

Transperitoneal approach via abdominal midline incision is usually chosen as a method to reach standard infrarenal RAAAs described in this section. Extraperitoneal approach is also a valid option in cases of severe intraperitoneal adhesion is predicted due to previous open surgery, the patient is highly obese, or suprarenal aortic cross-clamping may be required; however, it may take a long time to reach the proximal neck, or may cause massive bleeding during procedure depending on the rupture site.

When the retroperitoneum is incised after laparotomy, the tissue surrounding the aortic aneurysm is usually relatively sparse. The proximal neck is manually controlled and clamped in an anteroposterior direction usually without taping. Provided the deteriorated coagulation ability due to massive hemorrhage, we usually administer 2,000–3,000 units of heparin, while some others do not. In case of the retroaortic left renal vein, clamping the aortic neck in an anteroposterior direction may cause massive venous bleeding. Therefore, it is advisable to confirm the anatomy of the left renal vein in a preoperative CT scan.

For pararenal aortic RAAA, clamping of the descending aorta via thoracotomy and supraceliac aortic clamping by dividing the right crus of the diaphragm through the lesser omentum are options. However, it is necessary to swiftly shift to infrarenal aortic cross-clamping otherwise all intraperitoneal organs become ischemic.

Procedures following proximal clamping are basically similar to elective AAA repair. However, a major difference from elective repair is that RAAA surgery is life-saving procedure, therefore the procedure should be completed as quickly as possible to minimize the risk of postoperative complications. For example, when RAAA is known to exist with concomitant iliac aneurysms, it is acceptable to leave them untreated and complete the surgery with straight graft replacement as long as those iliac aneurysms are intact and not involved in the rupture.

After reconstruction is completed, the aneurysmal wall

and retroperitoneum are closed to prevent exposure of the prosthetic grafts. After hemostasis is achieved, the abdomen is closed; however, when primary abdominal closure is deemed unfeasible due to massive hematoma and intestinal edema, temporary abdominal closure is performed as per ACS treatment. Abdominal closure should be completed after intestinal edema is improved and the intraabdominal pressure decreases under mechanical ventilation management.

Emergency EVAR for RAAA

The usefulness of emergency EVAR has recently been shown in an increasing number of reports. The SVS guideline issued in January 2018 also has recommended EVAR when RAAA is anatomically feasible (level 1 recommendation [strong]) (Fig. 1).⁵⁾

Our procedures for emergency EVAR for RAAA are described as follows: When preoperative CT confirms that RAAA is anatomically feasible for EVAR, the proximal neck diameter and the left and right iliac artery diameters are measured and the most optimal EVAR devices are prepared while the patient undergoes preoperative management similar to that for OSR.

If possible, preoperative procedures such as tracheal intubation and securing an arterial blood pressure line should be completed in the emergency unit before the patient is transferred to the operation room. After the patient is brought into the operating theater, bilateral femoral arteries are cut down as usual when the patient's condition is relatively stable. If vital signs are unstable, EVAR is percutaneously performed. In such a case, an occlusion balloon should always be used concomitantly so that proximal control on the aortic aneurysm is maintained. That is to say, the main body device of EVAR is fully deployed to the ipsilateral leg, and then removed. Immediately thereafter, the aortic occlusion balloon is inserted through the ipsilateral leg and inflated in the proximal neck. Right after the contralateral iliac leg delivery is completed, the second balloon is inserted through the contralateral leg. Then, the ipsilaterally inserted first balloon is removed and the ipsilateral iliac leg is completed (Fig. 2).

If vital signs are quite unstable, the double balloon technique reported by Berland et al. is very useful because EVAR procedures can be performed while the proximal neck is always blocked with a balloon.⁶⁾ One caveat is that the 14–16F sheath that have been coaxially inserted with the main body device must be removed together with the balloon. Therefore, attention must be given when a barbed device is used, or the proximal neck is highly curved or relatively short.

When cannulation to the contralateral leg is expected to be difficult due to a severe tortuosity, it may be useful to place another access sheath in the brachial artery to

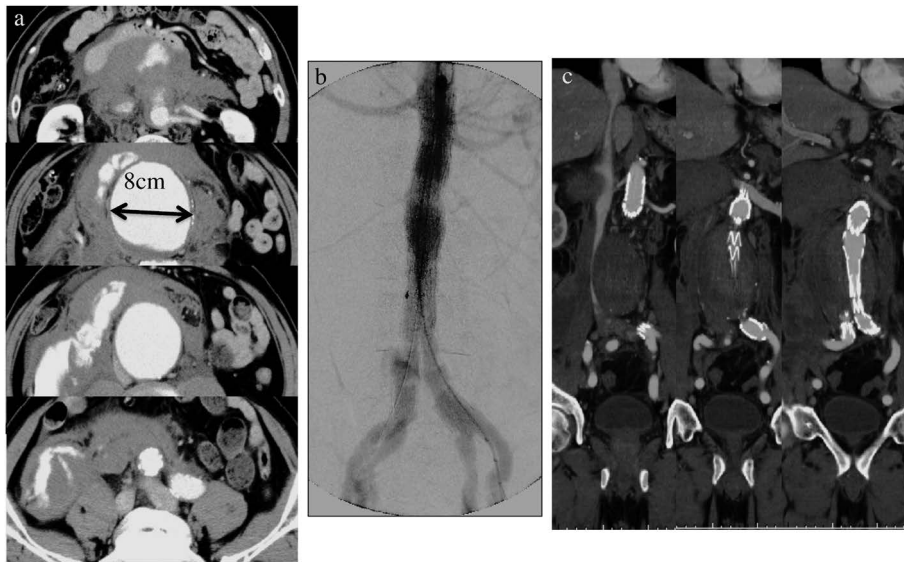


Fig. 1 A case of RAAA treated by EVAR. (a) Fitzgerald grade III RAAA. (b) RAAA was successfully treated by EVAR with Zenith Flex (Cook Medical Incorporated, Bloomington, IN, USA). (c) Postoperative CT scan showed successful aneurysm exclusion without endoleak.

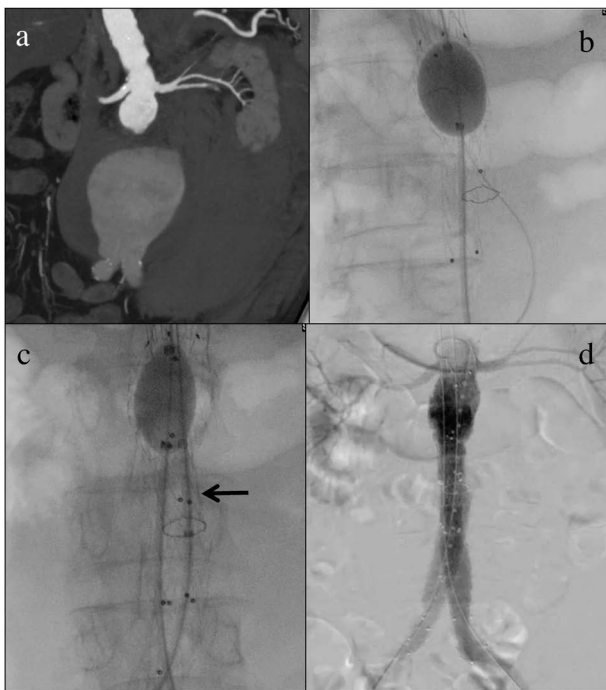


Fig. 2 Our procedure of EVAR for RAAA. (a) Fitzgerald grade III RAAA. (b) As soon as mainbody of the endovascular graft is deployed, an aortic balloon is inflated in the graft body. (c) Contralateral iliac limb is completed during aortic balloon inflation, then second balloon (arrow) is inserted into the contralateral limb. The first aortic balloon is deflated and the second balloon is inflated during delivering the ipsilateral iliac limb. (d) RAAA is successfully excluded without endoleak.

allow for pull-through guide wire technique. Conversion to the aorto-uni-iliac configuration should also be another strong option.

After EVAR procedures are completed without endoleak, the bilateral femoral arteries are exposed to remove sheaths. If ACS is suspected to occur at that point, laparotomy should be performed without hesitation to reduce the intraperitoneal pressure.

RAAA: should the first choice be OSR or EVAR?

It is still controversial whether the first-line treatment for RAAA should be OSR or EVAR. As is obvious, it is difficult to compare these two modalities under identical conditions. The majority of studies published before 2010 have shown the superiority of EVAR, albeit most of them were retrospective studies.^{3,7-11)}

The IMPROVE trial is a representative study wherein these two modalities were prospectively compared in 613 cases collected in the United Kingdom and Canada from 2009 to 2013. It is noteworthy that the patients in this trial were randomized to OSR or endovascular strategy at the time when they were suspected to have RAAA rather than randomizing cases for which both OSR and EVAR were anatomically feasible. This trial found no significant differences in the short-term survival rate between 297 OSR cases and 316 endovascular strategy cases, and concluded that the two modalities were equivalent. However, the length of hospital stay was shorter and the proportion of the patients directly discharged to home was higher in the latter group.¹²⁾ Looking at the data more closely, only 150 of 275 patients with RAAA randomized to the endo-

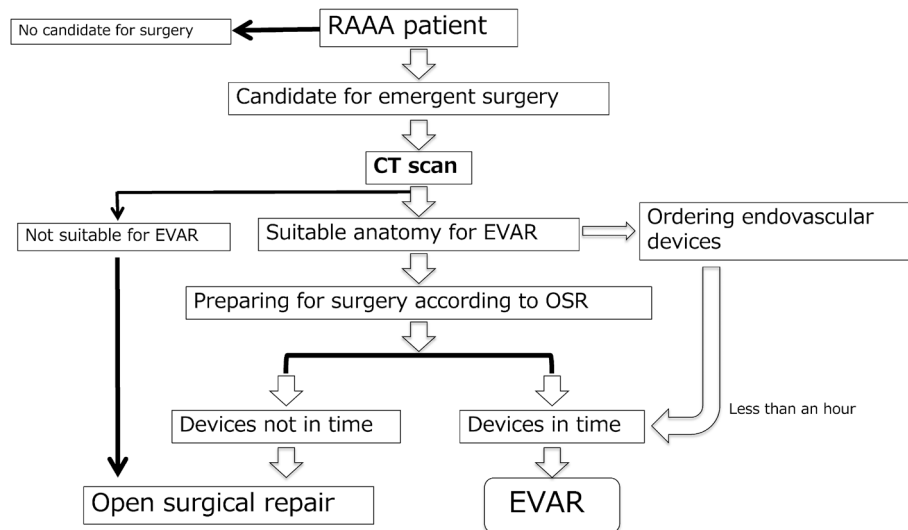


Fig. 3 Algorithm of RAAA treatment in our hospital.

vascular strategy group actually underwent EVAR, while 36 of 261 RAAA patients randomized to the OSR group underwent EVAR. The analysis of the results of this study according to the treatment actually performed indicated that short-term mortality rates for OSR and EVAR were 38.1% and 24.7%, respectively.

Meanwhile, according to a recently published report on a retrospective study involving 3,164 RAAA cases from 2009 to 2015, mortality rates in 1,614 EVAR cases (51%) and 1,550 OSR cases (49%) were 23.8% and 36.3%, respectively, indicating that the mortality was significantly lower for EVAR. Postoperative complications including intestinal ischemia were also fewer in the EVAR group.¹³⁾ Intriguingly, these results are very similar to the treatment results in the IMPROVE trial (OSR 38.1% vs EVAR 24.7%). Given these findings, it appears to be acceptable to place EVAR as a first-line treatment for RAAA as long as an expert EVAR team is available and the case is anatomically suitable for EVAR as strongly recommended by the latest SVS guideline. For readers' information, the treatment algorithm used at our hospital is shown in Fig. 3; our hospital does not have a stock of endovascular grafts, and devices can be delivered to our hospital generally within one hour. However, surgeons should be proficient at both OSR and EVAR procedures because there are many RAAA cases uncontrollable by EVAR.

Management of Postoperative Complications of RAAA

Various complications can occur after surgery for RAAA. Typical examples include postoperative bleeding, heart failure, respiratory failure, intestinal ischemia, and renal failure. Most of these complications can be explained as ACS.

In ACS, perfusion pressure of abdominal organs is disturbed due to an increase of the intraperitoneal pressure, and causes multiple organ failures such as renal failure, intestinal ischemia, and hepatic failure. ACS reportedly occurs in approximately 7% of patients with RAAA undergoing either OSR or EVAR. Mortality of ACS is up to 40% to 70%.^{14,15)} Risk factors for ACS include ≥ 5 L perioperative bleeding, coagulation disorder, persistent hypotension, preoperative loss of consciousness, requirement for an aortic balloon to maintain blood pressure, and aorto-uni-iliac conversion when contralateral cannulation is difficult in EVAR.^{14,15)}

Intraperitoneal pressure ranges from 0 to 5 mmHg in healthy people and from 5 to 7 mmHg in patients with poor general condition. Following RAAA surgery, intraperitoneal pressure is expected to increase to approximately 12 mmHg. If the pressure exceeds 30 mmHg, multiple organ failure may occur.

Intraperitoneal pressure tightly correlates with intrabdominal pressure and is measured via a urethral catheter. If intraperitoneal pressure measured in this manner exceeds 20 mmHg, laparotomy for decompression/temporary closure should be considered because the risk for ACS is elevated. If urine volume decreases and/or airway pressure increases, laparotomy should be performed immediately. Delay to perform decompression laparotomy reportedly increases the mortality rate to 70%.¹⁵⁾

Decompression laparotomy is generally performed as follows: a median incision is made, the intestinal tracts are covered with clean adhesive drapes.^{15,16)} While the use of the vacuum assisted closure system has been reported to be effective,¹⁵⁾ similar benefits can be obtained through the use of an aspiration systems.¹⁶⁾ Abdominal closure is performed after confirming improved circulatory dynamics and alleviated intestinal edema. Abdominal closure

may be performed within a few days after the laparotomy in some cases, or has to wait for more than one week in some other cases. Decisions should be made carefully as to when the patient is ready for abdominal closure as too early abdominal closure can cause ACS recurrence and intraperitoneal infections.

Prediction of Life-Saving from RAAA

In previous sections, we reviewed therapeutic strategy for RAAA and postoperative complications. Although EVAR has (slightly) improved the rate of survival from RAAA as well as ACS treatment has been more procedurally improved, the mortality of RAAA remains high. Therefore, various scoring systems for RAAA severity and likelihood of survival have been reported. Representative examples include Glasgow Aneurysm Score,¹⁷⁾ Hardman Index,¹⁸⁾ Edinburgh Ruptured Aneurysm Score,¹⁹⁾ and Vancouver Score.²⁰⁾ The relatively consistent factors predictive of poor prognosis include advanced age (≥ 76 years), impaired renal function, loss of consciousness, hypotension, and anemia. The predictive accuracies of these scoring systems have been compared, but it is hard to say which one is the most accurate.^{21,22)}

Among recently reported methods for prognosis prediction in RAAA patients, we introduce one very simple and convenient method. Starnes and colleagues at the University of Washington have reported that the mortality rates in patients meeting one, two, three, or all of the following four criteria are 22%, 69%, 80%, and 100%, respectively: (i) ≥ 76 years of age, (ii) ≥ 2.0 mg/dL Cr, (iii) ≥ 70 mmHg systolic blood pressure, and (iv) pH < 7.2 .²³⁾ Similar tendencies were observed in patients treated with both OSR and EVAR. This method for prognostic prediction may be useful since it only requires parameters that can be determined in a short time in an emergency unit.

Conclusion

RAAA is a life-threatening condition that requires immediate intervention for survival; however, treatment outcomes remain unsatisfactory. When a patient with RAAA is brought to a hospital, emergency surgery should be performed as soon as possible, and by then the patient should undergo careful preoperative management. While EVAR may be a very effective option when various conditions are met, OSR remains as the most versatile treatment compatible with any circumstance. Therefore, all vascular surgeons need to be proficient in both modalities.

Disclosure Statement

The Author (Hiroyuki Ito) has no conflict of interest to

disclose.

Additional Note

The contents of this paper were presented at the 28th Educational Seminar of the Japanese Society for Vascular Surgery held in Hiroshima, Japan on October 27, 2018.

References

- 1) Bown MJ, Sutton AJ, Bell PR, et al. A meta-analysis of 50 years of ruptured abdominal aortic aneurysm repair. *Br J Surg* 2002; **89**: 714-30.
- 2) Ohki T, Veith FJ. Endovascular grafts and other image-guided catheter-based adjuncts to improve the treatment of ruptured aortoiliac aneurysms. *Ann Surg* 2000; **232**: 466-79.
- 3) Alsac JM, Desgranges P, Kobeiter H, et al. Emergency endovascular repair for ruptured abdominal aortic aneurysms: feasibility and comparison of early results with conventional open repair. *Eur J Vasc Endovasc Surg* 2005; **30**: 632-9.
- 4) Lachat M, Enzler M. Innovations in the treatment of ruptured AAA may improve future outcome. *Vasa* 2007; **36**: 227-8.
- 5) Chaikof EL, Dalman RL, Eskandari MK, et al. The society for vascular surgery practice guidelines on the care of patients with an abdominal aortic aneurysm. *J Vasc Surg* 2018; **67**: 2-77.e2.
- 6) Berland TL, Veith FJ, Cayne NS, et al. Technique of suprarenal balloon control of the aorta during endovascular repair of ruptured abdominal aortic aneurysms. *J Vasc Surg* 2013; **57**: 272-5.
- 7) Verhoeven EL, Kapma MR, Groen H, et al. Mortality of ruptured abdominal aortic aneurysm treated with open or endovascular repair. *J Vasc Surg* 2008; **48**: 1396-400.
- 8) McPhee J, Eslami MH, Arous EJ, et al. Endovascular treatment of ruptured abdominal aortic aneurysms in the United States (2001–2006): a significant survival benefit over open repair is independently associated with increased institutional volume. *J Vasc Surg* 2009; **49**: 817-26.
- 9) Veith FJ, Lachat M, Mayer D, et al.; RAAA Investigators. Collected world and single center experience with endovascular treatment of ruptured abdominal aortic aneurysms. *Ann Surg* 2009; **250**: 818-24.
- 10) Giles KA, Pomposelli FB, Hamdan AD, et al. Comparison of open and endovascular repair of ruptured abdominal aortic aneurysms from the ACS-NSQIP 2005–07. *J Endovasc Ther* 2009; **16**: 365-72.
- 11) Starnes BW, Quiroga E, Hutter C, et al. Management of ruptured abdominal aortic aneurysm in the endovascular era. *J Vasc Surg* 2010; **51**: 9-17; discussion, 17-8.
- 12) Powell JT, Sweeting MJ, Thompson MM, et al.; IMPROVE trial investigators. Endovascular or open repair strategy for ruptured abdominal aortic aneurysm: 30 day outcomes from IMPROVE randomised trial. *BMJ* 2014; **348**: f7661.
- 13) Gupta AK, Dakour-Aridi H, Locham S, et al. Real-world evidence of superiority of endovascular repair in treating ruptured abdominal aortic aneurysm. *J Vasc Surg* 2018; **68**: 74-81.
- 14) Ersryd S, Djavani-Gidlund K, Wanhainen A, et al. Abdominal

- compartment syndrome after surgery for abdominal aortic aneurysm: a nationwide population based study. *Eur J Vasc Endovasc Surg* 2016; **52**: 158-65.
- 15) Paty PSK, Mehta M. Abdominal compartment syndrome after rEVAR. *Endovascular Today* 2015; **14**: 71-3.
 - 16) Morisaki K, Fukunaga R, Ito H, et al. Delayed closure technique for a ruptured abdominal aortic aneurysm: report of three cases. *Surg Today* 2011; **41**: 1003-6.
 - 17) Samy AK, Murray G, MacBain G. Glasgow aneurysm score. *Cardiovasc Surg* 1994; **2**: 41-4.
 - 18) Hardman DT, Fisher CM, Patel MI, et al. Ruptured abdominal aortic aneurysms: who should be offered surgery? *J Vasc Surg* 1996; **23**: 123-9.
 - 19) Chen JC, Hildebrand HD, Salvian AJ, et al. Predictors of death in nonruptured and ruptured abdominal aortic aneurysms. *J Vasc Surg* 1996; **24**: 614-20; discussion, 621-3.
 - 20) Tambyraja A, Murie J, Chalmers R. Predictors of outcome after abdominal aortic aneurysm rupture: Edinburgh ruptured aneurysm score. *World J Surg* 2007; **31**: 2243-7.
 - 21) Vos CG, de Vries JPPM, Werson DAB, et al. Evaluation of five different aneurysm scoring systems to predict mortality in ruptured abdominal aortic aneurysm patients. *J Vasc Surg* 2016; **64**: 1609-16.
 - 22) Thompson PC, Dalman RL, Harris EJ, et al. Predictive models for mortality after ruptured aortic aneurysm repair do not predict futility and are not useful for clinical decision making. *J Vasc Surg* 2016; **64**: 1617-22.
 - 23) Garland BT, Danaher PJ, Desikan S, et al. Preoperative risk score for the prediction of mortality after repair of ruptured abdominal aortic aneurysms. *J Vasc Surg* 2018; **68**: 991-7.