

Measurement of S1 foramen depth for ultrasound-guided S1 transforaminal epidural injection

Ye Sull Kim^{1,2,3}, SeongOk Park¹, Chanhong Lee¹, Sang-Kyi Lee^{1,2,3}, A Ram Doo^{1,2,3}, and Ji-Seon Son^{1,2,3}

¹Department of Anesthesiology and Pain Medicine, Jeonbuk National University Hospital, Jeonbuk National University Medical School, Jeonju, Korea

²Research Institute of Clinical Medicine of Jeonbuk National University, Jeonju, Korea

³Biomedical Research Institute of Jeonbuk National University Hospital, Jeonju, Korea

ABSTRACT

Background: Ultrasound-guided first sacral transforaminal epidural steroid injection (S1 TFESI) is a useful and easily applicable alternative to fluoroscopy or computed tomography (CT) in lumbosacral radiculopathy. When a needle approach is used, poor visualization of the needle tip reduces the accuracy of the procedure, increasing its difficulty. This study aimed to improve ultrasound-guided S1 TFESI by evaluating radiological S1 posterior foramen data obtained using three-dimensional CT (3D-CT).

Methods: Axial 3D-CT images of the pelvis were retrospectively analyzed. The radiological measurements obtained from the images included 1st posterior sacral foramen depth (S1D, mm), 1st posterior sacral foramen width (S1W, mm), the angle of the 1st posterior sacral foramen (S1A, °), and 1st posterior sacral foramen distance (S1ds, mm). The relationship between the demographic factors and measured values were then analyzed.

Results: A total of 632 patients (287 male and 345 female) were examined. The mean S1D values for males and females were 11.9 ± 1.9 mm and 10.6 ± 1.8 mm, respectively ($P < 0.001$); the mean S1A $28.2 \pm 4.8^\circ$ and $30.1 \pm 4.9^\circ$, respectively ($P < 0.001$); and the mean S1ds, 24.1 ± 2.9 mm and 22.9 ± 2.6 mm, respectively ($P < 0.001$); however, the mean S1W values were not significantly different. Height was the only significant predictor of S1D ($\beta = 0.318$, $P = 0.004$).

Conclusions: Ultrasound-guided S1 TFESI performance and safety may be improved with adjustment of needle insertion depth congruent with the patient's height.

Keywords: Epidural Space; Fluoroscopy; Injections, Epidural; Low Back Pain; Pain Management; Radiculopathy; Sacrum; Steroids; Tomography, X-ray Computed; Ultrasonography, Interventional.

INTRODUCTION

Lumbosacral transforaminal epidural steroid injection

is a valuable therapeutic option for various lumbosacral pathologies, including radiculopathy caused by spinal stenosis or a herniated intervertebral disc. It is a target-

Received July 4, 2022; Revised September 15, 2022; Accepted September 25, 2022

Handling Editor: Yeon-Dong Kim

Correspondence: Ji-Seon Son

Department of Anesthesiology and Pain Medicine, Jeonbuk National University Hospital, Jeonbuk National University Medical School, 20 Geonji-ro, Deokjin-gu, Jeonju 54907, Korea

Tel: +82-63-250-1241, Fax: +82-63-250-1240, E-mail: sjs6803@jbnu.ac.kr



This is an Open Access article distributed under the terms of the Creative Commons Attribution Non-Commercial License (<http://creativecommons.org/licenses/by-nc/4.0>), which permits unrestricted non-commercial use, distribution, and reproduction in any medium, provided the original work is properly cited.

Copyright © The Korean Pain Society

specific approach in which a steroid can be intensively injected into the pathological site and around the dorsal root ganglion [1–4]. Because lumbosacral pathologies such as intervertebral disc herniation develop most frequently at the L4-5 and L5-S1 regions [5], 1st sacral transforaminal epidural steroid injection (S1 TFESI) may be a promising therapeutic option for treating the pain associated with compression of inflammation of the S1 nerve root [6].

S1 TFESI is generally performed under fluoroscopy or computed tomography (CT) guidance, but these techniques have some disadvantages, such as radiation exposure, space limitation, and high costs. Moreover, identification of the S1 posterior foramen is often difficult because it is smaller than the anterior foramen in the anteroposterior fluoroscopic view [7–9]. It may be more challenging in patients with intestinal gas overlap, obesity, severe spinal degeneration, osteoporosis, or anatomic variations [10,11]. Several researchers have suggested practical methods that may help predict the location of the S1 posterior foramen using the alignment of the lumbar facet joint [12,13]. Such methods may narrow down the possible location of the S1 posterior foramen in difficult cases, but they cannot facilitate its visualization.

Ultrasound-guide S1 TFESI is a practical and easily applicable bedside alternative to CT and fluoroscopy that can be performed without exposure to radiation. Lumbar transforaminal injections under fluoroscopy- and ultrasound-guided techniques have been shown to be comparable with reliable accuracy and feasibility in clinical settings [14–17]. Furthermore, the S1 posterior foramen being placed relatively close to the skin, can be easily detected *via* ultrasound [18,19]. However, poor visualization of the needle tip may lead to unwanted drug leakage from the epidural space or a visceral injury during injection [10,20]. Therefore, further research for a better understanding of the surface anatomy and sonographic features of the S1 foramen is necessary to conduct the procedure effectively and safely.

In this retrospective study, the authors aimed to evaluate the anatomical information in terms of the depth, width, length, and angle of the S1 posterior foramen,

using three-dimensional CT (3D-CT) to improve ultrasound-guided S1 TFESI performance. And the demographic factors associated with imaging parameters were also identified.

MATERIALS AND METHODS

This study retrospectively reviewed 3D-CT images of the pelvis of 670 consecutive adult patients who underwent imaging between January 2019 and February 2021. This retrospective study was approved by the Institutional Review Board of Jeonbuk National University Hospital (No. CUH 2021-04-028) and the requirement for informed consent was waived.

The inclusion criteria were being aged 19–99 years and having undergone CT for disease assessment.

The exclusion criteria were the presence of S1 posterior foramen parameters that were difficult to measure owing to lumbosacral bone surgery, sacral deformity caused by primary or metastatic bone cancer, and presence of severe degenerative changes in the lumbosacral spine. The patient selection process is presented as a flow diagram (**Fig. 1**).

1. CT machines

Multi-slice Computed Tomography scanning was performed on a 128-slice dual-source CT scanner (Somatom definition flash, Siemens, Germany). Images of the pelvis were obtained by automatically selecting the patient's optimal kV setting in 10 kV increments by balancing the radiation dose and the image contrast using Siemens' CARE kV function.

2. Radiological measurement of the first sacral foramen

All parameters were measured using axial 3D-CT images of the pelvis. The vertebral level was determined by counting from the 5th lumbar vertebra in the caudal direction, and the largest diameter of the S1 posterior

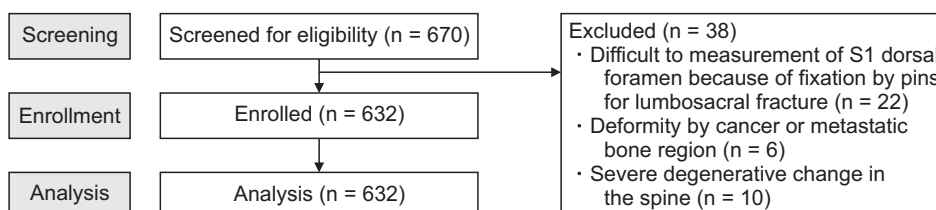


Fig. 1. A flowchart depicting patient enrollment.

foramen was determined after identifying the first and second sacral bones. According to a previous study, lumbarization of the first sacral bone has a prevalence of 4.1%, which can result in incorrect counting of the vertebra resulting in misidentification of the first sacral foramen [21]. Therefore, the position of the 5th lumbar vertebra was confirmed with 3D-CT imaging.

Radiological measurements included the following (Fig. 2): S1 posterior foramen depth (S1D, mm), defined as the length from the posterior surface of the sacrum to the margin of the sacral canal; S1 posterior foramen width (S1W, mm), defined as the largest diameter of the S1 posterior foramen; S1 posterior foramen angle (S1A, °), defined as the angle between the S1 posterior foramen and the midsagittal line of the sacrum; and S1 posterior foramen distance (S1ds, mm), defined as the distance between the midsagittal line of the sacrum and the parallel line passing through the center of the S1 posterior foramen. To minimize measurement errors, two trained anesthesiologists measured each parameter, and the obtained values were averaged.

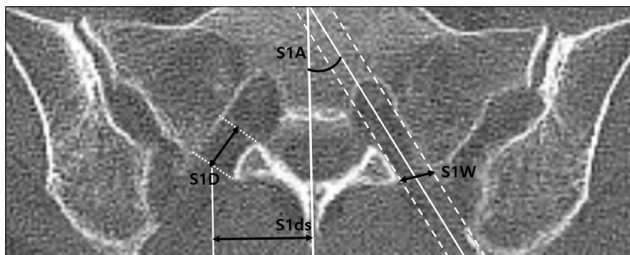


Fig. 2. Measured parameters using axial computed tomography at the level of the 1st posterior sacral foramen. S1D: 1st posterior sacral foramen depth defined as the length from the posterior surface of the sacrum to the margin of the sacral canal, S1W: 1st posterior sacral foramen width defined as the largest diameter of the S1 posterior foramen, S1A: angle of the 1st posterior sacral foramen defined as the angle between the S1 posterior foramen and the midsagittal line of the sacrum, S1ds: 1st posterior sacral foramen distance defined as the distance between the midsagittal line of the sacrum and the parallel line passing through the center of the S1 posterior foramen.

Demographic data, such as age, sex, height, weight, and body mass index (BMI), were evaluated to verify their effects on the measured values. The primary outcome assessed the S1D (mm), while the secondary outcomes included other measurements of the S1 posterior foramen features. Furthermore, we evaluated the correlation between the demographic data and S1 posterior foramen parameters was evaluated.

3. Statistical analysis

An independent sample *t*-test was performed to analyze continuous variables after the normality test. A linear regression model was used to analyze the potential demographic factors in relation to the measured values. Based on the regression analysis, the Bland-Altman method was used to identify the 95% limits of agreement. One-way analysis of variance was used to determine whether S1D was different among stratified groups according to patients' heights. All statistical analyses were performed using IBM SPSS statistics for Windows, version 27 (IBM Co., Armonk, NY). All descriptive statistics are expressed as mean \pm standard deviations. Statistical significance was set at $P < 0.050$.

RESULTS

A total of 632 patients, 287 male and 345 female, were examined. Demographic data are shown in **Table 1**, and measurements of parameters are presented in **Table 2**.

The mean S1D of the males was significantly greater than that of the females (11.5 ± 1.9 mm vs. 10.6 ± 1.8 mm; $P < 0.001$, two-tailed *t*-test). S1A and S1ds values also significantly differed from each other. The mean S1A values of males were smaller than those of females ($28.2 \pm 4.8^\circ$ vs. $30.1 \pm 4.9^\circ$; $P < 0.001$), whereas the mean S1ds values of the males were larger than those of the females (24.1 ± 2.9 mm vs. 22.9 ± 2.6 mm; $P < 0.001$). However, no difference regarding S1W values was observed.

Univariate linear regression analysis revealed a signifi-

Table 1. Demographic data

Variable	Total (n = 632)	Male (n = 287)	Female (n = 345)
Age (yr)	56.8 \pm 18.4	61.9 \pm 18.8	69.7 \pm 16.3
Height (cm)	161.8 \pm 10.0	168.6 \pm 7.8	155.4 \pm 7.3
Weight (kg)	61.8 \pm 12.2	67.9 \pm 11.0	56.1 \pm 10.4
Body mass index (kg/m ²)	23.5 \pm 3.4	23.8 \pm 3.0	23.2 \pm 3.7

Values are presented as means \pm standard deviation.

Table 2. S1 posterior sacral foramen parameter values

Parameters	Total (n = 632)	Male (n = 287)	Female (n = 345)	P value
S1D (mm)	11.0 ± 1.9 (4.9–17.5)	11.5 ± 1.9 (7.1–17.5)	10.6 ± 1.8 (4.9–17.4)	< 0.001*
S1W (mm)	8.5 ± 1.6 (3.7–19.1)	8.3 ± 1.6 (3.7–19.1)	8.6 ± 1.6 (4.7–15.1)	0.066
S1A (°)	29.2 ± 4.9 (12.5–45.8)	28.2 ± 4.8 (12.5–44.7)	30.1 ± 4.9 (18.5–45.8)	< 0.001*
S1ds (mm)	23.5 ± 2.8 (16.2–32.2)	24.1 ± 2.9 (17.8–32.2)	22.9 ± 2.6 (16.2–32.2)	< 0.001*

Values are presented as means ± standard deviation (min–max).

S1D: 1st posterior sacral foramen depth, S1W: 1st posterior sacral foramen width, S1A: angle of the 1st posterior sacral foramen, S1ds: 1st posterior sacral foramen distance.

*P < 0.05 indicated significance with a two-tailed t-test.

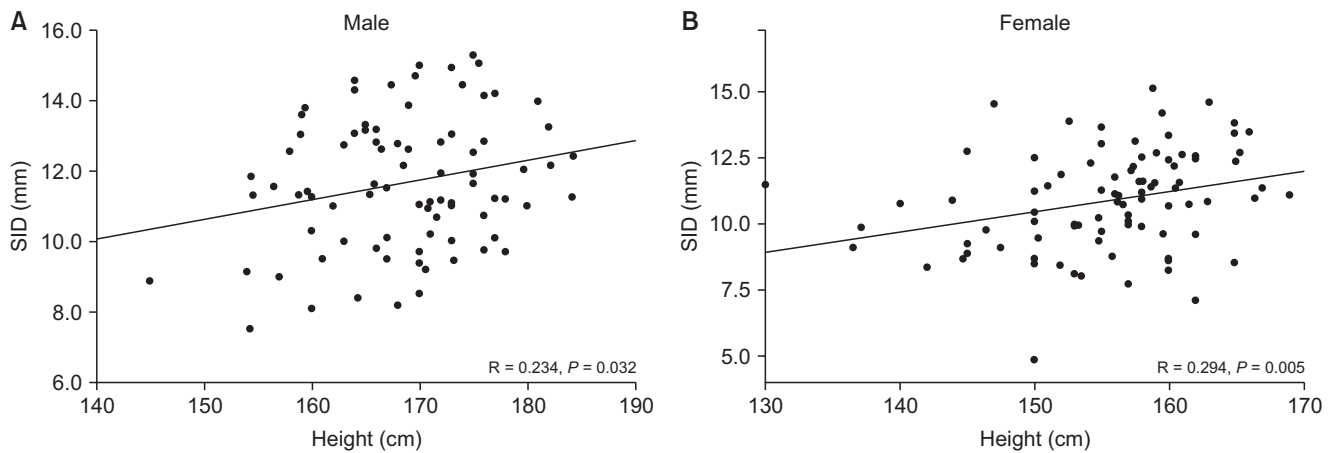


Fig. 3. Relationships between S1D and the patients' height. (A) Male. (B) Female. S1D: 1st posterior sacral foramen depth.

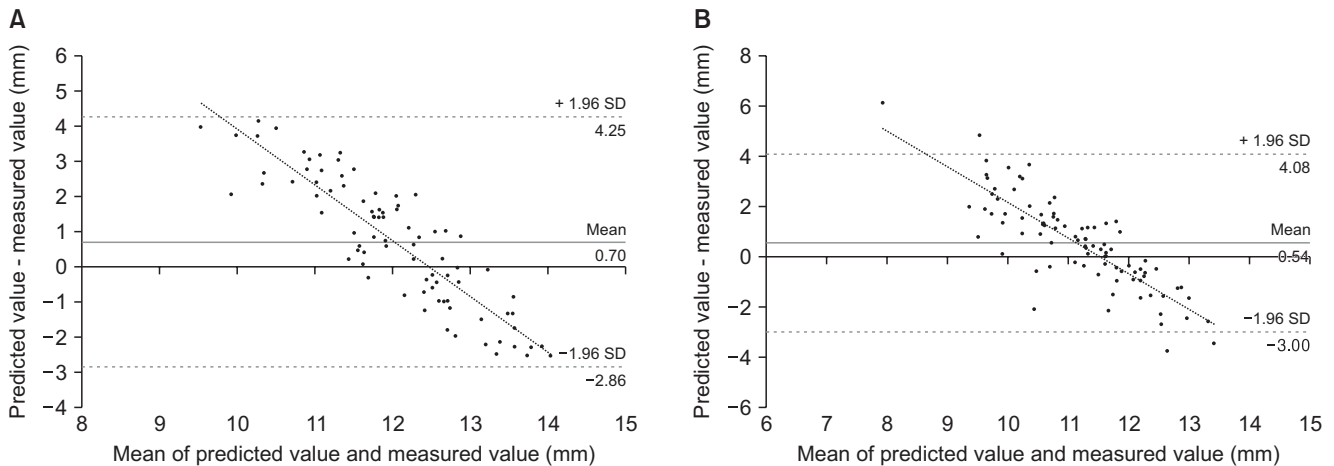


Fig. 4. Bland–Altman plot comparing predicted and measured values of S1D. (A) Male. (B) Female. S1D: 1st posterior sacral foramen depth, SD: standard deviation.

cant correlation between demographic variables and S1D (**Fig. 3**). The Bland–Altman plots are presented in **Fig. 4**. Age, height, and weight were significantly correlated, but no significant correlation with BMI was identified. The significantly associated variables were integrated into a

multivariate linear regression analysis; height was the only significant predictor for S1D ($\beta = 0.318$; 95% confidence interval [CI], 0.020 to 0.101; $P = 0.004$) (**Table 3**).

We further investigated whether height influences S1D. In the males, S1D was significantly reduced in partici-

Table 3. Correlation between the depth of the S1 posterior sacral foramen and demographic variables on linear regression analysis

Variable	Univariate analysis			Multivariate analysis		
	β	95% CI	<i>P</i> value	β	95% CI	<i>P</i> value
Age (yr)	-0.191	-0.029 to -0.012	< 0.001*	-0.058	-0.023 to 0.011	0.489
Height (mm)	0.333	0.037 to 0.091	< 0.001*	0.318	0.020 to 0.101	0.004*
Weight (kg)	0.222	0.012 to 0.058	0.003*	-0.018	-0.034 to 0.028	0.855
BMI (kg/m ²)	0.007	-0.081 to 0.089	0.927			

BMI: body mass index, CI: confidence interval.

**P* < 0.05 indicated significance.

Table 4. Depth of the S1 posterior sacral foramen stratified by height

	Height	Number of patients	S1D (mm)
Male (n = 287)	< 155 cm	16	9.8 ± 1.8 ^a
	155 ≤, < 165 cm	65	11.6 ± 2.0
	165 ≤, < 175 cm	134	11.7 ± 1.8
	≥ 175 cm	72	12.2 ± 1.6
Female (n = 345)	< 155 cm	130	10.1 ± 1.9 ^b
	155 ≤, < 165 cm	192	11.3 ± 1.8
	≥ 165 cm	23	12.0 ± 1.0

Values are presented as means ± standard deviation.

S1D: 1st posterior sacral foramen depth.

^aSignificantly different than that of male participants ≥ 175 cm tall (*P* = 0.006).

^bSignificantly different than that of female participants ≥ 165 cm tall (*P* = 0.019).

pants with a height < 155 cm compared with those with a height ≥ 175 cm (9.8 ± 1.8 vs. 12.2 ± 1.6 mm, *P* = 0.006). In the females, S1D was significantly reduced in participants with a height < 155 cm compared with those with a height ≥ 165 cm tall (10.1 ± 1.9 vs. 12.0 ± 1.0 mm, *P* = 0.019) (Table 4).

Other parameters and demographic variables were analyzed by linear regression analysis. S1Ds showed a significant correlation with height (β = 0.278; 95% CI, 0.035 to 0.112; *P* < 0.001), but no significant correlation with age, weight, or BMI. S1W and S1A showed no significant relationship.

DISCUSSION

Ultrasound imaging has been suggested as an important alternative to fluoroscopy for various spinal interventions in that it is easy to apply without space limitations and free from radiation exposure. Moreover, it can visualize almost all spinal structures, including the musculature,

bony surfaces, facet joints, and intervertebral foramen. Ultrasound imaging also helps in visualization of S1 posterior foramen in those with a relatively clear sonoanatomy [22], and its feasibility compared with that of conventional fluoroscopy has been validated [6,14–17]. However, the main drawback of ultrasound-guided S1 TFESI is that the needle tip may not be well visualized inside the sacral foramen [20,23]. Besides, excessive needle advancement into the sacral foramen may cause drug leakage through the anterior sacral foramen or a pelvic organ injury, resulting in a failed procedure [10,20].

For minimizing these kinds of unexpected side effects, many studies have suggested anatomical information via direct measurement using cadavers [7,24] or imaging studies [11,25]. Watanabe et al. [25] analyzed the relationship between the S1 posterior foramen and S1 nerve root by 3D-CT to prevent nerve root damage during a sacral surgical approach. They reported that the average distance from the posterior surface of the sacrum to the S1 nerve root was 13.9 mm. Although direct comparison of those results with the current study is limited due to the methodological discrepancy, the measured parameter approximately corresponds to the S1D of the current study. This study revealed similar results, in which S1D is 11.0 mm. However, the wide range of S1D, as presented in the current study (min–max; 4.9–17.5), should be taken into consideration to prevent accidental nerve and organ injury in clinical practice. Another study investigated various parameters such as the largest diameter of the S1 foramen as well as the angle of the S1 foramen [11]. The comparison of the measured parameters between the present study and previous studies are shown in Table 5.

The measured values of the present study suggest some interesting facts for pain physicians, which are as follows. (1) The patient's height is an independent predictor of S1D, indicating the need to adjust needle insertion depth congruently to patient's height during ultrasound-guided S1 TFESI. In both male and female with a height < 155 cm, the needle tip should not be inserted more

Table 5. Comparison of morphological parameters

Reference	S1D (mm)	S1W (mm)	S1A (°)	S1ds (mm)
The current study	Male (n = 287) 11.5 ± 1.9	Male (n = 287) 8.3 ± 1.6	Male (n = 287) 28.2 ± 4.8	Male (n = 287) 24.1 ± 2.9
	Female (n = 345) 10.6 ± 1.8	Female (n = 345) 8.6 ± 1.6	Female (n = 345) 30.1 ± 4.9	Female (n = 345) 22.9 ± 2.6
Arman et al. [7]	N/A	Adult (n = 100) 7.97 ± 1.89	N/A	N/A
Hwang et al. [11]	N/A	Male (n = 202) 7.1 ± 0.7	Male (n = 202) 26.4 ± 3.4	N/A
		Female (n = 214) 7.1 ± 0.7	Female (n = 214) 26.2 ± 3.3	
Bagheri and Govsa [24]	N/A	Adult (n = 87) 7.97 ± 1.89	N/A	N/A

Values are presented as mean ± standard deviation.

S1D: length of the 1st posterior sacral foramina, S1W: the width of the 1st posterior sacral foramina, S1A: the angle of the 1st posterior sacral foramina, S1ds: the distance of the 1st posterior sacral foramina, N/A: not applicable.

than approximately 10 mm from the posterior margin of the S1 posterior foramen to prevent potential risk to the patients. Moreover, the Bland–Altman plot showed a negative correlation, suggesting that S1D can potentially be overestimated in shorter patients but underestimated in taller ones. (2) S1ds show significant correlation with height. This suggests that S1ds will also increase with the patients' heights, as the vertebral cross-section area has a positive correlation with the height as well as study by Oura et al. [26]. In this respect, the depth of the posterior foramen is also expected to increase with the patient's height due to bone growth because it is an estimate of the length of a bone structure (3). However, S1A has shown no significant relationship which would explain that the growth ratio of width and depth in vertebral body growth is almost constant and therefore has barely any effect on the angle.

Fluoroscopy remains the gold standard for spinal interventions, and ultrasound imaging has some technical limitations, including difficulty in identifying the correct epidural spread of drugs and negative intravascular uptake. Park et al. [10] suggested a novel method that combines both ultrasound imaging and fluoroscopy for S1 TFESI. They used ultrasound to guide the initial needle placement and subsequently used fluoroscopy to confirm correct needle placement and drug spread. However, further investigations are urgent for improving the accuracy, safety, and applicability of ultrasound-guided procedures. Thus, to the best of the authors' knowledge, this is the first study to measure depth of the S1 posterior foramen using 3D-CT. The data of this study will provide useful information for minimizing the disadvantage of

ultrasound-guided S1 TFESI by facilitating the prediction of an appropriate needle insertion depth. However, this study has a few limitations. First, the measured parameters may not reflect the actual values as they depend on the angulation and rotation axis of the CT scan, which may not always focus adequately on the sacral foramen. The 3D-CT scan can be used to prevent such errors only to some extent. Second, the possibility of selection bias cannot be excluded because the sample consisted of mostly elderly patients, meaning it did not adequately reflect all age groups. In addition, all patients included in this study were Koreans, and racial differences are possible. Third, the data obtained in this study are from analysis of radiographically measured data. Therefore, additional follow-up studies applying the data are needed for clinical practice. To obtain more clinically valuable data, multi-center studies of patients of different age groups and races are needed.

In conclusion, this study evaluated various anatomical parameters of the S1 posterior foramen, whereby the results indicated the importance of needle insertion depth adjustment corresponding to a patient's height for a successful ultrasound-guided S1 TFESI.

DATA AVAILABILITY

The datasets supporting the findings of this study are available from the corresponding author upon reasonable request.

CONFLICT OF INTEREST

No potential conflict of interest relevant to this article was reported.

FUNDING

This paper was supported by Funds from Biomedical Research Institute, Jeonbuk National University Hospital, Jeonju, Republic of Korea.

AUTHOR CONTRIBUTIONS

Ye Sull Kim: Writing/manuscript preparation; SeongOk Park: Investigation; Chanhong Lee: Investigation; A Ram Doo: Writing/manuscript preparation; Sang-Kyi Lee: Supervision; Ji-Seon Son: Study conception.

ORCID

Ye Sull Kim, <https://orcid.org/0000-0001-8771-488X>
 SeongOk Park, <https://orcid.org/0000-0001-7611-4061>
 Chanhong Lee, <https://orcid.org/0000-0003-0595-9141>
 A Ram Doo, <https://orcid.org/0000-0003-1310-790X>
 Sang-Kyi Lee, <https://orcid.org/0000-0002-7965-7501>
 Ji-Seon Son, <https://orcid.org/0000-0002-6672-4576>

REFERENCES

1. Manchikanti L, Buenaventura RM, Manchikanti KN, Ruan X, Gupta S, Smith HS, et al. Effectiveness of therapeutic lumbar transforaminal epidural steroid injections in managing lumbar spinal pain. *Pain Physician* 2012; 15: E199-245.
2. Roberts ST, Willick SE, Rho ME, Rittenberg JD. Efficacy of lumbosacral transforaminal epidural steroid injections: a systematic review. *PM R* 2009; 1: 657-68.
3. Chun EH, Park HS. Effect of high-volume injectate in lumbar transforaminal epidural steroid injections: a randomized, active control trial. *Pain Physician* 2015; 18: 519-25.
4. Bhatia A, Flamer D, Shah PS, Cohen SP. Transforaminal epidural steroid injections for treating lumbosacral radicular pain from herniated intervertebral discs: a systematic review and meta-analysis. *Anesth Analg* 2016; 122: 857-70.
5. Jordan J, Konstantinou K, O'Dowd J. Herniated lumbar disc. *BMJ Clin Evid* 2009; 2009: 1118.
6. Sato M, Mikawa Y, Matuda A. Ultrasound and electrical nerve stimulation-guided S1 nerve root block. *J Anesth* 2013; 27: 775-7.
7. Arman C, Naderi S, Kiray A, Aksu FT, Yilmaz HS, Tetik S, et al. The human sacrum and safe approaches for screw placement. *J Clin Neurosci* 2009; 16: 1046-9.
8. Cheng JS, Song JK. Anatomy of the sacrum. *Neurosurg Focus* 2003; 15: E3.
9. Povo A, Arantes M, Matzel KE, Barbosa J, Ferreira MA, Pais D, et al. Surface anatomical landmarks for the location of posterior sacral foramina in sacral nerve stimulation. *Tech Coloproctol* 2016; 20: 859-64.
10. Park YJ, Lee SH, Ryu KH, Kim YK, Shim J, Lee HW, et al. Novel method for S1 transforaminal epidural steroid injection. *World Neurosurg* 2020; 133: e443-7.
11. Hwang BY, Park JH, Ji HT, Kim GE, Kim SK, Lee YK, et al. Retrospective lumbosacral CT analysis and prospective observational study of the ipsilateral tunnel view technique for fluoroscopy-guided selective S1 transforaminal epidural injection. *Pain Pract* 2022; 22: 83-90.
12. Cha YD, Choi JK, Yang CW, Lim HK, Heo GA, Kim BG. Relationship between first dorsal sacral foramen and lumbar facet joint connecting line in South Korea populations: retrospective study. *Medicine (Baltimore)* 2017; 96: e7544.
13. Roussouly P, Gollogly S, Berthonnaud E, Dimnet J. Classification of the normal variation in the sagittal alignment of the human lumbar spine and pelvis in the standing position. *Spine (Phila Pa 1976)* 2005; 30: 346-53.
14. Park D. Can ultrasound-guided S1 transforaminal epidural injection using the in-plane approach and color Doppler imaging be a safer alternative to lumbar inter-laminar epidural injection? *Am J Phys Med Rehabil* 2018; 97: e66-7.
15. Gofeld M, Bristow SJ, Chiu SC, McQueen CK, Bollag L. Ultrasound-guided lumbar transforaminal injections: feasibility and validation study. *Spine (Phila Pa 1976)* 2012; 37: 808-12.
16. Evansa I, Logina I, Vanags I, Borgeat A. Ultrasound versus fluoroscopic-guided epidural steroid injections in patients with degenerative spinal diseases: a randomised study. *Eur J Anaesthesiol* 2015; 32: 262-8.

17. Hashemi M, Dadkhah P, Taheri M, Haji Seyed Abootorabi SM, Naderi-Nabi B. Ultrasound-guided lumbar transforaminal epidural injections; a single center fluoroscopic validation study. *Bull Emerg Trauma* 2019; 7: 251-5.
18. McGrath MC, Stringer MD. Bony landmarks in the sacral region: the posterior superior iliac spine and the second dorsal sacral foramina: a potential guide for sonography. *Surg Radiol Anat* 2011; 33: 279-86.
19. Kim SH, Yoon KB, Yoon DM, Choi SA, Kim EM. An analysis of location of needle entry point and palpated PSIS in S1 nerve root block. *Korean J Pain* 2010; 23: 242-6.
20. Lee BJ, Han J, Park D. A video of ultrasound-guided S1 transforaminal epidural injection using color Doppler: technical reports. *Pain Pract* 2020; 20: 396-8.
21. Price R, Okamoto M, Le Huec JC, Hasegawa K. Normative spino-pelvic parameters in patients with the lumbarization of S1 compared to a normal asymptomatic population. *Eur Spine J* 2016; 25: 3694-8.
22. Plaikner M, Gruber H, Schwabl C, Brenner E, Bale R, Skalla E, et al. A simple approach for ultrasound-guided paravertebral injections in the sacral spine: a pilot computer tomography controlled cadaver study. *Med Ultrason* 2019; 21: 125-30.
23. Park D. Ultrasound-guided S1 transforaminal epidural injection using the in-plane approach and color Doppler imaging. *Am J Phys Med Rehabil* 2018; 97: e14-6.
24. Bagheri H, Govsa F. Anatomical considerations of safe drilling corridor upper sacral segment screw insertion. *J Orthop* 2019; 16: 543-51.
25. Watanabe N, Takigawa T, Uotani K, Oda Y, Misawa H, Tanaka M, et al. Three-dimensional analysis of the ideal entry point for sacral alar iliac screws. *Asian Spine J* 2022. doi: 10.31616/asj.2021.0268.
26. Oura P, Nurkkala M, Auvinen J, Niinimäki J, Karppinen J, Junno JA. The association of body size, shape and composition with vertebral size in midlife - the Northern Finland Birth Cohort 1966 study. *Sci Rep* 2019; 9: 3944.