

# Subacute onset leukodystrophy and visual-spatial disorders revealing phenylketonuria combined with homocysteinemia in adulthood

## A case report

Chunchen Wang, MS<sup>a,\*</sup>, Jieying Li, MS<sup>b</sup>

### Abstract

**Rationale:** Phenylketonuria (PKU) is a metabolic disorder, which manifests a progressive irreversible neurological impairment during infancy and childhood. Hyperhomocysteinemia also showed that it might be involved in pathophysiology of many neuropsychiatric disorders. The late-onset clinical manifestations of these 2 diseases have not been reported elsewhere. We speculated that the late-onset PKU is caused by 2 kinds of metabolic dysfunction synergistically, especially a short period of irregular diet directly caused clinical symptoms.

**Patient concerns:** A 21-year old Asian male patient demonstrated subacute leukodystrophy and visual-spatial disorders of late onset in adulthood.

**Diagnoses:** Phenylketonuria combined with homocysteinemia, who presented with heterozygous mutations in gene encoding PAH p.G247R (c.739G>C) and p.Y204C (c.611A>G), along with homozygous mutation of gene encoding MTHFR c.677C>T.

**Interventions:** The patient was treated with cobalamine (500 µg/day), vitamin B6 (30 mg/day), folate (5 mg/day) and encouraged to follow a protein-restricted diet.

**Outcomes:** Visual disorientation and cognitive function showed improvement. Head MR showed similar resolution with the original lesion. Serum homocysteine and folate analysis were normal with decreased phenylalanine level.

**Lessons:** This case suggests that neurological involvement of progressive nervous system dysfunction could be caused by more than one kind of inherited metabolic disturbances, and each one can induce or deteriorate the manifestations of another metabolic disorders.

**Abbreviations:** BH<sub>4</sub> = tetrahydrobiopterin, CBS = cystathionine β-synthase, EEG = electroencephalogram, EMG = electromyogram, HHcy = hyperhomocysteinemia, MS = methionine synthase, MTHFR = methylenetetrahydrofolate reductase, PAH = phenylalanine hydroxylase, Phe = phenylalanine, PKU = phenylketonuria, WAIS= Wechsle adult intelligence scales.

**Keywords:** leukoencephalopathy, phenylalanine hydroxylase, phenylketonuria

## 1. Introduction

Phenylketonuria (referred to as PKU) is one of the few curable inborn errors of metabolism in humans. Up to 2011 in China, a

total number of 35.79 million newborns had been tested and of which, 3082 cases have been confirmed for PKU, which indicates the prevalence of PKU in 1/11,614 cases.<sup>[1]</sup> As a metabolic disorder, PKU is characterized by phenylalanine (Phe) accumulation due to phenylalanine hydroxylase (PAH) deficiency. PAH hydroxylates Phe to tyrosine, for which tetrahydrobiopterin (BH<sub>4</sub>) is required as a co-factor. During infancy and childhood, PKU manifest as a progressive irreversible neurological impairment involving growth failure, intellectual impairment, epilepsy and tremor. In 2008, the first case of late adulthood PKU case was reported with musty odor, mental retardation, and spastic paraplegia.<sup>[2]</sup> During adulthood, untreated PKU may become apparent. According to the earlier published case reports, few patients developed late spastic paraparesis or tetraparesis, tremor, epilepsy, and ataxia as presenting features with or without the decline in cognitive abilities.<sup>[1,3]</sup> In addition, hyperhomocysteinemia (HHcy) is an independent risk factor for atherosclerotic vascular disease, especially reported in Chinese Han population.<sup>[4]</sup> Besides, it is demonstrated that HHcy may be involved in pathophysiology of a large number of neuropsychiatric disorders.<sup>[5]</sup> Polymorphisms of genes encoding homocysteine metabolism-related enzymes, such as methylenetetrahydrofolate reductase (MTHFR), cystathionine β-synthase (CBS) and methionine synthase (MS), are the important

Editor: N/A.

This study was supported by the Hospital Authority Training Programme Fund (grant number PZ2016005).

The authors have no conflicts of interest to disclose.

<sup>a</sup> Department of Neurology & Acupuncture and Moxibustion Centre, Beijing Hospital of Traditional Chinese Medicine Affiliated to Capital Medical University, Beijing, <sup>b</sup> Department of Neurology, The Second People's Hospital of Guiyang, Guiyang, Guizhou, China.

\* Correspondence: Chunchen Wang, Department of Neurology & Acupuncture and Moxibustion Centre, Beijing Hospital of Traditional Chinese Medicine Affiliated to Capital Medical University, No. 23 Art Museum Backstreet, Dongcheng District, Beijing 100010, China (e-mail: cc-wang1101@hotmail.com).

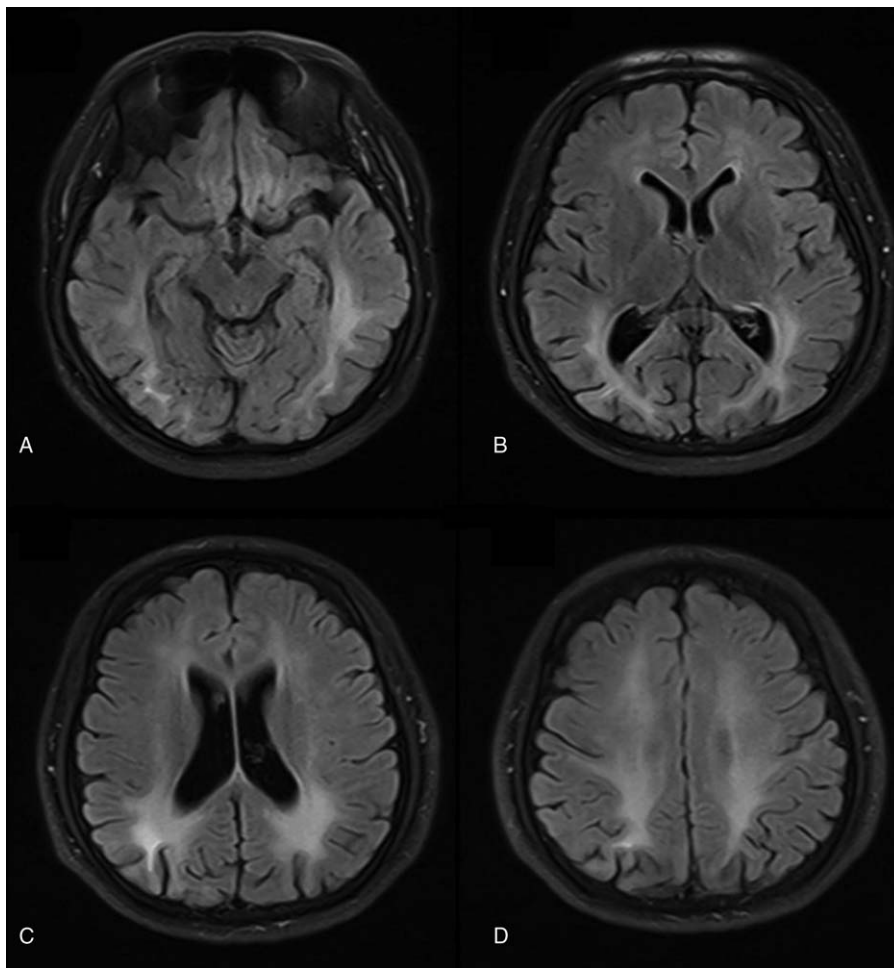
Copyright © 2018 the Author(s). Published by Wolters Kluwer Health, Inc. This is an open access article distributed under the Creative Commons Attribution-NoDerivatives License 4.0, which allows for redistribution, commercial and non-commercial, as long as it is passed along unchanged and in whole, with credit to the author.

Medicine (2018) 97:8(e9801)

Received: 4 December 2017 / Received in final form: 9 January 2018 /

Accepted: 16 January 2018

<http://dx.doi.org/10.1097/MD.0000000000009801>



**Figure 1.** Cranial MR images finding. Axial FLAIR T2-weighted sequences obtained in April 2014 showing hyperintensities involving periventricular and subcortical white matter (A–D) which suggest leukodystrophy.

determinants of Hcy concentrations.<sup>[6]</sup> In this report, an adult patient diagnosed with PKU in combination with homocysteinemia is reported, who presented heterozygous mutations in gene encoding PAH p.G247R (c.739G>C) and p.Y204C (c.611A>G), as well as homozygous mutation in gene encoding MTHFR c.677C>T. It is suspected that these 2 kinds of metabolic dysfunctions might have lead to a subacute onset leukodystrophy and visual-spatial disorders synergistically.

## 2. Case report

This study was not approved by the ethics committee because this is a clinical case report which does not involve clinical studies, drug trials, etc., and the patient was treated according to the related disease guidelines. The patient provided the written informed consent.

A 21-year-old Chinese Han male, was referred with 5-month history of visual-spatial disorders and 2-year history of personality changes. His childhood history was normal without family history. Because of addiction to Internet games, he got a period of irregular diet and disrupted daily life at age 19, that is, in his first year of college study. And then, he experienced delay in processing speed, declining mobility, autism, generalized apathy, and sometimes compulsion. In the beginning of 2014, visual

orientation disorders began to appear, which reflected clearly in his utilization of chopsticks for dishes being inaccurate, and filling of wrong serial number in machine reading card. Physical examination showed dark brown hair and the ophthalmic examination indicated that bilateral vision dropped to 0.3 with normal fundus. Motor and sensory examination as well as cranial nerves examination were normal. But the cranial MRI revealed brain leucodystrophy with symmetric abnormalities in bilateral deep cerebral white matter (Fig. 1), caused us to suspect X-linked adrenoleukodystrophy and heredity leukodystrophy. The blood test results revealed that homocysteine level was 128  $\mu\text{mol/L}$  (0–20  $\mu\text{mol/L}$ ). Moreover, Serum AQP-4 antibody, GM1 antibody, very-long-chain fatty acid and ABCD1 gene test in plasma were reported negative, caused us to clear heredity leukodystrophy.

In May 2014, the patient was admitted for persistent visual-spatial disorders. Due to visual oriental disorders, the problem of keeping in lines while writing still existed. Physical examinations displayed bilateral normal muscle strength with brisk tendon reflexes in 4 limbs. In addition, palm-jaw reflex and finger-nose test were positive, whereas other neurology examinations were negative. Besides, ophthalmic evaluation was normal and bilateral visual acuity increased to 0.8. No positive signs were observed in electromyogram (EMG) tests, while

electroencephalogram (EEG) presented mild abnormality. Visually evoked responses had reduced latencies of P100 with poor differentiation. There was a prolonged latency of left I wave in evoked brain stem auditory. Wechsle adult intelligence scales (WAIS) showed that VIQ was 86, PIQ was 84, and FIQ was 84, which were under normal levels. Furthermore, the following blood tests were negative: complete blood count, creatinine, vitamin B12, electrolyte, antinuclear, serum immunoelectrophoresis, thyroid function test, erythrocyte sedimentation rate, blood coagulation function test, lactate, pyruvate, arylsulfatase A, hexosaminidase A and B,  $\beta$ -D-galactosidase,  $\beta$ -D-mannosidase, galactosylceramidase, phytanic acid, serum sexual hormone and urinary-17 hydroxy steroid. The intracranial pressure was 160 mm H<sub>2</sub>O and CSF immunoglobulin A was 0.64 g/L with normal protein, no cells and no oligoclonal bands were observed. Repeated serum homocysteine level was 75.5  $\mu$ mol/L (normal 0–20  $\mu$ mol/L) and serum folate level was 1.31 ng/mL (normal > 3.8 ng/mL). Besides, urine routine showed positive for ketone body. The genetic results revealed homozygous mutation in gene encoding methylene tetrahydrofolate reductase (MTHFR) c.677C> T in the patient and MTHFR was a key enzyme in homocysteine metabolism. Plasma and urine amino acids chromatography presented increased phenylalanine levels in serum (694  $\mu$ mol/L, normal < 120  $\mu$ mol/L) and Phe/Tyr was found increased. Meanwhile, phenylalanine metabolism disorders were reflected in the urine result (Fig. 2). The patient was detected with heterozygous mutations for p.G247R (c.739G>C) and p.Y204C (c.611A>G), respectively, located in exon6 and exon7 of PAH gene, which probably caused an inactive protein function. Based on the above findings, the patient was diagnosed with PKU overlapping homocysteine and folate deficiency.

## 2.1. Treatment

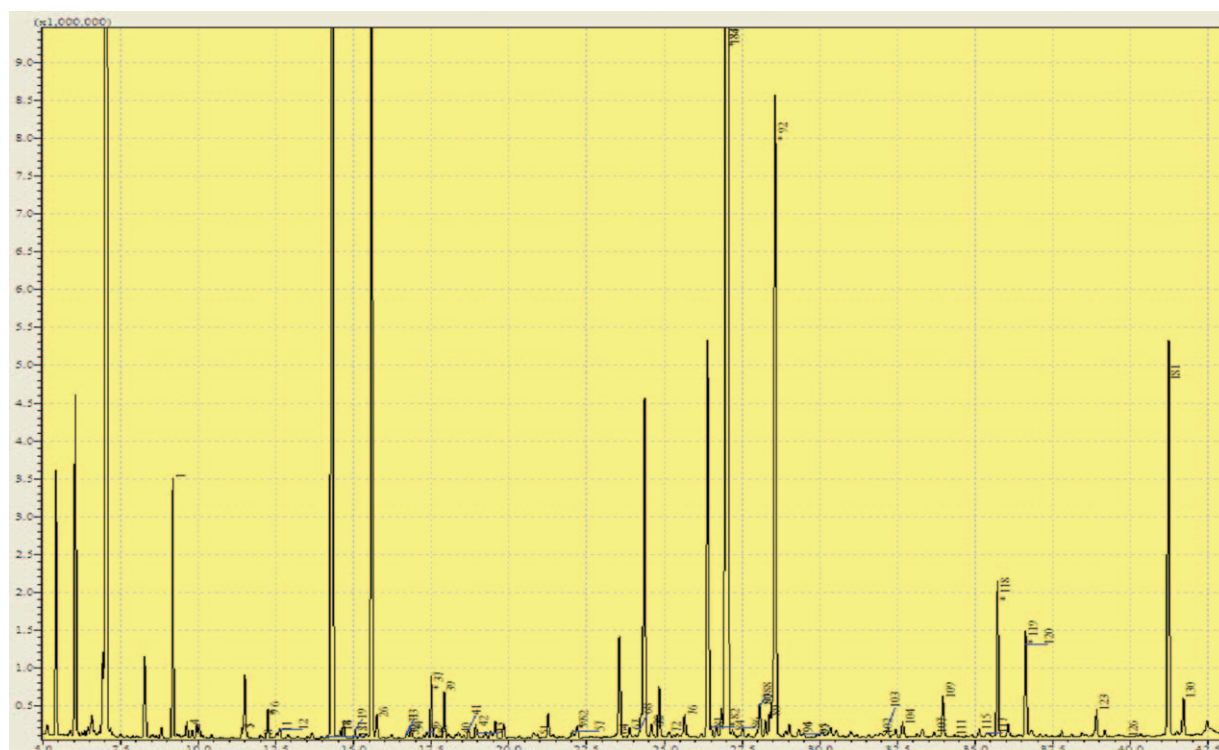
The patient was treated with intramuscular cobalamine injections (500  $\mu$ g/day), oral vitamin B6 (30 mg/day), oral folate (5 mg/day) and encouraged to follow a protein-restricted diet. After 3 weeks, moderate improvement was shown in his visual-spatial disorders and personality. He was discharged on oral cobalamine 500  $\mu$ g/day, vitamin B6 30 mg/day, folate 5 mg/day, and a protein-restricted diet.

## 2.2. Outcome and follow-up

Three months after the routine treatment, a subsequent head MR showed the same resolution with the original lesion. Serum homocysteine and folate analysis was repeated and the results were normal with decreased phenylalanine level (545.17  $\mu$ mol/L). Also, treatment was continued, and the patient went back to college and continued normal study process, and also placed under regular medical follow-up.

## 3. Discussion

In the present report, a patient with encephalopathy and visual orientation disorders were described, whose symptoms, initial laboratory findings, and imaging results suggested subacute onset leukodystrophy in adulthood PKU with overlapping of MTHFR mutation induced disturbances. Without unusual urine odour, he neither had anemia, or abnormal hair nor skin color. The head MRI indicated symmetric abnormalities in bilateral deep cerebral white matter of occipital, parietal and frontal lobe. On account of atypical presentation, it seemed to be



**Figure 2.** Urine organic acid spectrum showed phenylacetic, phenyllactic, phenylpyruvic, 4-hydroxyphenyllactic, 4-hydroxyphenylpyruvic, 3-methylglutaconic, 3-hydroxyglutaric acid concentration increased which suggesting that phenylalanine metabolism disorders, liver damage, and nutrition disorders.

inappropriate to make a diagnosis of heredity leukodystrophy. Besides, further examinations revealed hyperphenylalaninemia with heterozygous mutations for p.G247R (c.739G>C) and p.Y204C (c.611A>G) located in exon6 and exon7 of PAH, which can be considered as classic phenylketonuria. Overlapping TT genotype of MTHFR c.677C> T was diagnosed in combination with homocysteine and folate deficiency.

Characterized by hyperphenylalaninemia resulting from hepatic phenylalanine hydroxylase deficiency, PKU is an inherited autosomal recessive disorder, which converts phenylalanine into tyrosine. More than 800 mutations have been characterized so far and reported in phenylalanine hydroxylase gene locus-specific database.<sup>[7]</sup>

As PKU is curable, early detection and treatment allows patient to have a normal life. In October 1981, newborn screening was started in Shanghai. Now, almost all provinces of China have a newborn screening program of testing dried blood samples, which is conducted by the government. By 2012, Eastern China and economically developed regions have high screening rates reaching up to more than 90%. However, our patient born in 1993 did not undergo the screening program. PKU patients' with severe neurological impairment manifest the following characteristics, such as a direct consequence of neuronal cell loss, synapse reduction, and white matter abnormalities.<sup>[8–10]</sup> Studies performed in patients and animal model suggest that the underlying mechanism of pathophysiology has been identified to be related to metabolites accumulation and exert neurotoxic effects on Phe level particularly, which results in DNA damage in patient blood and animal brain subjected to an animal model of PKU<sup>[11,12]</sup> and cell apoptosis in cultured neurons.<sup>[13]</sup> In addition, neuroimaging studies demonstrated high-signal intensity in the periventricular white matter in majority of PKU patients.<sup>[14]</sup> Brain magnetic resonance imaging indicates clearly that white matter changes might have a certain relationship with these neuropsychological difficulties. Early onset PKU is associated with a range of neuropsychological impairments, including dopamine and white matter pathology.<sup>[14]</sup> Late onset PKU patients could be improved by diet treatment.<sup>[15]</sup>

The 5, 10-methylene tetrahydrofolate reductase (MTHFR) locus is mapped on chromosome 1 at the end of the short arm (1p36.6).<sup>[16]</sup> This enzyme plays a significant role in folate metabolism and this is an integral process for cell metabolism in DNA, RNA, and protein methylation. The mutation in MTHFR gene located at exon 4 results in the conversion of valine to alanine at codon 222, which is a common polymorphism causing the reduced activity of this enzyme, and results in hyperhomocysteinemia and low folate level.<sup>[17]</sup> As the epidemiology of the polymorphism varying depends on the geography and ethnicity, MTHFR C677T polymorphism has been associated with various diseases, such as vascular, cancers, neurology, diabetes, and psoriasis.<sup>[18]</sup> The majority of studies concerning MTHFR gene mutation were reported to be related to an elevated level of homocysteine, which is an independent factor for coronary heart disease and stroke. Spinal cord demyelination combined with MTHFR C677T mutation have been reported,<sup>[19]</sup> which shows induced disturbances in methylation process and result in a lower methylation rate of myelin basic protein. Besides, this kind of protein plays an important role in tightening compactness of myelin sheath through the association with acidic lipid on the cytosolic side of the membrane bilayer.<sup>[20]</sup>

#### 4. Conclusion

In our case, the patient had mild mental disorder, poor executive function, and visual orientation disorders. MRI abnormalities consist of T2-weighted and FLAIR images hyperintensities located in the occipital, parietal, frontal and extending regions. He was detected with heterozygous mutations in p.G247R (c.739G>C) and p.Y204C (c.611A>G) of PAH, and homozygous mutation in c.677C> T of MTHFR, which led to neuropsychological abnormalities synergistically. Successful treatment with low-phenylalanine diet, vitamin B and folate, leads to symptoms improvement along with decline in Hcy level. As far as we know, it is the first report of a patient with metabolic disorders revealing hyperphenylalaninemia in combination with homocysteinemia of PAH and MHTFR mutations that occurred in adulthood. It is speculated that a short period of irregular diet and life style appears to likely indicate complicated neurological symptoms. This case suggests that neurological involvement of progressive nervous system dysfunction can be caused by more than one kind of inherited metabolic disorder, and each can induce or deteriorate the manifestations of another metabolic disorder.

#### Acknowledgments

We acknowledge the expert advice by consultant Pediatrician Professor Xiuping Yang.

#### References

- [1] Shi XT, Cai J, Wang YY, et al. Newborn screening for inborn errors of metabolism in mainland china: 30 years of experience. *JIMD Rep* 2012;6:79–83.
- [2] Jousserand G, Antoine JC, Camdessanche JP. Musty odour, mental retardation, and spastic paraplegia revealing phenylketonuria in adulthood. *J Neurol* 2010;257:302–4.
- [3] Gao S, Li H, Xiao H, et al. Association of MTHFR 677T variant allele with risk of intracerebral haemorrhage: a meta-analysis. *J Neurol Sci* 2012;323:40–5.
- [4] Rong D, Liu J, Jia X, et al. Hyperhomocysteinemia is an independent risk factor for peripheral arterial disease in a Chinese Han population. *Atherosclerosis* 2017;263:205–10.
- [5] Brustolin S, Giugliani R, Felix TM. Genetics of homocysteine metabolism and associated disorders. *Braz J Med Biol Res* 2010;43:1–7.
- [6] Malinowska A, Chmurzynska A. Polymorphism of genes encoding homocysteine metabolism-related enzymes and risk for cardiovascular disease. *Nutr Res* 2009;29:685–95.
- [7] Wettstein S, Underhaug J, Perez B, et al. Linking genotypes database with locus-specific database and genotype–phenotype correlation in phenylketonuria. *Eur J Hum Genet* 2015;23:302–9.
- [8] Bauman ML, Kemper TL. Morphologic and histoanatomic observations of the brain in untreated human phenylketonuria. *Acta Neuropathol* 1982;58:55–63.
- [9] Horster F, Schwab MA, Sauer SW, et al. Phenylalanine reduces synaptic density in mixed cortical cultures from mice. *Pediatr Res* 2006;59:544–8.
- [10] Gazit V, Ben-Abraham R, Pick CG, et al. beta-Phenylpyruvate induces long-term neurobehavioral damage and brain necrosis in neonatal mice. *Behav Brain Res* 2003;143:1–5.
- [11] Sitta A, Manfredini V, Biasi L, et al. Evidence that DNA damage is associated to phenylalanine blood levels in leukocytes from phenylketonuric patients. *Mutat Res* 2009;679:13–6.
- [12] Simon KR, Dos Santos RM, Scaini G, et al. DNA damage induced by phenylalanine and its analogue p-chlorophenylalanine in blood and brain of rats subjected to a model of hyperphenylalaninemia. *Biochem Cell Biol* 2013;91:319–24.
- [13] Zhang H, Gu XF. A study of gene expression profiles of cultured embryonic rat neurons induced by phenylalanine. *Metab Brain Dis* 2005;20:61–72.
- [14] Anderson PJ, Leuzzi V. White matter pathology in phenylketonuria. *Mol Genet Metab* 2010;99(suppl 1):S3–9.

- [15] Lee PJ, Amos A, Robertson L, et al. Adults with late diagnosed PKU and severe challenging behaviour: a randomised placebo-controlled trial of a phenylalanine-restricted diet. *J Neurol Neurosurg Psychiatry* 2009;80:631–5.
- [16] Goyette P, Sumner JS, Milos R, et al. Human methylenetetrahydrofolate reductase: isolation of cDNA mapping and mutation identification. *Nat Genet* 1994;7:551.
- [17] Kang SS, Zhou J, Wong PW, et al. Intermediate homocysteinemia: a thermolabile variant of methylenetetrahydrofolate reductase. *Am J Hum Genet* 1988;43:414–21.
- [18] Liew SC, Gupta ED. Methylenetetrahydrofolate reductase (MTHFR) C677T polymorphism: epidemiology, metabolism and the associated diseases. *Eur J Med Genet* 2015;58:1–0.
- [19] Hao M, Zhang Y, Hou S, et al. Spinal cord demyelination combined with hyperhomocysteinemia: a case report. *Neuropsychiatr Dis Treat* 2014;10:2057–9.
- [20] Frattini D, Fusco C, Ucchino V, et al. Early onset methylmalonic aciduria and homocystinuria cblC type with demyelinating neuropathy. *Pediatr Neurol* 2010;43:135–8.