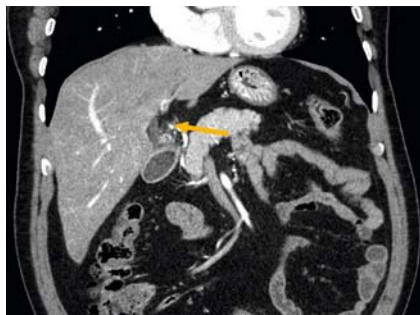
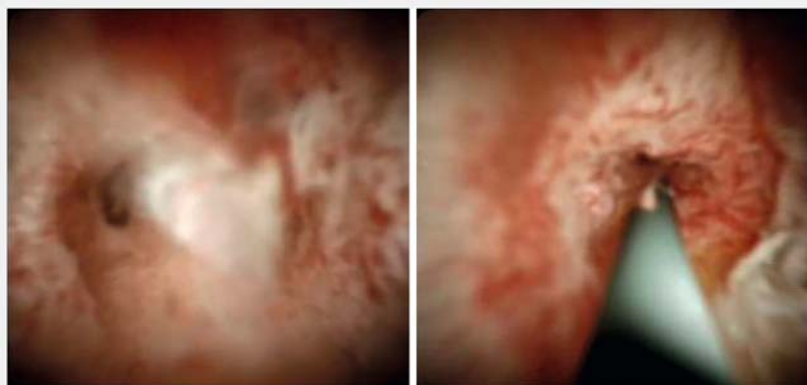

Endoscopic management of cystic duct stumpitis

OPEN
ACCESS

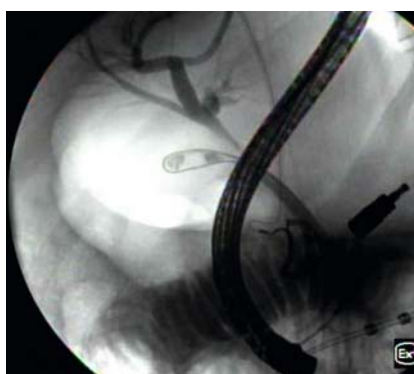► **Fig. 1** Contrast-enhanced computed tomography of the abdomen demonstrating a dilated cystic stump with abnormal enhancement at the junction with the common bile duct, and high density material at the distal margin of the cystic duct suggestive of possible stone material.



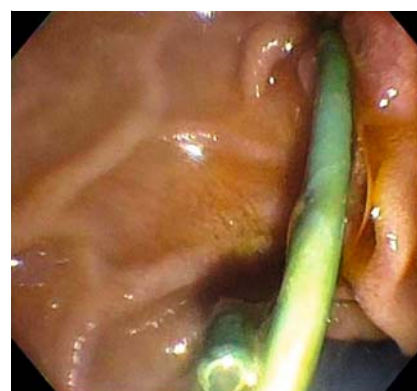
► **Fig. 2** The cholangioscope was advanced to the cystic duct insertion, which was markedly edematous and inflamed with partially denuded epithelium. The cholangioscope was unable to be advanced past the distal aspect of the cystic duct insertion owing to the significant degree of inflammation.

A 62-year-old man who underwent an uncomplicated laparoscopic cholecystectomy 1 year prior for acute gangrenous cholecystitis presented with abdominal pain. Computed tomography demonstrated a dilated cystic duct remnant with stones (► **Fig. 1**), confirmed on magnetic resonance cholangiopancreatography. The patient declined surgical intervention. Given the recent evidence [1], the patient was referred for an endoscopic retrograde cholangiopancreatography (ERCP).

Cholangioscopy (SpyGlass Direct Visualization System; Boston Scientific, Natick, Massachusetts, USA) during ERCP revealed a markedly inflamed and stenosed cystic duct insertion (► **Fig. 2**), thought to be reactive from stone disease, precluding advancement of the cholangioscope into the cystic duct remnant. The remainder of the bile duct epithelium was normal. An occlusion cholangiogram demonstrated an obstructing stone within the cystic duct remnant (► **Fig. 3**). Owing to the severe inflammation, attempted stone extraction was deferred. A 5Fr × 10-cm plastic pigtail stent was placed into the cystic duct remnant for transpapillary decompression to fa-



► **Fig. 3** An occlusion cholangiogram demonstrated a round filling defect consistent with a proximal obstructing stone within the cystic duct stump.

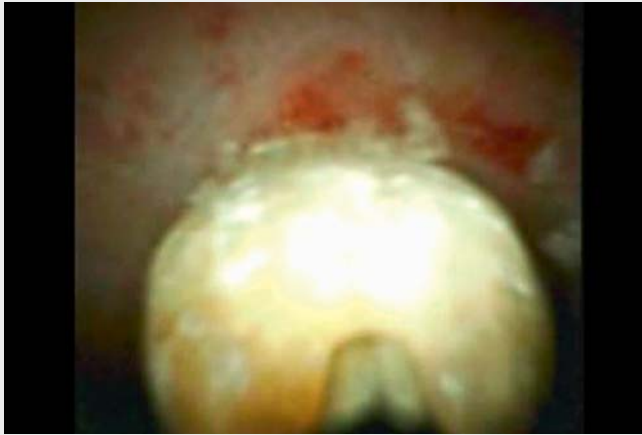

► **Fig. 4** A 5Fr × 10-cm plastic pigtail stent was placed into the cystic duct remnant for transpapillary decompression and to facilitate healing of the inflammation.

facilitate inflammation healing (► **Fig. 4**). The patient was discharged home on a course of oral antibiotics. On repeat ERCP 3 months later, the stent was removed and cholangiogram demonstrated a persistent stone in the cystic duct remnant (► **Video 1**). Cholangioscopy was performed and the inflammation had resolved (► **Fig. 5**). The cholangioscope was advanced into the remnant, and a small cholesterol stone was visualized. Electrohydraulic lithotripsy (EHL)

was successfully employed and the stone was extracted. A final occlusion cholangiogram confirmed clearance of the cystic duct remnant. On 4-week follow-up, the patient confirmed complete resolution of symptoms.

Surgical resection of the cystic duct remnant has been the traditional approach for treatment of cystic duct remnant syndromes [2]. We report a case of cystic duct stump syndrome (stumpitis) mana-



Video 1 Follow-up endoscopic retrograde cholangiopancreatography 3 months after initial procedure.

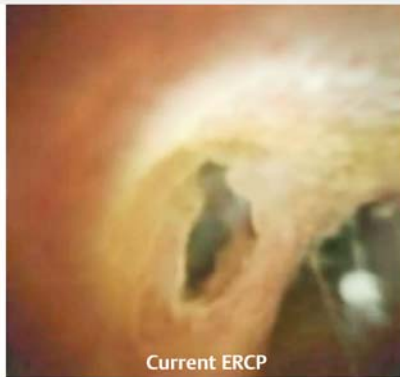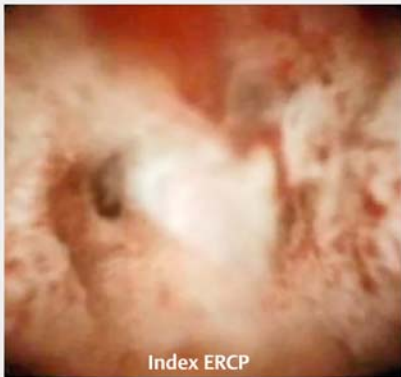


Fig. 5 Cholangioscopic exam 3 months from the index endoscopic retrograde cholangiopancreatography demonstrating complete resolution of cystic duct remnant inflammation and considerably improved narrowing of the cystic duct remnant insertion following transpapillary decompression with cystic duct stent.

ged solely with endoscopy. This case demonstrates that transpapillary stenting and calculi extraction can be effective for this syndrome, highlighting the expanding role endoscopy plays in the management of postsurgical conditions.

Endoscopy_UCTN_Code_CCL_1AZ_2AD

Competing interests

AJT: Consultant for Pentax Medical, Lucid Diagnostics, and Exact Sciences. PCB: Consultant for Boston Scientific, Apollo Endosurgery, Fujifilm, Olympus America; MP has no financial or personal COI.

The authors

Monica Passi  **Petros C. Benias, Arvind J. Trindade**

Division of Gastroenterology, Long Island Jewish Medical Center, Zucker School of Medicine at Hofstra/Northwell, Northwell Health System, New Hyde Park, New York, USA

Corresponding author

Arvind J. Trindade, MD

Long Island Jewish Medical Center, Division of Gastroenterology, Zucker School of Medicine at Hofstra/Northwell, Northwell Health System, 270-05 76th Avenue, New

Hyde Park, NY 11040, USA
Fax: +1-718-470-5509
arvind.trindade@gmail.com

References

- [1] Hajifathalian K, Issa D, Carr-Locke D et al. Cystic duct remnant syndrome: endoscopic approach to management. *VideoGIE* 2019; 4: 563–564
- [2] Kar A, Gulati S, Mohammed S et al. Surgical management of cystic duct stump stone or gallbladder remnant stone. *Indian J Surg* 2018; 80: 284–287

Bibliography

Endoscopy 2022; 54: E960–E961

DOI 10.1055/a-1882-5491

ISSN 0013-726X

published online 21.7.2022

© 2022. The Author(s).

This is an open access article published by Thieme under the terms of the Creative Commons Attribution-NonDerivative-NonCommercial License, permitting copying and reproduction so long as the original work is given appropriate credit. Contents may not be used for commercial purposes, or adapted, remixed, transformed or built upon. (<https://creativecommons.org/licenses/by-nc-nd/4.0/>)

Georg Thieme Verlag KG, Rüdigerstraße 14, 70469 Stuttgart, Germany



ENDOSCOPY E-VIDEOS

<https://eref.thieme.de/e-videos>



Endoscopy E-Videos is an open access online section, reporting on interesting cases and new

techniques in gastroenterological endoscopy. All papers include a high quality video and all contributions are freely accessible online. Processing charges apply (currently EUR 375), discounts and waivers acc. to HINARI are available.

This section has its own submission website at

<https://mc.manuscriptcentral.com/e-videos>