

Interdisciplinary Full Mouth Rehabilitation of a Patient with Amelogenesis Imperfecta: A Case Report with 8 Years Follow-up

S Sreedevi¹, R Sanjeev², Rena Ephraim³, Mathai Joseph⁴

Contributors:

¹Professor, Department of Prosthodontics, Mahe Institute of Dental Sciences, Mahe, Puducherry, India; ²Professor, Department of Periodontics, Indira Gandhi Institute of Dental Science, Kothamangalam, Kochi, Kerala, India; ³Professor, Department of Pedodontics with Preventive Dentistry, Mahe Institute of Dental Sciences, Mahe, Puducherry, India; ⁴Professor and Head, Department of Prosthodontics, Mahe Institute of Dental Sciences, Mahe, Puducherry, India.

Correspondence:

Dr. Sreedevi S. Department of Prosthodontics, Mahe Institute of Dental Sciences, Mahe, Puducherry, India. Phone: +91-8089087801. Email: s.sreedevi.dr@gmail.com

How to cite the article:

Sreedevi S, Sanjeev R, Ephraim R, Joseph M. Interdisciplinary full mouth rehabilitation of a patient with amelogenesis imperfecta: A case report with 8 years follow-up. J Int Oral Health 2014;6(6):90-3.

Abstract:

This case report deals with the interdisciplinary approach of a 28-year-old lady with Amelogenesis imperfecta of the hypoplastic kind. The patient came with a chief illness of worn out teeth, unsatisfactory esthetics and severe sensitivity of teeth. Her family history revealed a related situation in her father's brother and her sister. On clinical assessment, the crowns of all teeth were worn out. The plan of the treatment was to protect as much tooth structure, restore the vertical dimension, and improve esthetics and masticatory function. The treatment procedures involved prosthodontic, endodontic, and periodontic interventions. After recording the vertical height, endodontic treatment and crown lengthening were performed with respect to the lower anteriors. The lost vertical height was regained in stages by insertion of full coverage crowns for all the teeth. The patient's esthetic and functional needs were met with systematic and sequential interdisciplinary treatment approach.

Key Words: Amelogenesis imperfecta, esthetics, full mouth rehabilitation, interdisciplinary approach

Introduction

Amelogenesis imperfecta (AI) is a heterogeneous inherited disorder that disturbs the enamel formation and exists independent of any related systemic disorder also. It affects both the primary and permanent dentitions. Prevalence varies between approximately 1:700-1:14,000.¹ Different modes of inheritance includes autosomal dominant, recessive or X linked.² The anatomic and histologic features of the various types include either reduced enamel thickness (hypoplasia) or decreased mineralization (hypomineralization including hypomaturation and hypocalcification subtypes).³ According

to literature, clinical findings of AI include enamel deficiencies, pulpal calcification, failed tooth eruption, impaction of permanent teeth, root malformations, congenitally missing teeth, progressive root and crown resorption, tooth sensitivity and anterior and posterior open articulations.⁴ Due to reduced enamel thickness the teeth are often undersized, with the lack of contact between adjacent teeth, poor oral hygiene and mouth breathing with associated gingivitis and gingival hyperplasia.

Management of each case of AI requires an interdisciplinary approach to obtain the best outcome. Treating a patient with AI is important from a functional standpoint and also from a psychological point of view and hence the intent of treatment should be to both restore esthetics and improve masticatory function. This case report describes the sequenced treatment for a young patient with hypoplastic AI.

Case Report

A 28-year-old woman previously diagnosed with AI of the hypoplastic Type 1, reported to the Department of Prosthodontics with a chief complaint of sensitivity, worn out teeth and unsatisfactory esthetics (Figure 1). A complete dental and social history was obtained. The medical history and general physical condition revealed normal ranges. The family history revealed that the patient's parents were cousins and were not affected by AI. But her sister and father's brother were affected by AI.

The patient had not undergone any restorative treatment for esthetics before the consultation but had a Class 2 amalgam restoration on 37. Clinical and radiographical examination revealed worn out upper and lower anterior and posterior teeth (Figures 2, 3a and b). The pulp chambers of lower anterior teeth were exposed due to severe attrition, and the lower anteriors were completely overlapped by the upper anteriors. So there was a loss of vertical dimension with anterior deep bite. Patient did not give any history of parafunctional habits.

Objectives of treatment

To preserve maximum tooth structure, increase the lost vertical dimension to an ideal, comfortable position, which is the "physiologic neuromuscular position," and to restore masticatory function and improve esthetics.⁵ The treatment was planned in three stages.

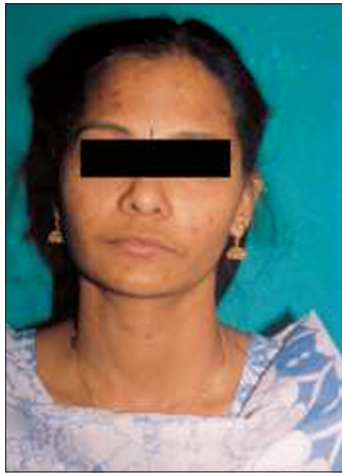

Figure 1: Pre-treatment photograph.

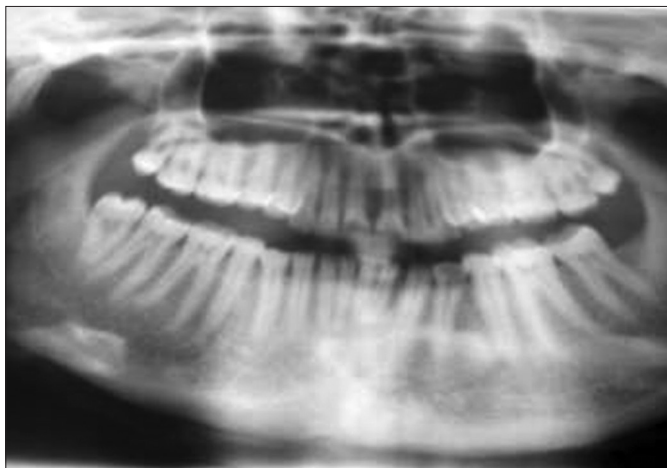


Figure 2: Orthopantomogram of the patient.

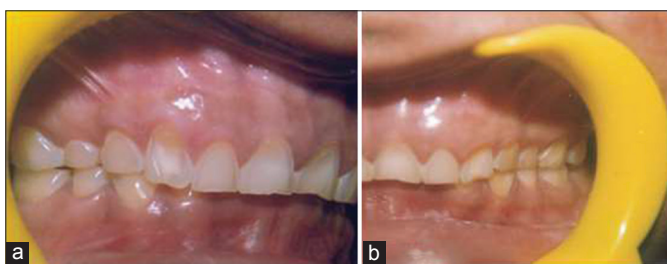

Figure 3: (a and b) Pre-operative photo showing worn out teeth and severe deep bite.

During the first stage of treatment

Two sets of impression casts were made. One set was used as diagnostic casts, and the other set was used for the manufacture of occlusal splints. A face bow record was made to record the craniomaxillary and maxillomandibular relationship. It was determined to raise the vertical height by 4 mm to reinstate the lost vertical height after noting the available interocclusal distance. It was then mounted on a semi adjustable articulator.

Occlusal splints of 2 mm each were fabricated using cold cure acrylic resin for the upper and the lower arch, and the

individual was asked to wear it for 3 months to get her used to the increase in the vertical dimension without doing any preparation on the teeth initially. Dental prophylaxis was performed, and oral hygiene instructions were given to the patient. The patient was reviewed after a week, and then a month, during this time; to see that she could comfortably accommodate the raised vertical dimension without any temporomandibular joint pain.

During the second stage of treatment

On review, the patient did not have any uneasiness, so it was decided to move to the next stage of treatment where the lower posterior teeth and then the upper posteriors were prepared and given provisional crowns in heat cure acrylic resin to maintain a similar vertical height (4 mm) (Figure 4a and b). After 3 months, the lower and then the upper posteriors were restored with definitive porcelain fused to metal crowns on the premolars of all the four quadrants and full metal crowns on all the molars; cemented with glass ionomer cement. Definitive impressions were made with polyvinyl siloxane impression material and bite registration was made with aluwax bite registration material.

During the third stage of treatment

Root canal treatment was performed with respect to all lower anteriors, i.e., 11, 12, 13, 21, 22, 23 as their pulps were exposed. Patient was referred to Department of Periodontics for crown lengthening with respect to all lower anteriors to increase their clinical crown length to permit placement of the definitive crowns.

Temporary crowns were given the same day following tooth preparation of lower anteriors (Figure 4c). Then the upper anteriors were prepared and temporized (Figure 4d). The temporary crowns were subsequently replaced by porcelain fused to metal in the anterior teeth. Porcelain fused to metal restorations were made using customized incisal guide table and cemented with glass ionomer cement (Figure 5a and b).

Oral hygiene instructions were given, and the patient was recalled past a week and then a month for follow-up and regular follow-up has been done for the last 8 years. At the end of treatment, all our goals were achieved. We could not only protect the remaining tooth structure but could also reinstate masticatory function and get better esthetics (Figure 6).

Discussion

Inherited defects of the enamel are the most recurrent congenital anomalies of dental hard tissues.¹ Based on the clinical presentation and strong family history, a diagnosis of AI (hypo calcified, autosomal recessive type) was made. An accurate diagnosis is important clinically for numerous

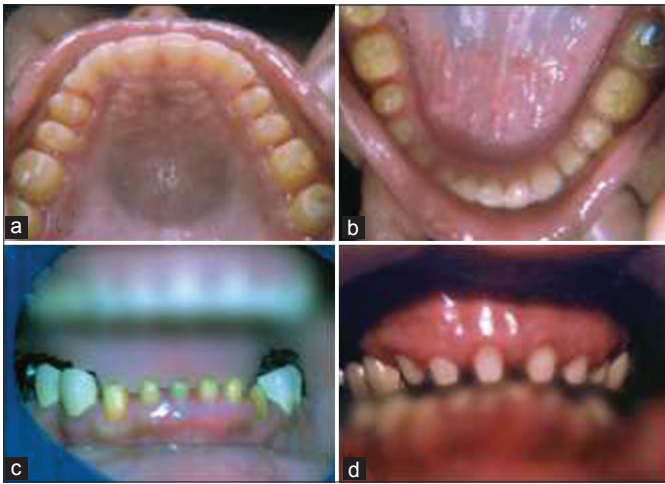

Figure 4: Posteriors after tooth preparation (a) maxillary (b) mandibular and anteriors after tooth preparation (c) mandibular (d) maxillary.

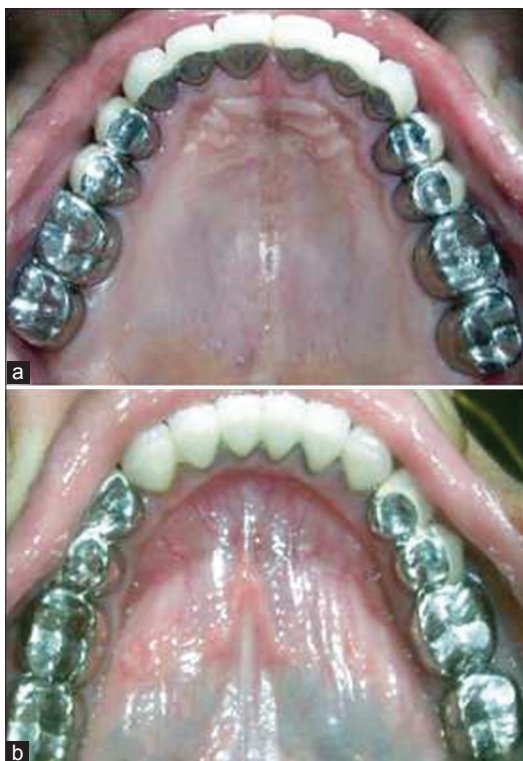

Figure 5: Definitive crowns after cementation in (a) maxillary and (b) mandibular arch.

reasons. First, one has to rule out the occurrence of systemic diseases that may accompany enamel hypoplasia. Secondly, precise diagnosis enables genetic counseling for affected families. Finally, an accurate diagnosis helps in recognition of the condition so preventive measures can be provided early. Treating a patient with AI is important for functional and psychosocial reasons. Some patients need only oral hygiene instructions while others need extensive dental treatment. The clinician must watchfully balance the esthetic requests of the patient, strength of the restoration, protection of the remaining teeth and long term prognosis of the treatment.⁶ Adhesive

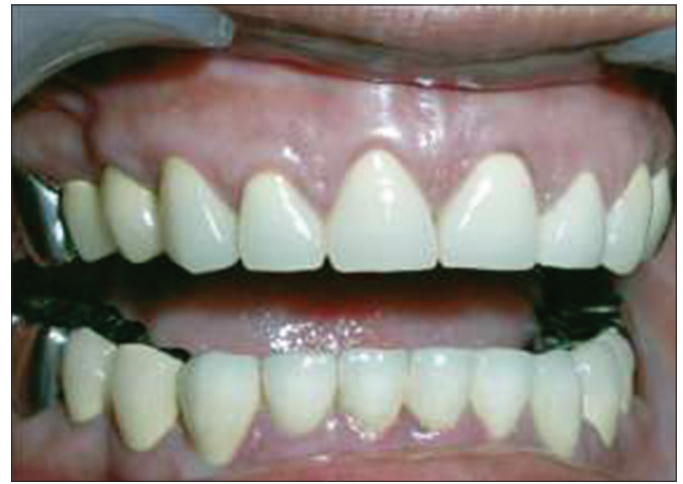

Figure 6: Definitive crowns in place.

restorative techniques, over dentures, porcelain-fused-to-metal crowns, fixed partial dentures, full porcelain crowns, and inlay/onlay restorations are the different modalities used for the prosthodontic treatment of AI patients.^{7,8}

In the present case, treatment was carried out in 3 stages. In the first stage, temporary occlusal Splints were used to acclimatize and to find if the patient could tolerate the increase in the vertical height of 4 mm.^{5,9,10} Increase in the vertical height of 4 mm was done in another case report by Makarita where satisfying esthetics and functions were achieved.¹¹

In this study, the splints were specified for a period of 3 months. The minimum recommended time is 3 months (for a minimum of 22 h/day).

Only after confirming that the patient could stand the increase in the vertical dimension, the second stage of treatment was carried out involving tooth preparation and placement of full mouth temporary crowns. During this stage, we could not only establish the above but also carry out the required interdisciplinary treatment procedures like endodontic treatment and periodontal crown lengthening before the definitive crowns were placed. Although the entire procedure took about 6 months, we were able to meet both functional and esthetic satisfaction of the patient. The patient was advised to sustain good oral hygiene by regular flossing and brushing. After a follow-up of 8 years, the patient did not present any signs and symptoms of abnormal function and was satisfied with both function and esthetics (Figure 7).

Conclusion

The esthetic and functional rehabilitation of a patient with AI has been described. The restoration of esthetics and function in patients with AI may be achieved by accurate diagnosis, meticulous treatment planning with a dedicated team approach involving different disciplines in dentistry.

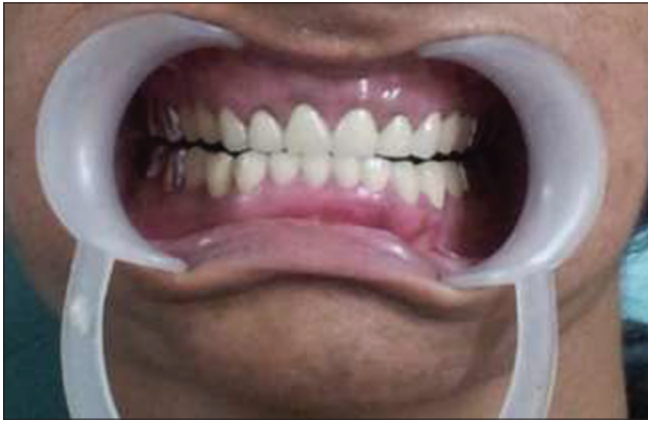

Figure 7: 8th year follow-up photo showing good anterior guidance.

Clinical Significance

Full mouth rehabilitation with an interdisciplinary approach remains the mode of treatment for patients with conditions like AI because these are conditions that cannot be prevented unless some revolutionary discoveries occur in the field of genetic science.

References

1. Aldred MJ, Savarirayan R, Crawford PJ. Amelogenesis imperfecta: A classification and catalogue for the 21st century. *Oral Dis* 2003;9(1):19-23.
2. Stephanopoulos G, Garefalaki ME, Lyroudia K. Genes and related proteins involved in amelogenesis imperfecta. *J Dent Res* 2005;84(12):1117-26.
3. Witkop CJ Jr. Amelogenesis imperfecta, dentinogenesis imperfecta and dentin dysplasia revisited: Problems in classification. *J Oral Pathol* 1988;17(9-10):547-53.
4. Ayers KM, Drummond BK, Harding WJ, Salis SG, Liston PN. Amelogenesis imperfecta – Multidisciplinary management from eruption to adulthood. Review and case report. *N Z Dent J* 2004;100(4):101-4.
5. Jankelson RR. *Neuromuscular Dental Diagnosis and Treatment*, 2nd ed. Tokyo: Ishiyaku Euro America; 1990.
6. Siadat H, Alikhasi M, Mirfazaelian A. Rehabilitation of a patient with amelogenesis imperfecta using all-ceramic crowns: A clinical report. *J Prosthet Dent* 2007;98(2):85-8.
7. Nel JC, Pretorius JA, Weber A, Marais JT. Restoring function and esthetics in a patient with amelogenesis imperfecta. *Int J Periodontics Restorative Dent* 1997;17(5):478-83.
8. Williams WP, Becker LH. Amelogenesis imperfecta: Functional and esthetic restoration of a severely compromised dentition. *Quintessence Int* 2000;31(6):397-403.
9. Mongini F, Tempia-Valenta G, Conserva E. Habitual mastication in dysfunction: A computer-based analysis. *J Prosthet Dent* 1989;61(4):484-94.
10. Neill DJ, Howell PG. Computerized kinesiography in the study of mastication in dentate subjects. *J Prosthet Dent* 1986;55(5):629-38.
11. Makarita H. Full-mouth rehabilitation and bite management of severely worn dentition. *J Cosmet Dent* 2008;24:84-96.