



Case report

Tracheomegaly and tracheoesophageal fistula following mechanical ventilation: A case report and review of the literature



Canan Kucuk ^{a,*}, Kemal Arda ^b, Naim Ata ^c, Mustafa Hamidullah Turkkani ^d,
Özgür Ömer Yildiz ^e

^a Ankara 29 Mayıs Hosp., Dept of Anesthesiology and Reanimation, Turkey

^b Ankara Atatürk Research and Education Hosp., Dept of Radiology, Turkey

^c Ankara 29 Mayıs Hosp., Dept of Internal Medicine, Turkey

^d Ankara 29 Mayıs Hosp., Dept of Chest Disease, Turkey

^e Diskapi Yıldırım Beyazıt Research and Education Hosp., Dept of Chest Surgery, Turkey

ARTICLE INFO

Article history:

Received 6 November 2015

Received in revised form

25 January 2016

Accepted 1 February 2016

Keywords:

Tracheoesophageal fistula

Acquired

Mechanical ventilation

Tracheomegaly

Complication

Anesthesiology

ABSTRACT

Postintubation Tracheoesophageal fistula (TEF) is a rare complication. Acquired TEF most commonly occurred following prolonged mechanical ventilation with an endotracheal or tracheostomy tube, cuff-related tracheal injury, post-intubation injury. We present a case of both tracheomegaly and tracheoesophageal fistula following mechanical ventilation for 15 days, in the light of the literature.

© 2016 The Authors. Published by Elsevier Ltd. This is an open access article under the CC BY-NC-ND license (<http://creativecommons.org/licenses/by-nc-nd/4.0/>).

1. Introduction

Tracheoesophageal fistula (TOF), which is a life threatening condition, may be congenital or acquired. It is the connection between the esophagus and the tracheobronchial tree or the other mediastinal structures. Most of the patients with TOFs are diagnosed following birth or during infancy. Acquired TOFs mostly occur secondary to several malignancies (i.e. esophageal cancer), infection, ruptured diverticula, and injuries [1]. Figs. 1–4

Post-intubation TOFs infrequently occur following prolonged mechanical ventilation with an endotracheal or tracheostomy tube, cuff-related tracheal injury, and post intubation injury.

Tracheomegaly is marked dilatation of the trachea. It is associated with long-term smoking, chronic bronchitis, pulmonary emphysema, cystic fibrosis, pulmonary fibrosis, multiple

chondritis, and Ehlers–Danlos syndrome [2]. Due to mechanical ventilation with high cuff pressures, acquired tracheomegaly may also develop [3]. In addition, acquired TOFs are common following prolonged intubation. They may develop within 12–200 days of mechanical ventilation [4]. Predisposing factors for an acquired TOF are poor overall health, poor nutritional status, airway infections, episodic hypotension, restless/awake patients, diabetes mellitus, steroid therapies, posterior counter-pressure by nasogastric tubes, and long-term mechanical ventilation [5].

Herein, we present a 64-year-old female case of both tracheomegaly and a TOF following mechanical ventilation for 15 days.

2. Case report

A 64-year-old quadriplegic women (height:150 cm, body weight:45 kg) was admitted to the intensive care unit due to respiratory failure in another facility. She had been quadriplegic for six years. She received controlled mechanical ventilation for respiratory failure due to pulmonary infection for three weeks. She was followed by bi-level positive airway pressure (BIBAP) ST mode for one week. She was referred to the palliative care unit in our hospital

* Corresponding author. Mustafa Kemal Mahallesi Barış Sitesi 2091, Sokak No: 14 Cankaya, Ankara, Turkey.

E-mail addresses: canankuc@yahoo.com (C. Kucuk), kemalarda@yahoo.com (K. Arda), atanaim@gmail.com (N. Ata), mhturkkani@gmail.com (M.H. Turkkani), dr.ooyildiz@gmail.com (Ö.Ö. Yildiz).

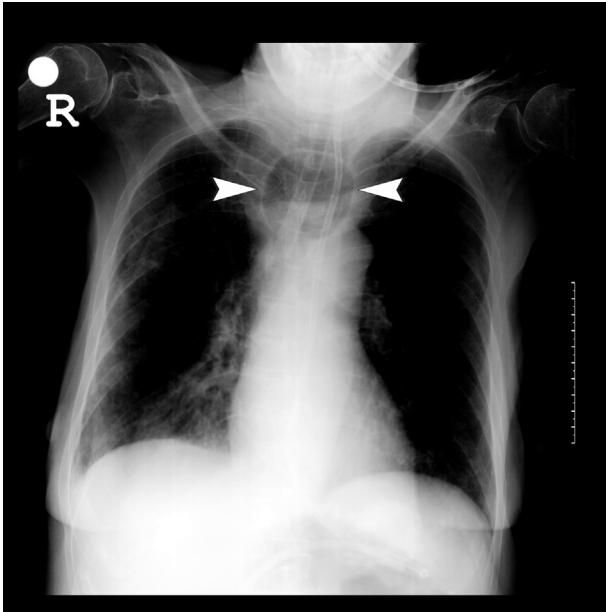


Fig. 1. On plain thoracic X-ray, Tracheomegaly and cuff of endotracheal tube can be seen (arrow head).

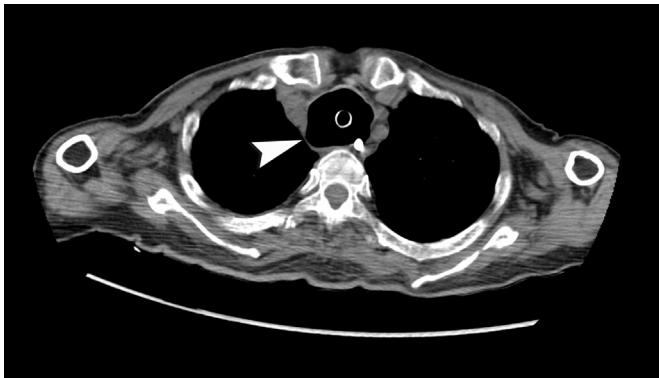


Fig. 2. On CT examination Tracheomegaly and cuff of endotracheal tube in trachea and nasogastric tube were seen in Fig. 2, and fistula was seen Fig. 3 (arrow heads).

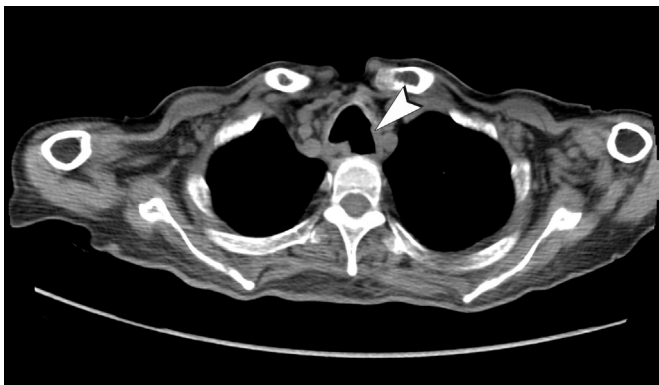


Fig. 3. On CT examination Tracheomegaly and cuff of endotracheal tube in trachea and nasogastric tube were seen in Fig. 2, and fistula was seen Fig. 3 (arrow heads).

to instruct her husband on feeding the patient via the nasogastric tube and using BIBAP-ST at home. However, we were unable to feed

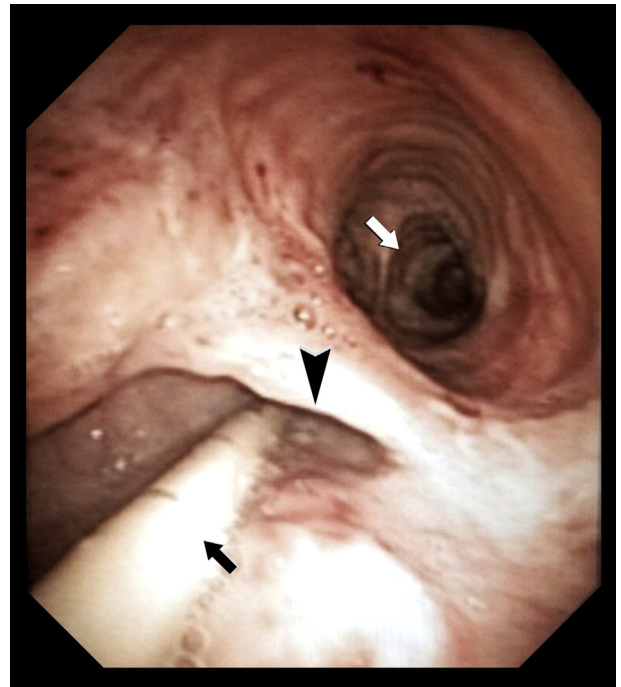


Fig. 4. Bronchoscopic examination confirmed fistula (black arrow head), nasogastric tube (black arrow), also carina could be seen (White arrow).

her via the nasogastric tube. We noticed bubbling on her chest resembling an accumulation of sputum. The arterial blood gas showed severe hypoxemia: pH: 7.27, PaCO₂: 66.28 mmHg, PaO₂: 53.4 mmHg, HCO₃⁻: 11. She was re-intubated with an 8-mm endotracheal tube in our intensive care unit. We inflated the cuff with 15 mL air due to the peritubal air leakage to control ventilation. The thoracic X-ray revealed that the maximum transverse diameter of the trachea was 6 cm on the thoracic computed tomography (CT) and the maximum transverse diameter of trachea was 4.2 cm (GE, Lightspeed VCT, USA). She developed tracheomegaly during mechanical ventilation. Despite re-intubation, we were unable to feed her via the nasogastric tube. A milky substance similar to tube feeding material was also aspirated from her endotracheal tube and a TEF was highly suspected. Thoracic CT scan revealed a TOF between the mid-esophagus and the tracheal carina and bronchoscopy demonstrated a fistula 3 cm in diameter located at the membranous portion of the carina. The patient was placed on total parenteral nutrition (TPN) and treated conservatively. After bronchoscopy and consultation with thoracic surgeon, we considered that there was no chance for treatment due to the localization and large diameter of the fistulae. Spontaneous healing of fistulae was waited. Gastrostomy and feeding jejunostomy were performed to drain the gastric content and facilitate feeding.

3. Discussion

Tracheomegaly is often diagnosed when the transverse diameter of the trachea is greater than normal and exceeds 25 mm and 21 mm in men and women, respectively. Our patient had a 6 cm transverse diameter of the trachea on the chest radiography, and 4.2 cm in diameter on the thoracic CT. The etiologies of tracheomegaly are various. Some authors suggest that tracheomegaly can develop by ventilator therapy, barotrauma, smoking, and chronic irritants. During mechanical ventilation, pressure on the tracheal

wall could contribute to the development of tracheomegaly [3].

On the other hand, TEFs can be classified into congenital and acquired conditions. Acquired origins can be subdivided into benign or malignant forms. Among the benign conditions, prolonged mechanical ventilation is the most common (47%), followed by injury (17%), prior laryngectomy (17%), and prior esophagotomy (17%) (6). In the malignant category of TEFs, esophageal tumors accounts for three-fourths of total cases [6].

Post-intubation TEF is a rare and potentially fatal clinical condition. Definitive surgical repair is usually needed to restore the patient's normal respiration and oral intake. Untreated TEFs may lead to death [7]. Certain risk factors include excessive motion of the tracheal tube, high cuff pressure, prolonged duration of intubation, respiratory and esophageal infections, steroid use, hypotension, immunosuppression, diabetes mellitus, advanced age, and the use of a nasogastric tube [8]. It has been reported that surgical repair combining the direct primary suture closure of tracheal and esophageal defects and interposition of a pedicled soft tissue flap provides the best outcome and opportunity to resume oral intake. Spontaneous closure is rarely seen [7–10]. Nevertheless, conservative treatment, including re-positioning the endotracheal tube below the fistula site, removing the nasogastric tube, and establishing gastrostomy and feeding jejunostomy may not only be a palliative therapy for ventilator-dependent patients, but may also provide an opportunity for complete healing.

Furthermore, high intra-cuff pressure is likely the single most important factor in the development of TEF [9,10]. Total obstruction of the tracheal blood flow occurs at pressure >50 cm H₂O and in patients with hypotension, even a cuff pressure of 34 cm of H₂O may cause signs of tracheal damage. Excessive movement of the tube can occur while positioning, suctioning or by weighing down by the ventilator equipment. The utilization of a nasogastric tube reflects more pressure on the posterior wall and it acts as an abrasive surface against the anterior esophageal wall [11].

Damage to the mucous membranes caused by an endotracheal tube can also result in destruction of the mucous membranes and cartilage, causing tracheomalacia and fibrous stenosis, and eventually perforation may occur between the membranous portion of the trachea and the front part of the esophagus, leading to the formation of a TEF [12]. In our case, TEF occurred while having a nasogastric tube and intubation for respiratory failure, and poor overall and nutritional status. Acquired, non-malignant TEFs usually results from the erosion of the tracheal and esophageal walls by endotracheal or tracheostomy tube cuffs, particularly when a rigid nasogastric tube is in place. This life-threatening condition is infrequent with the use of high-volume and low pressure cuffs. Therefore, higher intra-cuff pressures are required to maintain the cuff's sealing effect in intubated patients. Prolonged intubation and the presence of a wide-bore gastric tube may yield pressure on the sandwiched mucosa between the cuff of the tracheal tube and the gastric tube. In addition, excessive motion of the tracheal tube during frequent dressing changes and respiratory care is another predisposing factor. Local infection may worsen the mucosal damage, resulting in perforation.

The duration of artificial ventilation by means of a tracheal tube in these patients exerts abasic influence on the occurrence of this complication.

Moreover, endotracheal tube cuff pressures in the intensive care units are often high and are significantly elevated. Endotracheal tube cuff pressures should be routinely measured by a manometer to minimize injuries to the tracheal mucosa and surrounding structures. Many different tracheostomy tubes are available that are constructed of different materials; in different sizes, shapes, and cuff design. Tubes should be selected with care, based on the patient's body habits, ventilator capacity, and aspiration risk.

Tracheostomy tube cuff volumes and pressures require constant monitoring to avoid tracheal injuries. Previous literature data recommended routine inflation and deflation of cuffs every few hours; however, this has not been shown to reduce the risk of tracheal injury, and it actually increases the risk for aspiration [13]. As cuff pressures >30 cm H₂O compress mucosal capillaries and impair blood flow with total occlusion occurring at 50 cm H₂O, it is usually recommended that cuff pressures do not exceed 20 cm H₂O. However, monitoring cuff pressure alone is insufficient, since tracheal damage and increased cuff volumes can occur, even when cuff pressures are maintained within the desired range. Cuff volumes should not exceed 6–8 ml, ideally; and the need to inflate the cuff to >10 ml should raise concerns about tracheal injury [14]. High-compliance endotracheal tube cuffs are used to prevent gas leaks and pulmonary aspiration in mechanically ventilated patients. However, the use of the usual cuff inflation volumes produces transmission of the pressure directly to the tracheal wall around the cuffs. When the cuff pressure is over 40 cm H₂O, which is the perfusion pressure of the tracheal mucosa and submucosa, a loss of mucosal cilia, ulceration, bleeding, tracheal stenosis, and TEFs may occur.

A patient with acquired TEF should be provided with good supportive therapy, measures taken to prevent aspiration and pulmonary infections aggressively managed. If a patient is on a ventilator, the TEF may fail to close. A spontaneously breathing and nutritionally fit patient is a prerequisite for the success of the therapy. The site and size of the lesion must be carefully noted. Failure to ventilate, due to intubation of the lumen of a large TEF is a major concern. Proper selection of an appropriate size endotracheal tube, frequent cuff pressure monitoring (maintaining cuff pressure between 20 and 30 mm of H₂O), minimal endotracheal tube movement on positioning/suctioning, and using a flexible nasogastric tube prevent the occurrence of TEF [15].

It is often challenging to diagnose a TEF using a plain thoracic X-ray, and diagnosis may require an upper GI series using a contrast medium [16]. Also, it is difficult to diagnose a TEF at an early stage, and there are many cases where a diagnosis is made after the start of inflammation in the lungs during mechanical ventilation or after death. The optimal diagnostic method is to confirm the existence and degree of a fistula through the esophagus or by bronchoscopy [16,17].

In the literature, spontaneous healing of fistulae has been reported in patients with acquired benign TEFs; thus, retrievable stents should be used, if applicable. Acquired benign TEFs at the level of the carina may not respond well to conventional management. There are several surgical treatment options available, including direct suturing of the esophageal defect, esophageal bypass, esophageal exclusion, and fistula resection. Additionally, fibrin sealants or glues have been utilized in small-opening fistulas [18]. In cases of advanced malignancies, palliative measures are usually employed including esophageal stenting and chemotherapy or radiation therapy to address dysphagia and the risk of pulmonary infections. However, with procedures such as stenting, there is a high incidence of esophageal perforation due to frequent need of tumor dilation [18].

In conclusion, it should be kept in mind that high cuff pressures may result in fistula development in prolonged mechanical ventilation patients with respiratory failure. Cuff pressure monitorization should be performed in all intubated patients to prevent such complications of tracheomegaly and TEFs.

References

- [1] M.F. Reed, D.J. Mathisen, Tracheoesophageal fistula, *Chest Surg. Clin. N. Am.* 13 (2) (2003) 271–289.

- [2] E. Breatnach, G.C. Abbott, R.G. Fraser, Dimensions of the normal human trachea, *AJR Am. J. Roentgenol.* 142 (1984) 903–906.
- [3] M.Y. Kim, E.J. Kim, B.W. Min, J.S. Ban, S.K. Lee, J.H. Lee, Anesthetic experience of a patient with tracheomegaly –a case report–, *Korean J. Anesthesiol.* 58 (2) (2010) 197–201.
- [4] J. Marzelle, P. Darteville, J. Khalife, A. Rojas-Miranda, A. Chapelier, P. Levasseur, Surgical management of acquired postintubation TOF, *Eur. J. Cardiothorac. Surg.* 3 (1989) 499–503.
- [5] R. Diddee, I.H. Shaw, Acquired tracheo-oesophageal fistula in adults, *Contin. Educ. Anaesth. Crit. Care Pain* 6 (3) (2006) 105–108.
- [6] A. Muniappan, J.C. Wain, C.D. Wright, D.M. Donahue, M. Gaisser H, Lanuti, et al., Surgical treatment of nonmalignant tracheoesophageal fistula: a thirty-five year experience, *Ann. Thorac. Surg.* 95 (4) (2013) 1141.
- [7] D.J. Mathisen, H.C. Grillo, J.C. Wain, et al., Management of acquired nonmalignant tracheoesophageal fistula, *Ann. Thorac. Surg.* 52 (1991) 759–765.
- [8] D.K. Pavne, W.M. Anderson, M.D. Romero, et al., Tracheoesophageal fistula formation in intubated patients: risk factors and treatment with high-frequency jet ventilation, *Chest* 98 (1990) 161–164.
- [9] N. Kastanos, R. Estopa Miro, A. Marin Perez, A. Xaublet Mir, A. Agusti-Vidal, Laryngotracheal injury due to endotracheal intubation: incidence, evolution, and predisposing factors. A long term study, *Crit. Care Med.* 11 (1983) 362–367.
- [10] J.D. Cooper, H.C. Grillo, The evolution of tracheal injury due to ventilatory assistance through cuffed tubes: a pathologic study, *Ann. Surg.* 169 (1969) 334–348.
- [11] D.C. Guyton, M.R. Barton, T.R. Besselievre, Influence of airway pressure on minimum occlusive endotracheal tube cuff pressure, *Crit. Care Med.* 25 (1997) 91–94.
- [12] H.C. Paik, D.H. Kim, H.M. Cho, D.Y. Lee, Clinical analysis of acquired tracheoesophageal fistula, *Korean J. Bronchoesophagol.* 8 (1) (2002) 61–65.
- [13] M.M. Powaser, M.C. Brown, J. Chezem, C.R. Woodburne, P. Rogenes, B. Hanson, The effectiveness of hourly cuff deflation in minimizing tracheal damage, *Heart Lung* 5 (1976) 734–741.
- [14] B.J. Make, N.S. Hill, A.I. Goldberg, J.R. Bach, G.J. Criner, P.E. Dunne, et al., Mechanical ventilation beyond the intensive care unit: report of a consensus conference of the american college of chest physicians, *Chest* 113 (1998) 289S–344S.
- [15] D. Kaur, S. Anand, P. Sharma, A. Kumar, Early presentation of postintubation tracheoesophageal fistula: perioperative anesthetic management, *J. Anaesthesiol. Clin. Pharmacol.* 28 (1) (2012) 114–116.
- [16] Y.H. Jung, C.W. Baek, J.W. Park, Y.C. Woo, G.H. Koo, Acquired-tracheoesophageal fistula observed after ventilator care, *Korean J. Anesthesiol.* 46 (2004) 122–126.
- [17] C.M. Yeh, C.M. Chou, Early repair of acquired tracheoesophageal fistula, *Asian Cardiovasc. Thorac. Ann.* 16 (2008) 318–320.
- [18] S. Yata, T. Kaminou, M. Hashimoto, Y. Ohuchi, K. Sugiura, A. Adachi, et al., Successful closure of intractable tracheoesophageal fistula using a combination of a modified silicon stent and metallic stents, *Acta Radiol. Short. Rep.* 1 (2) (2012), 19.