

# A Complicated Case of COVID-19 and Hyperglycemic Hyperosmolar Syndrome in an Adolescent Male

Anisha Gohil<sup>a</sup> Stefan Malin<sup>b</sup> Kamal Abulebda<sup>b</sup> Tamara S. Hannon<sup>a</sup>

<sup>a</sup>Division of Endocrinology & Diabetes, Department of Pediatrics, Riley Hospital for Children at IU Health, Indiana University School of Medicine, Indianapolis, IN, USA; <sup>b</sup>Division of Pediatric Critical Care, Department of Pediatrics, Riley Hospital for Children at IU Health, Indiana University School of Medicine, Indianapolis, IN, USA

## Keywords

Hyperglycemic hyperosmolar state · Diabetic ketoacidosis · Coronavirus disease 2019 infection · Type 2 diabetes

## Abstract

Emerging data demonstrate that comorbid conditions and older age are contributing factors to COVID-19 severity in children. Studies involving youth with COVID-19 and diabetes are lacking. We report the case of a critically ill adolescent male with obesity, type 2 diabetes, and COVID-19 who presented with hyperglycemic hyperosmolar syndrome (HHS). This case highlights a challenge for clinicians in distinguishing severe complications of COVID-19 from those seen in HHS. Youth with obesity and type 2 diabetes may represent a high-risk group for severe COVID-19 disease, an entity that to date has been well-recognized in adults but remains rare in children and adolescents.

© 2021 S. Karger AG, Basel

## Introduction

Emerging studies are aiding in our understanding of infection with coronavirus SARS-CoV-2 (COVID-19), but information regarding presentation and outcomes in

youth is still limited [1]. While many children may present with fever and respiratory symptoms, pediatric populations often have a less severe and more variable disease presentation as compared to adults [2]. Hundreds of children have now been diagnosed with multisystem inflammatory syndrome in children, a hyperinflammatory shock-like severe illness due to COVID-19 that is similar to Kawasaki disease [3]. While a significant portion of both pediatric and adult patients may be asymptomatic, or have symptoms not severe enough to require admission to a hospital, a large subset requires intensive care unit admission [4]. These critically ill patients are at an increased risk of requiring mechanical ventilation and having life-threatening thrombotic events [4, 5].

In a large case series of 5,700 mostly adult patients admitted with COVID-19 in New York City, the most common comorbidities were hypertension, obesity, and diabetes [6]. Adults with diabetes were more likely to develop rapid progressive disease and had increased morbidity and mortality as compared to those without diabetes [7, 8]. Data, including outcomes, for children with diabetes and COVID-19 are lacking. We report the case of an adolescent male with a complicated course of COVID-19 who presented to medical attention with new-onset type 2 diabetes with hyperglycemic hyperosmolar syndrome (HHS).

## Case

A 16-year-old African American male was in his normal state of health until he developed nonbloody and nonbilious emesis, weakness, and slurred speech. He presented to an emergency department where his initial vitals showed a heart rate of 120, blood pressure of 110/73, temperature of 37.7°C, and respiratory rate of 28 with an oxygen saturation of 98% on room air. A review of systems revealed that he had polyuria and polydipsia for multiple years but no reported weight loss. He reported no fevers or respiratory symptoms. His past medical history was positive for obesity, autism, and attention-deficit/hyperactivity disorder. His family history was unknown as he was adopted as an infant.

His growth parameters were notable for a weight of 129 kg (z-score 3.26), height of 173 cm (z-score 0.00), and BMI of 45.1 kg/m<sup>2</sup> units (z-score 2.90). His initial laboratory evaluation shown in Table 1 was consistent with new-onset diabetes with a mixed HHS and diabetes ketoacidosis (DKA) presentation. He was also noted to have leukocytosis with lymphopenia. He was given a liter bolus of normal saline and started on substantial continuous intravenous fluids carefully titrated to slowly correct his fluid deficit of approximately 6 L. Intravenous insulin was started at 0.05 units/kg/h and he was transferred to the pediatric intensive care unit at the regional children's hospital.

On the 1st day of admission, he became febrile with a peak temperature of 40.4°C. Given this new fever with associated leukocytosis and lymphopenia, a surveillance blood culture, urine culture, respiratory viral panel, and COVID-19 nasopharyngeal swab were obtained, which all came back negative. In the setting of HHS, an elevated creatine kinase level of 5,192 units/L raised concern for malignant hyperthermia. He was started on intravenous dantrolene with subsequent improvement but without resolution of his fever.

After an initial clinical improvement, on the 5th day of admission he developed refractory hypoxemia that necessitated initiation of noninvasive positive pressure ventilation. Given his body habitus and history of snoring, this was initially thought to be a consequence of obstructive sleep apnea; however, a chest x-ray revealed new bilateral lung opacities. A repeat nasopharyngeal swab was obtained and was positive for coronavirus SARS-CoV-2 (COVID-19) in addition to human rhinovirus/enterovirus and parainfluenza 4 virus. His hypoxemia worsened and he was ultimately intubated for acute hypoxemic respiratory failure and severe acute respiratory distress syndrome.

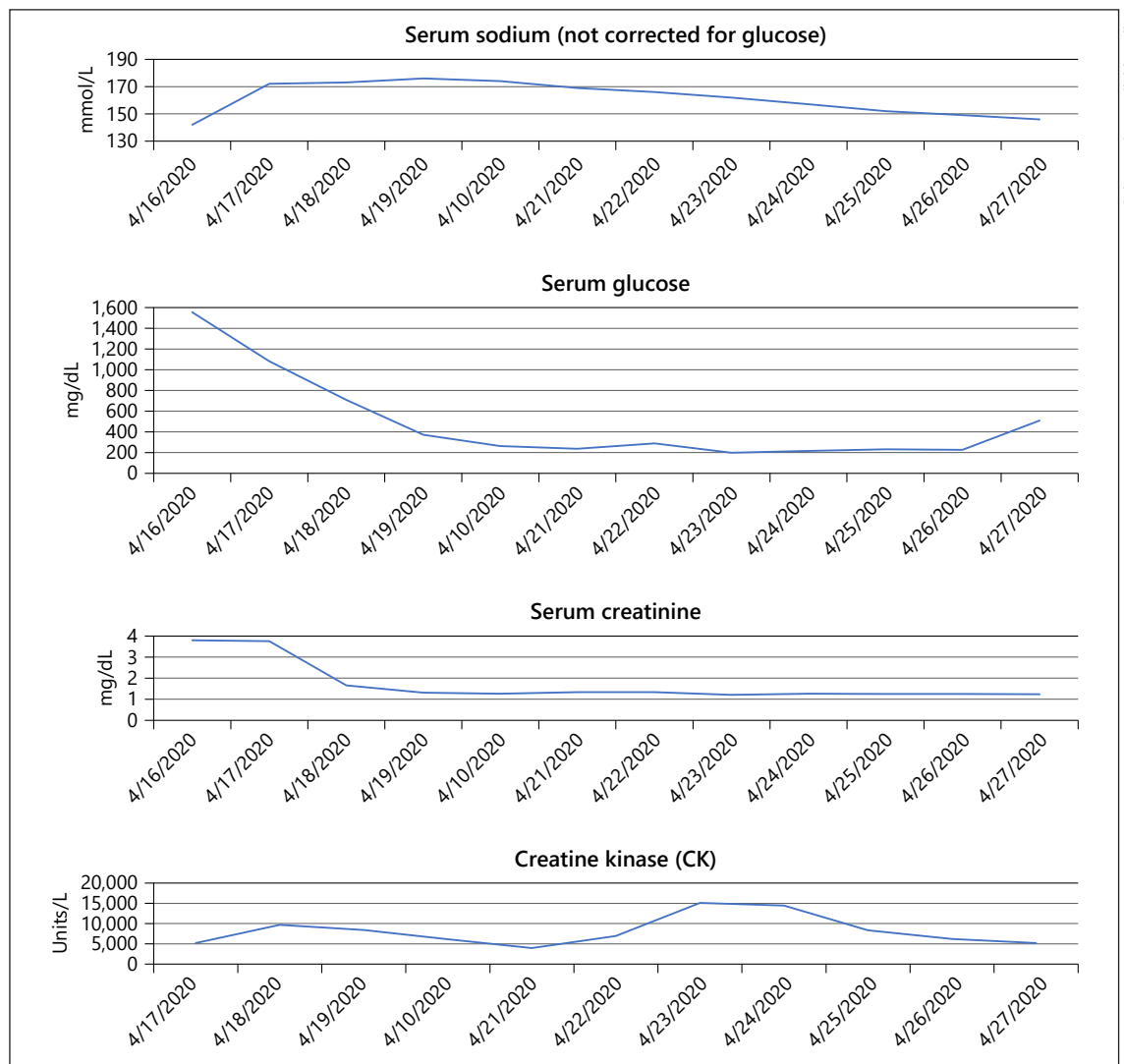
**Table 1.** Characteristics and significant laboratory values at presentation

Age	16 year 0 months
Sex	Male
Ethnicity	African American
Weight	129 kg (z-score 3.26)
Height	173 cm (z-score 0.00)
BMI	45.1 kg/m <sup>2</sup> (z-score 2.90)
HbA1c	9.9%
Diabetes Autoantibodies	GAD65, insulin, and IA-2 negative
Labs at presentation	
Glucose	>1,250 mg/dL
Bicarbonate	<8 mmol/L
Sodium	139 mmol/L
Glucose-corrected sodium	157 mmol/L
Venous pH	7.1
Urine ketones	5 mg/dL

His clinical course was complicated by severe hypernatremia (peak sodium level 174 mmol/L), dehydration, and acute kidney injury (creatinine 3.8 mg/dL); however, these all improved with fluid resuscitation with isotonic crystalloid and slow correction of hyperglycemia. It is important to note that while correction of severe hypernatremia in HHS indicated the need for aggressive fluid resuscitation, the ability to give large fluid volumes was limited by his acute respiratory distress syndrome. As this occurred, he was diagnosed with type 2 diabetes as his hemoglobin A1c was 9.9% and GAD65, insulin, and IA-2 autoantibodies were negative.

Treatment with remdesivir was considered but ultimately not given due to the patient's acute kidney injury. He was started on IV corticosteroids and inhaled nitric oxide and was eventually placed into a specialized medical bed for proning. He was given tocilizumab and convalescent serum on the 7th and 8th days of admission, respectively, for cytokine release syndrome. Over the subsequent 4 days, his inflammatory markers improved, but his d-dimer rose from 690 to 3,170 ng/mL. Due to reports of increased thrombosis risk in critically ill patients infected with SARS-CoV-2, the patient was started on heparin infusion for thrombosis prophylaxis as soon as he was diagnosed with COVID-19. The heparin was converted to lovenox once his kidney function improved. The trend of notable laboratory and inflammatory markers are found in Figures 1 and 2.

On the 12th day of admission, his clinical course acutely worsened. He developed slowly worsening and persistent tachycardia without an identifiable cause that did not improve with IV fluid administration. An echocardiogram revealed a hypovolemic and hyperdynamic left ven-



Color version available online

**Fig. 1.** Trend of notable laboratory markers in case patient.

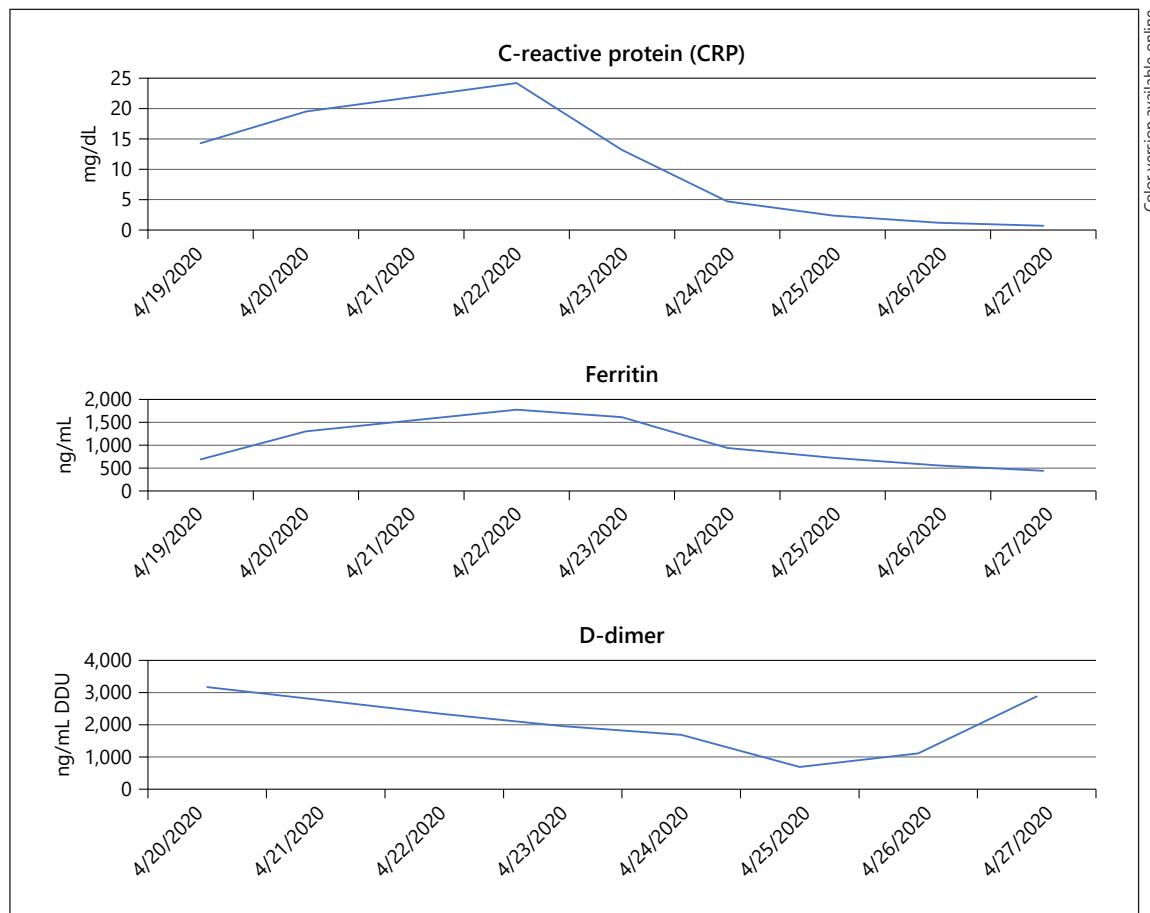
tricle; the right ventricle was unable to be visualized. Shortly afterward, his sinus tachycardia devolved into junctional rhythm that progressed to pulseless ventricular tachycardia. Despite 40 min of cardiopulmonary resuscitation efforts and a dose of tissue plasminogen activator for concern for pulmonary embolism, he never regained a perfusing rhythm.

### Discussion

We describe the case of an adolescent male with obesity and type 2 diabetes who had complications (respiratory failure, rhabdomyolysis, and suspected thrombosis) of

COVID-19 infection similar to those seen in adults [5, 6, 8, 9]. Compared to other children and adolescents, youth with type 2 diabetes are more likely to have hypertension and obesity [10], the same comorbidities noted in adults with complex clinical courses of COVID-19 [6, 8]. In North American PICUs, results from a cross-sectional study of 48 children with COVID-19 demonstrated 83% had preexisting medical conditions, 8% had diabetes, and 7% had obesity [11]. Within the pediatric age range, adolescents and young adults with COVID-19 as opposed to younger children are at the highest risk for severe disease [12].

We suspect the patient's 1st COVID-19 test was a false negative. Multiple studies have shown that the multitude of tests currently available on the market have a wide



**Fig. 2.** Trend of inflammatory markers in case patient.

range of specificity, with false negative rates of up to 29% [13–15]. For this reason, it is important to have a high clinical suspicion to retest.

COVID-19 may trigger DKA or HHS in individuals with poorly controlled or new-onset diabetes [16]. Kim et al. [17] reported 2 cases of adults with type 2 diabetes and severe cases of COVID-19, one who presented with DKA and the other with HHS. To the best of our knowledge, our case is the 1st report of COVID-19 associated with HHS in the pediatric population.

In youth, HHS has a high mortality rate particularly in African American males with obesity [18], and therefore patients with these characteristics likely represent a group at high risk for severe complications from COVID-19. It is important to recognize the overlapping clinical complications of COVID-19 and HHS such as rhabdomyolysis, thrombosis, and fever [19]. Our patient developed fever and rhabdomyolysis that was initially thought due to malignant hyperthermia; however, on review of clinical data,

he was noted to have a partial pressure of carbon dioxide of 37 during this initial course, and this never was higher than 48 prior to intubation. In the setting of malignant hyperthermia, increased muscle metabolism results in rapid carbon dioxide production. In patients who are not intubated, they can compensate for this by increasing their minute ventilation; but they should not have difficulties oxygenating, which this patient developed [20]. In retrospect, this patient's initial fever and elevated creatine kinase were most consistent with the early viral syndrome of COVID-19. This highlights a challenge for the clinician to determine the etiology for these severe complications during the current pandemic.

As seen in our case, youth with type 2 diabetes and COVID-19 may have severe disease. It is important to consider complications that are typically seen in adults when treating adolescents with type 2 diabetes, as the same pro-inflammatory state may predispose to more severe disease progression and outcomes from COVID-19 [21]. So far

data suggest that children with type 1 diabetes who develop COVID-19 have a mild disease presentation similar to what is observed in children without diabetes [22]. However, in youth obesity is a risk factor for severe complications from COVID-19 [23]. Since adolescents with type 2 diabetes typically have obesity, these youth are likely at higher risk for a more complicated clinical course from COVID-19. Studies looking at characteristics of youth with type 2 diabetes and COVID-19 are warranted in order to improve outcomes and develop management strategies.

### Statement of Ethics

Ethics Committee approval was not obtained because we report a case report of a single individual, we have not included any identifiable information, and we obtained written consent for publication of this case report from the patient's mother; therefore, the paper is exempt from Ethics Committee approval.

### References

- 1 Cruz AT, Zeichner SL. COVID-19 in children: initial characterization of the pediatric disease. *Pediatrics*. 2020 Jun;145(6):e20200834.
- 2 Ludvigsson JF. Systematic review of COVID-19 in children shows milder cases and a better prognosis than adults. *Acta Paediatr*. 2020;109(6):1088–95.
- 3 Riphagen S, Gomez X, Gonzalez-Martinez C, Wilkinson N, Theocharis P. Hyperinflammatory shock in children during COVID-19 pandemic. *The Lancet*. 2020 May 23;395(10237):1607–08.
- 4 Grasselli G, Zangrillo A, Zanella A, Antonelli M, Cabrini L, Castelli A, et al. Baseline characteristics and outcomes of 1591 patients infected with SARS-CoV-2 admitted to ICUs of the Lombardy Region, Italy. *Jama*. 2020;323(16):1574–81.
- 5 Klok FA, Kruip M, Van der Meer N, Arbous M, Gommers D, Kant K, et al. Confirmation of the high cumulative incidence of thrombotic complications in critically ill ICU patients with COVID-19: an updated analysis. *Thromb Res*. 2020 Jul;191:148–50.
- 6 Richardson S, Hirsch JS, Narasimhan M, Crawford JM, McGinn T, Davidson KW, et al. Presenting characteristics, comorbidities, and outcomes among 5700 patients hospitalized with COVID-19 in the New York City area. *JAMA*. 2020 May 26;323(20):2052–59.
- 7 Guo W, Li M, Dong Y, Zhou H, Zhang Z, Tian C, et al. Diabetes is a risk factor for the progression and prognosis of COVID-19. *Diabetes Metab Res Rev*. 2020 Mar 31:e3319.
- 8 Zhou F, Yu T, Du R, Fan G, Liu Y, Liu Z, et al. Clinical course and risk factors for mortality of adult inpatients with COVID-19 in Wuhan, China: a retrospective cohort study. *Lancet*. 2020;395(10229):1054–62.
- 9 Jin M, Tong Q. Rhabdomyolysis as potential late complication associated with COVID-19. *Emerg Infect Dis*. 2020 Jul;26(7):1618–20.
- 10 Kumar S, Kelly AS. Review of childhood obesity: from epidemiology, etiology, and comorbidities to clinical assessment and treatment. *Mayo Clinic Proc*. 2017 Feb;92(2):251–65.
- 11 Shekerdeman LS, Mahmood NR, Wolfe KK, Riggs BJ, Ross CE, McKiernan CA, et al. Characteristics and outcomes of children with coronavirus disease 2019 (COVID-19) infection admitted to US and Canadian pediatric intensive care units. *JAMA Pediatr*. 2020 Sep 1;174(9):868–73.
- 12 DeBiasi RL, Song X, Delaney M, Bell M, Smith K, Pershad J, et al. Severe COVID-19 in children and young adults in the Washington, DC, Metropolitan region. *J Pediatr*. 2020 Aug;223:199–203.e1.
- 13 Woloshin S, Patel N, Kesselheim AS. False negative tests for SARS-CoV-2 infection: challenges and implications. *N Engl J Med*. 2020 Aug 6;383(6):e38.
- 14 Di Paolo M, Iacovelli A, Olmati F, Menichini I, Oliva A, Carnevalini M, et al. False-negative RT-PCR in SARS-CoV-2 disease: experience from an Italian COVID-19 unit. *ERJ Open Res*. 2020;6(2):324–2020.
- 15 Arevalo-Rodriguez I, Buitrago-Garcia D, Simancas-Racines D, Zambrano-Achig P, del Campo R, Ciapponi A, et al. False-negative results of initial RT-PCR assays for COVID-19: a systematic review. *medRxiv*. 2020;15(12):e0242958.
- 16 Rubino F, Amiel SA, Zimmet P, Alberti G, Bornstein S, Eckel RH, et al. New-onset diabetes in Covid-19. *N Engl J Med*. 2020 Aug 20;383(8):789–90.
- 17 Kim N-Y, Ha E, Moon JS, Lee Y-H, Choi EY. Acute hyperglycemic crises with coronavirus disease-19: case reports. *Diabetes Metab J*. 2020 Apr;44(2):349–53.
- 18 Morales AE, Rosenbloom AL. Death caused by hyperglycemic hyperosmolar state at the onset of type 2 diabetes. *J Pediatr*. 2004;144(2):270–3.
- 19 Zeitler P, Haqq A, Rosenbloom A, Glaser N. Hyperglycemic hyperosmolar syndrome in children: pathophysiological considerations and suggested guidelines for treatment. *J Pediatr*. 2011 Jan;158(1):9–14.e1–2.
- 20 Lin HT, Wang SC, Zuo Z, Tsou MY, Chan KH, Yuan HB. Increased requirement for minute ventilation and negative arterial to end-tidal carbon dioxide gradient may indicate malignant hyperthermia. *J Chin Med Assoc*. 2014;77(4):209–12.
- 21 Cariou B, Hadjadj S, Wargny M, Pichelin M, Al-Salameh A, Allix I, et al. Phenotypic characteristics and prognosis of inpatients with COVID-19 and diabetes: the CORONADO study. *Diabetologia*. 2020 Aug;63(8):1500–15.
- 22 DiMeglio LA, Albanese-O'Neill A, Muñoz CE, Maahs DM. COVID-19 and children with diabetes—updates, unknowns, and next steps: first, do no extrapolation. *Diabetes Care*. 2020 Nov;43(11):2631–34.
- 23 Nogueira-de-Almeida CA, Del Ciampo LA, Ferraz IS, Del Ciampo IR, Contini AA, Ued FdV. COVID-19 and obesity in childhood and adolescence: a clinical review. *Jornal Pediatr*. 2020 Sep–Oct;96(5):546–58.

### Conflict of Interest Statement

There are no conflicts of interest.

### Funding Sources

A.G. was supported by NIH grant T32DK065549.

### Author Contributions

A.G. and S.M. contributed to conceptualization and design. A.G. contributed to data analysis. A.G. wrote the original draft of the manuscript. S.M., K.A., and T.H. critically reviewed and edited the manuscript. S.M., K.A., and T.H. provided supervision and oversight of the manuscript. All authors have read and approved the final manuscript and agree to be accountable for all aspects of the work.