



Case Report

Bortezomib Maintenance for the Treatment of Monoclonal Gammopathy of Renal Significance

Holly Lee¹, Peter Duggan², Paola Neri², Jason Tay² and Victor H Jimenez-Zepeda².

¹ Department of Internal Medicine, Cumming School of Medicine, University of Calgary, Calgary, Canada.

² Tom Baker Cancer Center, Department of Medical Oncology and Hematology, Calgary, AB, Canada.

Competing interests: The authors have declared that no competing interests exist.

Abstract. Monoclonal gammopathy of renal significance (MGRS) defines renal diseases resulting from the nephrotoxic effects of monoclonal proteins secreted from non-malignant clonal B cells or plasma cells, that do not meet criteria for multiple myeloma, Waldenstrom's macroglobulinemia, chronic lymphocytic leukemia, or lymphomas. Renal disease in MGRS can result from monoclonal immunoglobulin deposition to different parts of the kidney and includes a wide spectrum of glomerular, tubulointerstitial and vascular renal diseases. Recognizing MGRS is important because renal outcomes are poor and treatments targeting the underlying clonal disease have been associated with improved renal survival. In this case report, we present a case of a patient with proliferative glomerulonephritis with monoclonal immunoglobulin deposits (PGNMID) subtype of MGRS who underwent a phased clone directed treatment of induction and extended maintenance therapy to achieve renal response.

Keywords: Monoclonal gammopathy, Renal disease, Glomerulonephritis, Immunoglobulin deposits.

Citation: Lee H., Duggan P., Neri P., Tay J., Jimenez-Zepeda V.H.. Bortezomib maintenance for the treatment of Monoclonal Gammopathy of Renal Significance. *Mediterr J Hematol Infect Dis* 2019, 11(1): e2019007, DOI: <http://dx.doi.org/10.4084/MJHID.2019.007>

Published: January 1, 2019

Received: September 13, 2018

Accepted: November 17, 2018

This is an Open Access article distributed under the terms of the Creative Commons Attribution License (<https://creativecommons.org/licenses/by-nc/4.0>), which permits unrestricted use, distribution, and reproduction in any medium, provided the original work is properly cited.

Correspondence to: Holly Lee, Department of Internal Medicine, Cumming School of Medicine, University of Calgary, Calgary, Canada. E-mail: holly.lee@ahs.ca

Introduction. Monoclonal gammopathy of renal significance (MGRS) is an entity that was defined in 2012 to describe a spectrum of renal diseases resulting from the nephrotoxic effects of paraproteinemia from non-malignant clonal B cells or plasma cells, and by definition does not meet criteria for multiple myeloma, chronic lymphocytic leukemia, or malignant lymphoma.¹ While renal disease such as myeloma light chain cast nephropathy or renal damage from hyperviscosity syndrome in Waldenstrom's macroglobulinemia reflect the nephrotoxicity of the monoclonal proteins produced by the underlying malignant tumor burden, renal conditions of MGRS occur independent of the size or progression of the underlying clonal disease.² The clonal size of MGRS is small and most often resembles the state of monoclonal gammopathy of undetermined significance (MGUS).³

MGRS can result from deposition of monoclonal proteins, dysregulation of complements, and activation of humoral factors.⁴ Monoclonal proteins can affect any parts of the kidney including glomerular, tubulointerstitial and vascular compartments. Glomerular lesions from monoclonal protein deposition is classified into 1) organized deposition patterns of AL amyloidosis, cryoglobulinemic glomerulonephritis (GN), and immunotactoid GN, and 2) unorganized deposition including monoclonal immunoglobulin deposition disease, proliferative glomerulonephritis with monoclonal immunoglobulin deposits (PGNMID), and C3 GN with monoclonal gammopathy. Tubulointerstitial diseases such as light chain proximal tubulopathy and renal vascular diseases from deposition of amyloid fibrils and crystalglobulinemia/cryoglobulinemia also constitute MGRS.^{2,4}

Proliferative glomerulonephritis with monoclonal immunoglobulin deposits (PGNMID) has renal biopsy features of glomerular monoclonal immunoglobulin deposition, and of the different immunoglobulin subtypes, IgG is most commonly involved. Biopsy often reveals a proliferative or membranoproliferative pattern, and some cases have reported mesangial proliferation as well.⁵⁻⁷ The distinction between MGUS and MGRS is important given that the effect of monoclonal proteins in MGRS is far from undetermined or benign.¹ Case studies have shown that PGNMID renal injury has high rates of progression, with up to 22% of patients progressing to end stage renal disease.⁸

The management of MGRS highlights the importance of timely diagnosis and initiation of therapy targeting the underlying clonal disorder to improve renal outcomes.³ Here we report a case of a patient with PGNMID subtype of MGRS who underwent clone directed treatment in a phased approach. After initial induction therapy, the patient had complete renal response (defined as proteinuria 0.5 g/day or less, albuminemia level > 30 g/L, and no more than 10% decrease in eGFR from baseline⁹) which lasted 6 months before she had recurrent proteinuria. She required re-induction followed by ongoing maintenance treatment with bortezomib. This case highlights the importance of long term follow up and a role for maintenance therapy in MGRS management.

Case Presentation. A 61-year-old female presented for assessment of anemia and microscopic hematuria. She had no other significant medical comorbidities. At presentation, her hemoglobin was 90 g/L and her creatinine was 79 $\mu\text{mol/L}$ (eGFR 69.6 mL/min/1.73m², creatinine clearance 62 mL/min). She described a history of fatigue and mild pedal edema, but denied other constitutional symptoms. Review of systems on history was otherwise unremarkable.

Investigations revealed serum free light chains of kappa 51.6 mg/L, lambda 29.4 mg/L, and elevated kappa to lambda ratio of 1.76 (normal range 0.26-1.65). Serum protein electrophoresis and immunofixation did not reveal evidence of monoclonal peak. Immunoglobulin levels were IgA 2.68, IgG 8.20, IgM 1.17 g/L. Serum albumin was 32 g/L and calcium level was 2.2 mmol/L. Initial urine studies showed proteinuria of 2.01 g/day. Urine protein electrophoresis and immunofixation did not reveal evidence of monoclonal peak. On blood work, her hepatitis screen was negative and she had negative cryoglobulins, anti-GBM, ANCA, ANA, anti-dsDNA, and rheumatoid factor levels. Her C3 and C4 were normal. HIV testing was not done at the time of diagnosis.

For work up of her significant proteinuria, she underwent an ultrasound guided renal biopsy with a total of four passes with an 18-gauge biopsy needle to the lower pole of the left kidney. Under the dissecting

microscope, samples were taken for plastics, electron microscopy, and immunofluorescence. The biopsy revealed membranoproliferative glomerulonephritis (MPGN) with IgG kappa deposition in granular and non-linear pattern, non-Randall type. On microscopic analysis, most of the glomeruli showed marked cellular proliferation with a lobular pattern and diffuse mesangial and endocapillary proliferation with basement membrane duplication. There was mild patchy interstitial fibrosis and tubular atrophy of 15% of the cortex, with no significant interstitial inflammation. Immunofluorescence microscopy revealed IgG 4+ finely granular and short pseudo-linear stain along the basement membrane with lobular accentuation. There was 2+ kappa stain. Stains for IgA, lambda and fibrinogen were negative. There were trace IgM, 3+ C3c and 3+ C1q stains. On electron microscopy, there were innumerable small subendothelial and rare subepithelial deposits, as well as extensive, but not total foot process effacement.

Bone marrow biopsy showed 3 % plasma cells by immunohistochemistry, and flow cytometry showed a slight bimodal population with lambda light chain excess. Congo red staining on the marrow sample was negative. Cardiac MRI, echocardiogram and skeletal survey did not demonstrate evidence of multiple myeloma or AL amyloidosis.

Overall, the patient was diagnosed with PGNMID subtype of MGRS. During initial clinical monitoring, she developed worsening proteinuria of up to 3.54 g/day (**Figure 1**). Treatment was started with six cycles of cyclophosphamide po 300 mg/m², bortezomib sc 1.3 mg/m², and dexamethasone po 40 mg once weekly (CyBorD). At the end of induction, her proteinuria decreased to 0.17 g/day. At this time, the treatment was stopped and she was followed clinically. Six months after the last dose of bortezomib, she had recurrent proteinuria that peaked at 2.8 g/day. She went on to receive three more cycles of CyBorD followed by bortezomib sc 1.3 mg/m² maintenance (without dexamethasone) every two weeks for the first three months, then every three weeks, and then monthly afterwards.

Hematological response was monitored by following light chain measurements per AL amyloidosis response criteria. CR was defined as negative serum and urine immunofixation and normal FLC ratio, VGPR defined as difference in free light chains (dFLC) <40 mg/L, PR defined as dFLC decrease >50%, and no response.^{3,10} Renal response was measured using the KDIGO practice guideline on glomerulonephritis.^{9,11} Complete renal response was defined as proteinuria 0.5 g/day or less, albuminemia level > 30 g/L, and no more than 10% decrease in eGFR from baseline value.⁹

With re-induction and maintenance treatment, she maintained hematological VGPR and met one of the criteria for complete renal response with near resolution

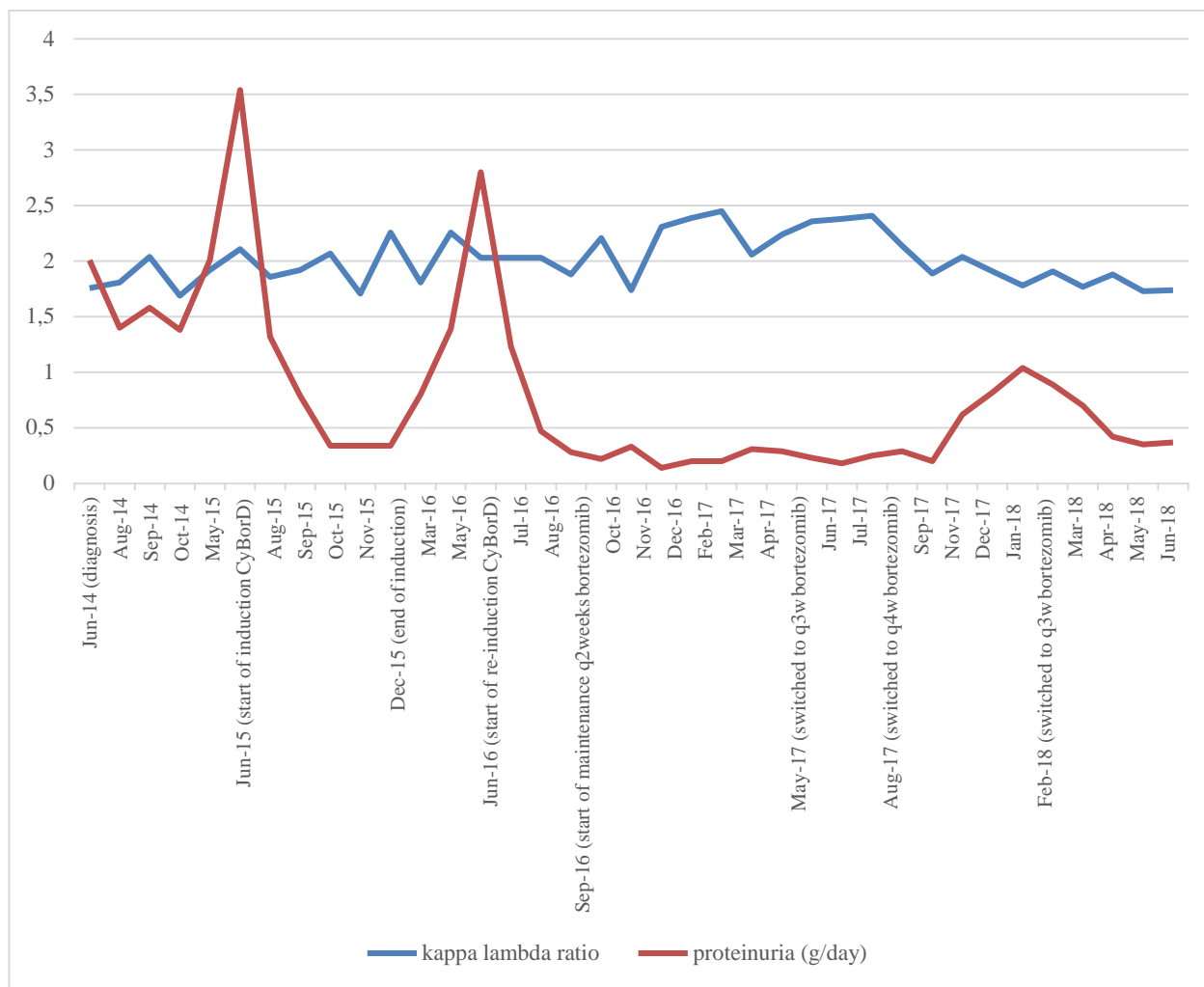


Figure 1. Serum free light chain ratio and proteinuria over 4 years

of proteinuria (0.18 – 0.29 g/day). During recent follow up on monthly bortezomib treatment, her proteinuria showed an increasing trend up to 1 g/day, and the bortezomib maintenance therapy frequency was switched back to once every three weeks. Her creatinine remained in the 60-80 umol/L throughout the course of treatment. She does not have peripheral neuropathies or gastrointestinal side effects and is tolerating ongoing bortezomib therapy.

Discussion. Proliferative glomerulonephritis with monoclonal immunoglobulin deposits (PGNMID) was first described by Nasr et al. in 2004 when 10 patients were identified who had renal biopsy findings that showed unclassifiable proliferative glomerulonephritis with monoclonal IgG deposition.¹² Biopsies most commonly showed diffuse proliferative or membranoproliferative glomerulonephritis pattern on light microscopy. Immunofluorescence studies revealed immune deposits staining for a single IgG subclass and a single light chain isotype. On electron microscopy, mesangial, subendothelial, and/ or subepithelial granular electron-dense deposits were found.¹²

In addition to a renal biopsy consistent with MPGN with IgG kappa restricted deposits, our patient had the

classical clinical presenting features of PGNMID which included microhematuria and proteinuria. Patients can also present with nephrotic syndrome or end stage renal disease.¹² The clinical course of PGNMID was reported by Nasr et al., who retrospectively assessed 37 PGNMID patients with mean follow up time of 30 months, and found that 38% had complete or partial recovery, 37% had persistent renal dysfunction, and 22% progressed to ESRD.⁸ There is a risk of recurrence of disease in renal allograft in PGNMID patients who undergo renal transplantation.^{6,13} Furthermore, Steiner et al. reported that in their retrospective observation study comparing 2891 MGUS patients versus biopsy proven 44 MGRS patients, there was a significantly higher rate of progression to multiple myeloma in MGRS patients than in MGUS patients (18 % vs 3%).¹⁴ As randomized controlled studies or prospective studies are not yet available in the field of MGRS, treatment is mainly based on expert consensus opinion and clinical experiences.³ Targeting the underlying clone is the central aspect to therapy, in addition to managing the consequences of chronic kidney disease and end stage renal disease. In the case of PGNMID, recommendations on initiation of therapy are based on the stage of chronic kidney disease and the degree of

proteinuria.³ At diagnosis, our patient had stage 2 CKD with 2.01 g of proteinuria per day, meeting indications for starting treatment.

The decision to initiate treatment in MGRS can be challenging, particularly when there is undetectable corresponding dysproteinemia or clear evidence of clonal disease in the bone marrow. Among the different types of renal diseases with monoclonal IgG deposition, PGNMID has one of the lowest rates of detection of corresponding dysproteinemia. In the 10 patients with PGNMID reported by Nasr et al., 5 had detectable serum monoclonal protein.¹² In another cohort study of 37 patients with PGNMID, only 10 patients had dysproteinemia at diagnosis and 1 patient developed a serum monoclonal peak 3 years after initial presentation.⁸ Bhutani et al. showed that in addition to the low detection rates in the serum, evidence of clonal disease in the bone marrow biopsies were found in only 25% of the patients with monoclonal immunoglobulin proliferative glomerulonephritis, and concluded that current clonal disease detection techniques may be inadequate to capture the low clonal tumor size in MGRS.¹⁵ Without detectable hematological involvement, objective assessment of disease response to therapy largely relies on monitoring renal markers.

Our patient had evidence of dysproteinemia with excess kappa chain on serum free light chain ratio, kappa restriction on renal biopsy, and lambda chain excess on bone marrow flow cytometry. Given her diagnosis of MGRS with progressive proteinuria of up to 3.54 g/day, she was started on treatment with CyBorD. Her disease response was assessed monthly by assessing free light chain measurements per AL amyloidosis response criteria,^{3,10} and the renal response was measured using the KDIGO practice guideline.^{9,11} Studies have shown that hematological response corresponds with renal response.³ Chauvet et al. showed that the depth of hematological response is associated with renal survival in MGRS. In their retrospective report on 50 patients with monoclonal gammopathy-associated C3 glomerulopathy (C3G), patients who had complete hematological response or very good partial response had higher rates of renal survival compared to those with no hematological response or partial response.¹¹

Notably in our patient, the renal response changed while the hematological response remained constant. With treatment, she remained in VGPR hematological response with no further improvement to complete hematological response, while her proteinuria decreased from 3.54 g/day to 0.17 g/day, meeting one of the criteria for complete renal response. Serum protein electrophoresis and immunofixation did not reveal evidence of monoclonal protein during follow up, and there was persistent abnormal serum free light chain ratio with dFLC <40 mg/L. When she had a recurrence of proteinuria 6 months after induction treatment, this was again not reflected in her hematological markers as she continued to remain in hematologic VGPR. In this case, the hematological response did not appear to capture disease recovery or relapse. As discussed in previous reports, it is possible that the sensitivity of the current monoclonal protein detection assays including serum free light chains or immunofixation may not be sensitive enough to capture the low levels of dysproteinemia or the small changes in the serum protein quantity.¹⁵

At the time of renal relapse, the decision on re-induction and maintenance treatment for this patient was made after seeking expert clinical opinion. This is a case of MGRS treatment using induction and prolonged maintenance bortezomib therapy. Through a single case report, it is certainly not possible to establish a role for extended therapy. Long term follow up with larger study population is required to validate the extended treatment approach. It would be interesting to assess how the time to relapse post-clone directed therapy impacts renal outcomes. We note that our patient had renal relapse within 6 months after completion of therapy. In multiple myeloma, early relapse of disease within a year of treatment portends poorer prognosis.¹⁶ Not only the depth but also the sustainability of disease response and its impact on renal survival need to be studied. Furthermore, it would be important to standardize the definition of relapse as well as indications and therapy options for relapsed MGRS.

Acknowledgements. All authors contributed to the collection, analysis, interpretation of data, and the writing of the manuscript.

References:

1. Leung, N., F. Bridoux, C.A. Hutchison, S.H. Nasr, P. Cockwell, J.P. Fermand, A. Dispenzieri, K.W. Song, and R.A. Kyle. Monoclonal gammopathy of renal significance: when MGUS is no longer undetermined or insignificant. *Blood*, 2012; 120(22): p. 4292-5 <https://doi.org/10.1182/blood-2012-07-445304> PMID:23047823
2. Rosner, M.H., A. Edeani, M. Yanagita, I.G. Glezerman, and N. Leung. Paraprotein-Related Kidney Disease: Diagnosing and Treating Monoclonal Gammopathy of Renal Significance. *Clin J Am Soc Nephrol*, 2016; 11(12): p. 2280-2287 <https://doi.org/10.2215/CJN.02920316> PMID:27526705 PMCid:PMC5142062
3. Fermand, J.P., F. Bridoux, R.A. Kyle, E. Kastritis, B.M. Weiss, M.A. Cook, M.T. Drayson, A. Dispenzieri, and N. Leung. How I treat monoclonal gammopathy of renal significance (MGRS). *Blood*, 2013; 122(22): p. 3583-90. <https://doi.org/10.1182/blood-2013-05-495929> PMID:24108460
4. Leung, N., M.E. Drosou, and S.H. Nasr. Dysproteinemias and Glomerular Disease. *Clin J Am Soc Nephrol*, 2018; 13(1): p. 128-139. <https://doi.org/10.2215/CJN.00560117> PMID:29114004
5. Al-Hussain, T., M.H. Hussein, H. Al Mana, and M. Akhtar. Renal involvement in monoclonal gammopathy. *Adv Anat Pathol*, 2015;

- 22(2): p. 121-34.
<https://doi.org/10.1097/PAP.000000000000056> PMID:25664947
6. Nasr, S.H., S. Sethi, L.D. Cornell, M.E. Fidler, M. Boelkins, F.C. Fervenza, F.G. Cosio, and V.D. D'Agati. Proliferative glomerulonephritis with monoclonal IgG deposits recurs in the allograft. *Clin J Am Soc Nephrol*, 2011; 6(1): p. 122-32.
<https://doi.org/10.2215/CJN.05750710>
 PMID:20876681 PMCID:PMC3022233
 7. Lusco, M.A., A.B. Fogo, B. Najafian, and C.E. Alpers. AJKD Atlas of Renal Pathology: Proliferative Glomerulonephritis With Monoclonal Immunoglobulin Deposits. *Am J Kidney Dis*, 2016; 67(3): p. e13-5.
<https://doi.org/10.1053/j.ajkd.2016.01.003> PMID:26916379
 8. Nasr, S.H., A. Satoskar, G.S. Markowitz, A.M. Valeri, G.B. Appel, M.B. Stokes, T. Nadasdy, and V.D. D'Agati. Proliferative glomerulonephritis with monoclonal IgG deposits. *J Am Soc Nephrol*, 2009; 20(9): p. 2055-64.
<https://doi.org/10.1681/ASN.2009010110>
 PMID:19470674 PMCID:PMC2736767
 9. Radhakrishnan, J. and D.C. Cattran. The KDIGO practice guideline on glomerulonephritis: reading between the (guide)lines--application to the individual patient. *Kidney Int*, 2012; 82(8): p. 840-56.
<https://doi.org/10.1038/ki.2012.280> PMID:22895519
 10. Palladini, G., A. Dispenziera, M.A. Gertz, S. Kumar, A. Wechalekar, P.N. Hawkins, S. Schonland, U. Hegenbart, R. Comenzo, E. Kastiritis, M.A. Dimopoulos, A. Jaccard, C. Klersy, and G. Merlini. New criteria for response to treatment in immunoglobulin light chain amyloidosis based on free light chain measurement and cardiac biomarkers: impact on survival outcomes. *J Clin Oncol*, 2012; 30(36): p. 4541-9.
<https://doi.org/10.1200/JCO.2011.37.7614> PMID:23091105
 11. Chauvet, S., V. Fremeaux-Bacchi, F. Petitprez, A. Karras, L. Daniel, S. Burtay, G. Choukroun, Y. Delmas, D. Guerrot, A. Francois, M. Le Quintrec, V. Javaugue, D. Ribes, L. Vrigneaud, B. Arnulf, J.M. Goujon, P. Ronco, G. Touchard, and F. Bridoux. Treatment of B-cell disorder improves renal outcome of patients with monoclonal gammopathy-associated C3 glomerulopathy. *Blood*, 2017; 129(11): p. 1437-1447.
<https://doi.org/10.1182/blood-2016-08-737163> PMID:28069603
 12. Nasr, S.H., G.S. Markowitz, M.B. Stokes, S.V. Seshan, E. Valderrama, G.B. Appel, P. Aucouturier, and V.D. D'Agati. Proliferative glomerulonephritis with monoclonal IgG deposits: a distinct entity mimicking immune-complex glomerulonephritis. *Kidney Int*, 2004; 65(1): p. 85-96.
<https://doi.org/10.1111/j.1523-1755.2004.00365.x> PMID:14675039
 13. Lorenz, E.C., S. Sethi, N. Leung, A. Dispenziera, F.C. Fervenza, and F.G. Cosio. Recurrent membranoproliferative glomerulonephritis after kidney transplantation. *Kidney Int*, 2010; 77(8): p. 721-8.
<https://doi.org/10.1038/ki.2010.1> PMID:20130531
 14. Steiner, N., G. Göbel, P. Suchecki, W. Prokop, H. Neuwirt, and E. Gunsilius. Monoclonal gammopathy of renal significance (MGRS) increases the risk for progression to multiple myeloma: an observational study of 2935 MGUS patients. *Oncotarget*, 2018; 9(2): p. 2344-56. <https://doi.org/10.18632/oncotarget.23412>
 PMID:29416776 PMCID:PMC5788644
 15. Bhutani, G., S.H. Nasr, S.M. Said, S. Sethi, F.C. Fervenza, W.G. Morice, P.J. Kurtin, F.K. Buadi, D. Dingli, A. Dispenziera, M.A. Gertz, M.Q. Lacy, P. Kapoor, S. Kumar, R.A. Kyle, S.V. Rajkumar, and N. Leung. Hematologic characteristics of proliferative glomerulonephritides with nonorganized monoclonal immunoglobulin deposits. *Mayo Clin Proc*, 2015; 90(5): p. 587-96.
<https://doi.org/10.1016/j.mayocp.2015.01.024> PMID:25939936
 16. Kumar, S., S.T. Mahmood, M.Q. Lacy, A. Dispenziera, S.R. Hayman, F.K. Buadi, D. Dingli, S.V. Rajkumar, M.R. Litzow, and M.A. Gertz. Impact of early relapse after auto-SCT for multiple myeloma. *Bone Marrow Transplant*, 2008; 42(6): p. 413-20.
<https://doi.org/10.1038/bmt.2008.180> PMID:18587435