

Received: 2016.09.10  
Accepted: 2016.12.08  
Published: 2017.03.14

ISSN 1941-5923  
© Am J Case Rep, 2017; 18: 263-266  
DOI: 10.12659/AJCR.901501

# Metastatic Colonic Adenocarcinoma to the Extrahepatic Common Bile Duct: The Critical Role of the Pathologist and Immunohistochemistry in Guiding Patient Care Decisions

Department of Pathology, Louisiana Health Science Center, Shreveport, LA, U.S.A.

Authors' Contribution:  
Study Design A  
Data Collection B  
Statistical Analysis C  
Data Interpretation D  
Manuscript Preparation E  
Literature Search F  
Funds Collection G

ABCDEF **Kurt J. Knowles**  
ABEF **Shoujun Chen**  
ABCDEF **Guillermo A. Herrera**

**Corresponding Author:** Kurt J. Knowles, e-mail: [kknow2@lsuhsc.edu](mailto:kknow2@lsuhsc.edu)  
**Conflict of interest:** None declared

**Patient:** Male, 49  
**Final Diagnosis:** Acute hepatitis  
**Symptoms:** Malaise • fatigue and dyspnea  
**Medication:** —  
**Clinical Procedure:** —  
**Specialty:** Gastroenterology and Hepatology

**Objective:** Rare co-existence of disease or pathology


**Background:** Adenocarcinoma of the colon frequently invades adjacent organs, spreads intraperitoneal, and metastasizes to intestinal lymph nodes, lungs, and the liver. Metastasis solely to the extrahepatic bile duct is extremely rare and has only been previously reported on 15 occasions. The accurate determination that an extrahepatic common bile duct lesion is of colonic origin has critical therapeutic implications.

**Case Report:** The patient was a 50-year-old male with a history of colon cancer S/P surgical resection in September 2014. At that time, the tumor extended to the serosal margin, and was staged as pT4a NO MX stage II. In April of 2016, the patient was admitted to our facility and an ERCP was performed. A biopsy was performed during the ERCP followed by sphincterotomy and metal stent placement. The surgical pathology revealed an adenocarcinoma with surrounding benign glandular structures. The surrounding benign glands served as an appropriate control when compared to the malignant glands. The benign glands were positive for CK-7 and the malignant glands were negative for CK-7. The malignant glands were also positive for CK-20 and CDX-2, and the benign glands were negative for CK-20 and CDX-2. This profile was consistent with an adenocarcinoma metastasis from colon primary tumor.

**Conclusions:** This case superbly illustrates the critical role of the pathologist, and their knowledge and understanding of immunohistochemistry, in arriving at the correct diagnosis and in assisting surgeons and oncologists in guiding the care, management, and appropriate therapeutic decisions regarding patients. In patients with a history of colorectal carcinoma (CRC), immunohistochemistry is required to arrive at the correct diagnosis as treatment options can be very different based on diagnosis.

**MeSH Keywords:** Cholangiocarcinoma • Colorectal Neoplasms • Liver Neoplasms

**Full-text PDF:** <http://www.amjcaserep.com/abstract/index/idArt/901501>

 1287

 1

 4

 13



## Background

Adenocarcinoma of the colon frequently invades adjacent organs, spreads intraperitoneal, and metastasizes to intestinal lymph nodes, lungs, and the liver [1]. Metastasis solely to the extrahepatic bile duct (EBD) is extremely rare and has only been previously reported on 15 occasions. The accurate determination that an extrahepatic common bile duct lesion is of colonic origin has critical therapeutic implications.

## Case Report

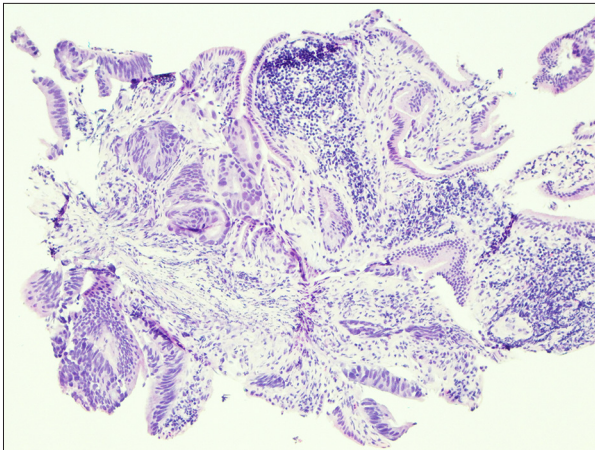
The patient was a 50-year-old male with a history of colon cancer S/P surgical resection in September 2014. At that time, the tumor extended to the serosal margin, and was staged as pT4a NO MX stage II. In April of 2016 he presented with a one-week history of jaundice, pruritus, and intense episodes of nausea and vomiting, and was admitted on April 4, 2016. On admission, his liver function tests showed ALT 109 U/L, AST 60 U/L, alkaline phosphatase 378 U/L, and total bilirubin 13.7 U/L. A MRI was performed on April 7, 2016. Intrahepatic biliary ductal dilatation was seen, up to the level of bifurcation of the common hepatic duct into the left and right hepatic ducts. The anterior branch of the right hepatic duct measured 14 mm, the posterior branch measured 13 mm, and the left hepatic duct measured 13 mm. There was a lesion in hepatic segment 4 causing obstruction at the bifurcation of the common hepatic duct. The concern was that malignant obstruction leads the differential in a patient with underlying colonic adenocarcinoma. Endoscopic retrograde cholangiopancreatography (ERCP) was performed on April 8, 2016. An intraoperative cholangiogram revealed a stricture starting after bifurcation of the hepatic duct. Initially there was no filling of the left system but selective cannulation of the left system was performed. After the bifurcation there was a 4 cm stricture with abnormal friable mucosa, neovascularization, and villous appearance highly suspicious for malignancy. Several biopsies were obtained. Thereafter, using the rapid exchange system, a 10×80 mm fully covered metal stent was placed with the proximal edge of stent proximal to the stricture with complete drainage. The surgical pathology revealed an adenocarcinoma with surrounding benign glandular structures (Figure 1). The surrounding benign glands served as an appropriate control when compared to the malignant glands. The benign glands were positive for CK-7 and the malignant glands were negative for CK-7 (Figure 2). The malignant glands were also positive for CK-20 and CDX-2 (Figure 3), and the benign glands were negative for CK-20 and CDX-2 (Figure 4). This profile was consistent with an adenocarcinoma metastasis from a colon primary tumor.

## Discussion

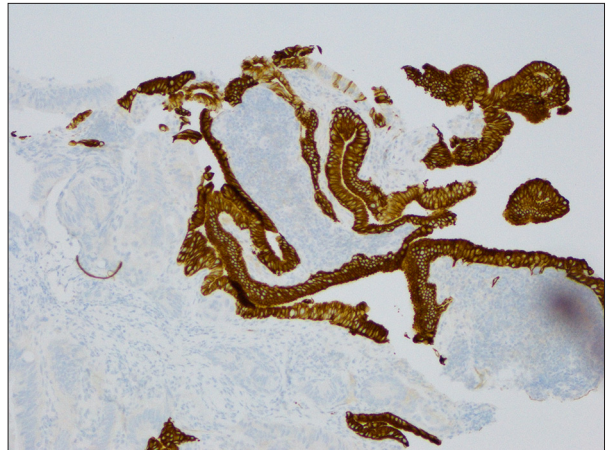
Adenocarcinoma of the colon and rectum is the second most common cause of death in the United States with approximately 50,000 deaths per year and 134,000 new cases per year [1]. In stark contrast, however, primary extrahepatic bile duct carcinoma (EBDC) is extremely uncommon, and between 1992 and 2009 there were only 6,299 cases of EBDC in the United States or about 350 cases per year [2]. In patients with a history of malignancy and an EBD lesion, it is essential to rule out metastasis to the EBD as opposed to a primary lesion, as therapy is markedly different. In patients with a history of colon cancer, it is essential to rule out metastatic disease as the liver is often the primary site of metastasis [3]. This pattern of metastasis can consist of single or multiple deposits and mimic primary cholangiocarcinoma [4,5]. There have been 15 previous case reports [5–9] and this case represents the 16th case report of CRC metastasis solely to the EBD.

It is highly probable that this scenario has occurred in the past, but the EBDC lesion was interpreted as a primary lesion. One of the earliest reported series by Lo et al. in 1994 reported on 11 cases of metastatic CRC to the EBD that were based on routine histologic sections, and it is possible that some of these lesions were primary. Primary tumors are going to be indistinguishable from metastatic CRC clinically and on routine H & E sections, and in 1994 immunohistochemistry was barely in its infancy. CK-7, CK-20, and CDX-2 (caudal type homeobox transcription factor 2), the markers used today to reliably distinguish between colorectal and EBDC, were not routinely available at that time. At the time of the Lo et al. report, a PubMed search revealed only two studies utilizing the combination of CK7 and CK20; one in 1993 [10] and one in 1994 [11], and neither of these studies was there an intent to differentiate EBDC versus CRC. During the entire decade of the 1990s, there were only 63 studies reporting the use of the two cytokeratins in combination. The expression of CDX-2 in human CRC was not reported until 1998 [12]. CDX-2 is positive in colorectal adenocarcinomas and negative in EBDC. Classically, CRC is positive for CK-20 and CDX-2 and negative for CK-7, while EBD epithelium is negative for CK-20 and CDX-2 and positive for CK-7. This case perfectly demonstrated the staining pattern for colon adenocarcinoma with an internal negative and positive control consisting of benign ECBD epithelium (Table 1) [13]. A retrospective analysis of EBD lesions utilizing immunohistochemistry and molecular analysis could prove interesting, especially if primary tumors demonstrated KRAS, BRAF or HER2/neu mutations as this might provide an additional treatment option if resection is not possible.

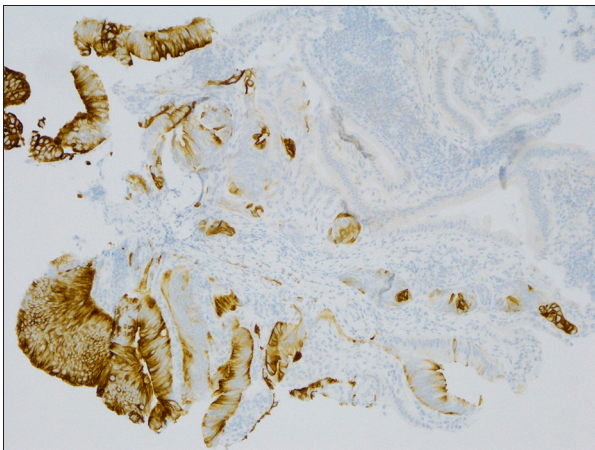
The determination that the bile duct lesion in our patient was a metastatic lesion was crucial from a therapeutic aspect. Early EBDC carcinomas have a better prognosis than more advanced lesions; however, surgery is the only treatment option that may



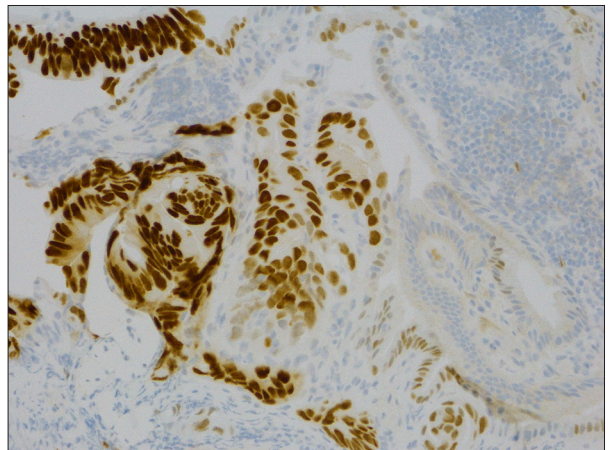
**Figure 1.** Bile duct lesion, H & E. Malignant glands on left, benign glands on right.



**Figure 2.** Cytokeratin 7 staining benign epithelium. Negative staining of malignant glands.



**Figure 3.** Cytokeratin 20 staining malignant glands. Negative staining of benign glands.



**Figure 4.** CDX 2 with intense staining of malignant glands and focally weak staining of benign glands.

**Table 1.** Immunohistochemistry used to differentiate CRC from bile duct carcinoma.

Sensitivity of individual markers	CK 7+	CK 20+	CDX 2+
CRC	14.3%	87.8%	93.9%
Bile duct	73.9%	26.1%	13.0%
Specificity of panels			
CK7-/CK20+/CDX2+	CK7+/CK20-/CDX2-		
CRC – 97.1%	Bile duct carcinoma – 98%		

Adapted from Park, et al. [13].

be curative. From a surgical aspect, cholangiocarcinomas are divided into intrahepatic, perihilar, and distal involvement. Our patient's lesion was classified as perihilar, which are typically subdivided into four types: type I tumors involve only the common hepatic duct; type II lesions involve the CHD and the

bifurcation but not the left or right intrahepatic ducts; type III lesions involve the CHD, bifurcation and either the left or right intrahepatic ducts; and type IV lesions involve both intrahepatic ducts. Type I and II tumors can be treated with surgery, which can be very extensive and complicated. The

common bile duct and involved hepatic ducts are generally excised with negative margins, then the right and left hepatic ducts are grafted to the jejunum: bilateral hepaticojejunostomies via a Roux en Y to the large bowel. If intrahepatic ducts are involved (type III), then a right or left partial hepatectomy is required. However, even with surgery, the five-year survival rate is low, from 20–40%. In our patient case, the metastatic colon cancer was stented.

Adjunct therapy may include conventional chemotherapy and/or targeted therapy directed at the vascular endothelial growth factor or epidermal growth factor receptor. Our patient had a KRAS mutation and was being treated with one of the KRAS inhibitors and had stable disease after seven months.

## Conclusions

This case superbly illustrates the critical role of the pathologist and their knowledge and understanding of

## References:

1. Bibbins DK, Grossman DC, Curry SJ et al: Screening for colorectal cancer: US preventative services Task Force Recommendation Statement. *JAMA*, 2016; 315(23): 2564–75
2. Castro FA, Koshiol J, Hsing AW, Devesa SS: Biliary tract cancer incidence in the United States – demographic and temporal variations by anatomic site. *Int J Canc*, 2013; 133(7): 1664–71
3. Hess KR, Varadhachary GR, Taylor SH et al: Metastatic patterns in adenocarcinoma. *Cancer*, 2006; 106: 1624–33
4. Riopel MA, Klimstra DS, Godellas CV et al: Intrahepatic growth of metastatic colonic adenocarcinoma: A pattern of intrahepatic spread easily confused with primary neoplasia of the biliary tract. *Am J Surg Pathol*, 1997; 21: 1030–36
5. Yamao T, Hayashi H, Higashi T et al: Colon cancer metastasis mimicking intraductal papillary neoplasm of the extra-hepatic bile duct. *Int J Surg Case Rep*, 2015; 10: 91–93
6. Lo CY, Lai EC: Palliation for extrahepatic biliary obstruction by metastatic colorectal carcinoma. *Am J Gastroenterology*, 1994; 89: 1852–55
7. Ghittoni G, Caturelli E, Viera FT: Intrahepatic duct metastasis from colonic adenocarcinoma without liver parenchyma involvement: contrast enhanced ultrasonography detection. *Abdom Imaging*, 2010; 35: 346–48
8. Strauss AT, Clayton SB, Markow M, Mamel J: Colon cancer metastatic to the biliary tree. *ACG Case Reports Journal*, 2016; 3(3): 214–16
9. Dong Y, Patel H, Patel C: Intrahepatic metastasis of colorectal carcinoma mimicking primary cholangiocarcinoma: A case report and review of the literature. *Case Rep Pathol*, 2016; 2016: 4704781
10. Betke M, Suss R, Hohenleutner U et al: Gastric carcinoma metastatic to the site of a congenital melanocytic nevus. *J Am Acad Dermatol*, 1993; 28: 866–69
11. Lo TS, Calaluze RD: Utility of cytokeratin immunostaining in separating pulmonary adenocarcinomas from colonic adenocarcinomas. *Am J Clin Pathol*, 1994; 102: 764–67
12. Wicking C, Simms LA, Evans T et al: CDX2, a human homologue of *Drosophila* caudal, is mutated in both alleles in a replication error positive colorectal cancer. *Oncogene*, 1998; 17: 657–59
13. Park SY, Kim BK, Kim JH et al: Panels of immunohistochemical markers help determine primary sites of metastatic adenocarcinoma. *Arch Pathol Lab Med*, 2007; 131: 1561–67

immunohistochemistry in arriving at the correct diagnosis and in assisting surgeons and oncologists in guiding the care, management, and appropriate therapeutic decisions regarding patients. In patients with a history of CRC, immunohistochemistry is required to arrive at the correct diagnosis as treatment options can be very different. The lesion in our patient was metastatic CRC with KRAS mutation, and the patient was treated with immunotherapy and a stent; whereas if the lesion had been a primary tumor, the only treatment possible today would have been a complicated and extensive surgery. The patient's lesion was stable at seven months follow-up, and for the time being at least, surgery has been avoided. However, surgery might be considered beneficial in the future.

## Statement

The authors have no financial conflicts of interests to disclose and have not received any grants toward this work.