

# Report of a case of papillary thyroid carcinoma in association with Hashimoto's thyroiditis

Chukwudi Onyeaghana Okani, Benjamin Otene<sup>1</sup>, Terhembra Nyaga<sup>1</sup>, Joseph Ngbea<sup>1</sup>, Agaba Eke<sup>2</sup>, Felix Edegbe<sup>3</sup>, Daniel Anyiam<sup>4</sup>

Department of Histopathology, Chukwuemeka Odumegwu Ojukwu University, Awka Campus, <sup>4</sup>Department of Histopathology, Nnamdi Azikiwe University Teaching Hospital, Nnewi, Anambra State, Departments of <sup>1</sup>Histopathology and <sup>2</sup>Surgery, Benue State University Teaching Hospital, Makurdi, Benue State, <sup>3</sup>Department of Histopathology, Federal Teaching Hospital, Abakaliki, Ebonyi State, Nigeria

## ABSTRACT

Hashimoto thyroiditis (HT) is an autoimmune disease, known to be the most common cause of hypothyroidism in nonendemic goitrous areas. It is usually characterized by symmetric, painless, and diffused but sometimes localized swelling of the thyroid gland with features of hypothyroidism. Papillary thyroid carcinoma (PTC), on the other hand, is the most common yet less aggressive form of thyroid cancer, especially in iodine-deficient areas. The coexistence of the two diseases is possible but not common. This case study reports a 50-year-old female with a 10-year history of a huge goiter, which was essentially symptom-free until about 3 months prior to presentation when the patient started complaining of neck pain, dysphagia, productive cough, and cold intolerance. Physical examination revealed focal cystic and tender area in the multinodular swelling and associated cervical lymphadenopathy on the left side of the neck. The serum thyroid stimulating hormone was high, sub-normal T<sub>3</sub>, and the T<sub>4</sub> was low. The fine needle aspiration cytology yielded 10 ml of aspirate of pus admixed with altered blood which on microscopy showed a few suspicious follicular epithelial cells with open nuclei admixed with mainly neutrophil polymorphs, siderophages, and foam cells in a hemorrhagic background. The patient had an incision biopsy that showed areas displaying PTC and HT.

**Key words:** Hashimoto thyroiditis, histopathology, Hurthle cell, papillary thyroid carcinoma

### Address for correspondence:

Dr. Chukwudi Onyeaghana Okani,  
Department of Histopathology,  
Chukwuemeka Odumegwu Ojukwu  
University, Awka Campus,  
Anambra State, Nigeria.  
E-mail: chudiokani@gmail.com

## INTRODUCTION

The name Hashimoto thyroiditis (HT) was derived from the 1912 report by Hashimoto describing patients with goiter and intense lymphocytic infiltration of the thyroid (struma lymphomatosa).<sup>1</sup> HT is known to be the most common cause of hypothyroidism in iodine-deficient areas of the world.<sup>2</sup> Papillary carcinomas are also the most common form of thyroid cancer, and majority of them are associated with previous exposure to ionizing radiation. The association of papillary thyroid carcinoma (PTC) and HT has been a subject of debate, since it was first described by Dailey *et al.* in 1955.<sup>3-5</sup> Lee *et al.*, Cipolla *et al.*, Liu *et al.*, Pino Rivero *et al.*, and Singh *et al.* in their various studies

concluded that there was an association between HT and PTC.<sup>6-9</sup> We found on a microscopic examination of a thyroid biopsy from 50-year-old female, foci showing HT, PTC, and Hurthle cell hyperplasia; and it is hereby being reported.

## PATIENTS AND OBSERVATION

The patient was a 50-year-old woman who initially presented to the Surgery Department of Benue State University Makurdi with a 10-year history of goiter. The swelling increased gradually in size and appeared multinodular in contour, approximating 10 cm × 8 cm [Figure 1] and

This is an open access article distributed under the terms of the Creative Commons Attribution-NonCommercial-ShareAlike 3.0 License, which allows others to remix, tweak, and build upon the work non-commercially, as long as the author is credited and the new creations are licensed under the identical terms.

**For reprints contact:** reprints@medknow.com

**How to cite this article:** Okani CO, Otene B, Nyaga T, Ngbea J, Eke A, Edegbe F, *et al.* Report of a case of papillary thyroid carcinoma in association with Hashimoto's thyroiditis. Niger Med J 2015;56:433-5.

### Access this article online

#### Quick Response Code:



#### Website:

www.nigeriamedj.com

#### DOI:

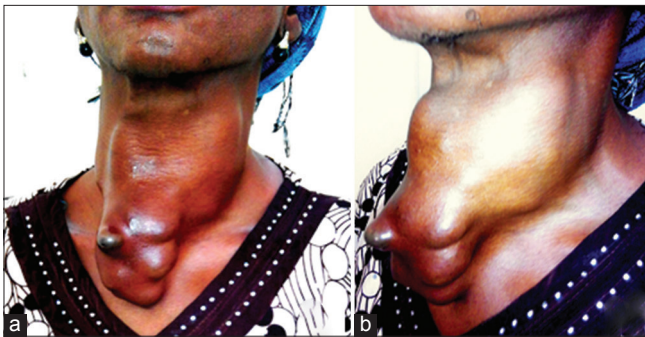10.4103/0300-1652.171612

was all the while painless until about 3 months prior to presentation to the Surgical Outpatient Unit of the Hospital with pain and tenderness, and mild difficulty in swallowing. The pain was described as dull which gradually increased in intensity necessitating her decision to seek medical intervention. She also complained of intolerance to cold and easy fatigability. The serum thyroid-stimulating hormone (TSH) was high –40.5  $\mu$ IU (normal reference range of 0.4–6.2  $\mu$ IU), and the T4 was low- <50 nmol/L while T3 was subnormal. The full blood count revealed mild microcytic hypochromic anemia with normal differential counts. Urea and creatinine were within the normal reference range. The erythrocyte sedimentation rate was mildly elevated–35 mm/h (Westergren method). The fine needle aspiration cytology done yielded about 10 ml of aspirate of pus admixed with altered blood, and the microscopic examination of the smears showed a few suspicious follicular epithelial cells with open nuclei, and pseudocyttoplasmic nuclear inclusions in a background containing mainly neutrophil polymorphs, lymphocytes, foam cells, and hemosiderin-laden macrophages. The patient had an incision

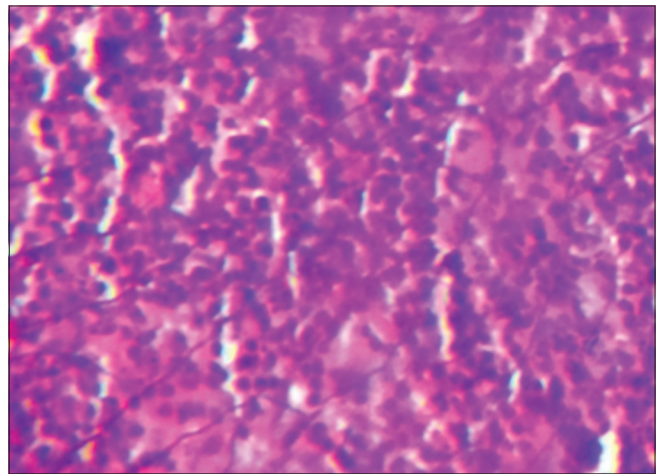
biopsy which on microscopic examination showed areas with PTC, HT, and Hurthle cell metaplastic changes [Figures 2-4].

## DISCUSSION

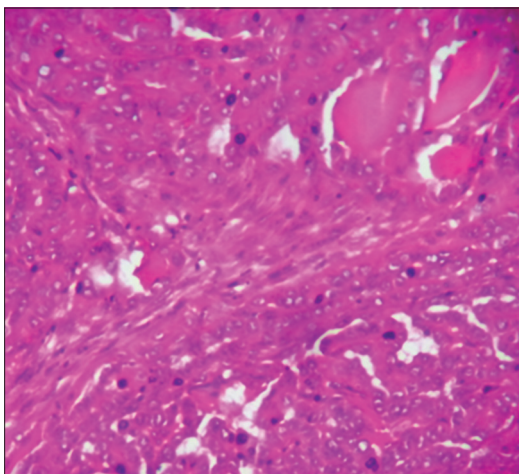
In a research by Replinger *et al.* that sought to answer a question, “Is Hashimoto’s thyroiditis a risk factor for papillary thyroid cancer?” They discovered that a subgroup of patients with HT had strong associations with PTC.<sup>2</sup> They also documented that there was a significantly greater percentage of PTC occurrence in females with HT as compared with females without HT.<sup>2</sup> Gasbarri *et al.* in a study showed that the diagnosis of HT was a representation of a variety of disease mechanisms which influenced the clinical presentation of the disease including PTC.<sup>10</sup> It is possible to extrapolate that certain factors influence varying thyroid growth including goiters or carcinomas. This index case certainly substantiates the causative relationship



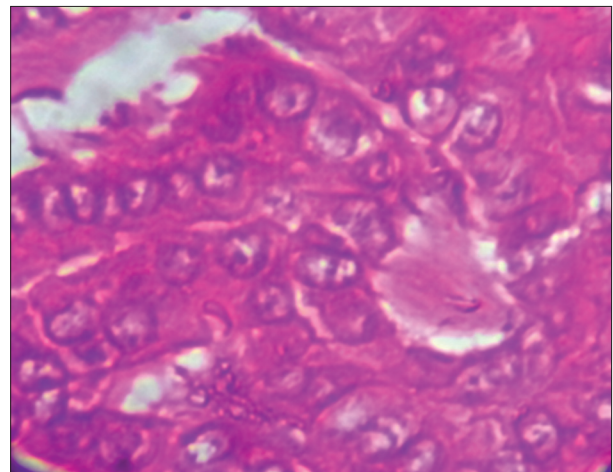
**Figure 1:** Multinodular goiter in a 50-year-old woman diagnosed with concurrent Hashimoto thyroiditis, papillary thyroid carcinoma, and Hurthle cell adenoma. (a) Anterior view of goiter with focal cystic areas filled with pus. (b) The lateral view of the goiter showing extension of the swelling into the posterior aspect of the neck



**Figure 2:** Hashimoto thyroiditis. Residual thyroid follicle being destroyed by a dense lymphocytic infiltrates



**Figure 3:** The microscopic appearance of a papillary carcinoma showing well-formed papillae and cells with ground glass nuclei



**Figure 4:** Papillary carcinoma of the thyroid. The microscopic appearance of a papillary carcinoma showing cells with characteristic empty-appearing nuclei called “Orphan Annie eye” nuclei

between HT and PTC. Some authors have proposed mechanisms and associations between the two lesions. Expression of the RET/PTC1 and RET/PTC3 oncogenes in HT patients was documented by Wirtschafter *et al.*<sup>11</sup> as a major association, and this hypothesis was supported by Arif *et al.* who demonstrated that both diseases have a similar immunophenotypic expression, histological features, and the RET/PTC gene rearrangement on molecular studies.<sup>12</sup> Moreover, Unger *et al.* documented p63 expression in a patient with HT, who also had concurrent papillary thyroid cancer.<sup>13</sup> This hypothesis was further substantiated by Burstein *et al.* in their work where they made some propositions that the initiator of the two diseases was pluripotent p63-positive stem cell remnants.<sup>14</sup> The intimate relationship between HT and PTC in this report goes further to substantiate the proposals made by these researchers that the two diseases may most probably have similar or common triggering factors. Another angle to this discuss is whether serum thyroid TSH has a causal role in the subsequent development of PTC in preexisting HT. Boelaert *et al.* documented that serum TSH is an independent predictor of malignancy in thyroid nodules,<sup>15</sup> and Haymart *et al.* further showed that higher serum TSH in thyroid correlated with extrathyroidal extension of disease.<sup>16</sup> Jonklaas *et al.* in their work concluded that higher TSH concentrations, even within the normal range, are associated with a subsequent diagnosis of thyroid cancer in individuals with thyroid abnormalities.<sup>17</sup> The hypothesis that TSH stimulates the growth or development of thyroid malignancy during its early or preclinical phase was further supported by their work. Jonklaas *et al.* also demonstrated that patients with thyroid cancer also have lower T3 levels than patients with benign disease.<sup>17</sup> This finding is in keeping with the clinical profile of this index case. It is interesting to conclude by joining Boelaert with the consensus opinion that serum TSH concentration can be used as a diagnostic adjunct in the identification of high-risk patients, who may require further investigation and/or surgical interventions.<sup>18</sup>

## CONCLUSION

A high index of suspicion is required for establishing the coexistence of Hashimoto's thyroiditis with PTC; therefore, clinicians must thoroughly evaluate patients with Hashimoto's thyroiditis while pathologists have to always do a thorough job by painstakingly doing a macroscopic and microscopic examination of thyroid specimens more especially, ones with suspected or confirmed Hashimoto's thyroiditis.

## Financial support and sponsorship

Nil.

## Conflicts of interest

There are no conflicts of interest.

## REFERENCES

1. Hashimoto H. Zur Kenntnis der lymphomatösen Veränderung der Schilddrüse (Struma lymphomatosa). *Archiv für klinische Chirurgie*, Berlin 1912;97:S219-48.
2. Repplinger D, Bargren A, Zhang YW, Adler JT, Haymart M, Chen H. Is Hashimoto's thyroiditis a risk factor for papillary thyroid cancer? *J Surg Res* 2008;150:49-52.
3. Dailey ME, Lindsay S, Skahan R. Relation of thyroid neoplasms to Hashimoto disease of the thyroid gland. *AMA Arch Surg* 1955;70:291-7.
4. Jankovic B, Le KT, Hershman JM. Clinical review: Hashimoto's thyroiditis and papillary thyroid carcinoma: Is there a correlation? *J Clin Endocrinol Metab* 2013;98:474-82.
5. Lee JH, Kim Y, Choi JW, Kim YS. High prevalence of suspicious cytology in thyroid nodules associated with positive thyroid autoantibodies. *Eur J Endocrinol* 2005;153:637.
6. Cipolla C, Sandonato L, Graceffa G, Fricano S, Torcivia A, Vieni S, *et al.* Hashimoto thyroiditis coexistent with papillary thyroid carcinoma. *Am Surg* 2005;71:874-8.
7. Liu LH, Bakhos R, Wojcik EM. Concomitant papillary thyroid carcinoma and Hashimoto's thyroiditis. *Semin Diagn Pathol* 2001;18:99-103.
8. Pino Rivero V, Guerra Camacho M, Marcos García M, Trinidad Ruiz G, Pardo Romero G, González Palomino A, *et al.* The incidence of thyroid carcinoma in Hashimoto's thyroiditis. Our experience and literature review. *An Otorrinolaringol Ibero Am* 2004;31:223-30.
9. Singh B, Shaha AR, Trivedi H, Carew JF, Poluri A, Shah JP. Coexistent Hashimoto's thyroiditis with papillary thyroid carcinoma: Impact on presentation, management, and outcome. *Surgery* 1999;126:1070-6.
10. Gasbarri A, Sciacchitano S, Marasco A, Papotti M, Di Napoli A, Marzullo A, *et al.* Detection and molecular characterisation of thyroid cancer precursor lesions in a specific subset of Hashimoto's thyroiditis. *Br J Cancer* 2004;91:1096-104.
11. Wirtschafter A, Schmidt R, Rosen D, Kundu N, Santoro M, Fusco A, *et al.* Expression of the RET/PTC fusion gene as a marker for papillary carcinoma in Hashimoto's thyroiditis. *Laryngoscope* 1997;107:95-100.
12. Arif S, Blanes A, Diaz-Cano SJ. Hashimoto's thyroiditis shares features with early papillary thyroid carcinoma. *Histopathology* 2002;41:357-62.
13. Unger P, Ewart M, Wang BY, Gan L, Kohtz DS, Burstein DE. Expression of p63 in papillary thyroid carcinoma and in Hashimoto's thyroiditis: A pathobiologic link? *Hum Pathol* 2003;34:764-9.
14. Burstein DE, Nagi C, Wang BY, Unger P. Immunohistochemical detection of p53 homolog p63 in solid cell nests, papillary thyroid carcinoma, and hashimoto's thyroiditis: A stem cell hypothesis of papillary carcinoma oncogenesis. *Hum Pathol* 2004;35:465-73.
15. Boelaert K, Horacek J, Holder RL, Watkinson JC, Sheppard MC, Franklyn JA. Serum thyrotropin concentration as a novel predictor of malignancy in thyroid nodules investigated by fine-needle aspiration. *J Clin Endocrinol Metab* 2006;91:4295-301.
16. Haymart MR, Glinberg SL, Liu J, Sippel RS, Jaume JC, Chen H. Higher serum TSH in thyroid cancer patients occurs independent of age and correlates with extrathyroidal extension. *Clin Endocrinol (Oxf)* 2009;71:434-9.
17. Jonklaas J, Nsouli-Maktabi H, Soldin SJ. Endogenous thyrotropin and triiodothyronine concentrations in individuals with thyroid cancer. *Thyroid* 2008;18:943-52.
18. Boelaert K. The association between serum TSH concentration and thyroid cancer. *Endocr Relat Cancer* 2009;16:1065-72.