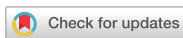

Case Report  
Theriogenology



# Male pseudohermaphroditism with os clitoris in three dogs

Keon Kim <sup>1</sup>, Sang-ho Lee<sup>2</sup>, Chang-ho Son<sup>2</sup>, Sang-ik Park <sup>3,\*</sup>, Chang-min Lee <sup>1,\*</sup>

<sup>1</sup>Department of Veterinary Laboratory Medicine, College of Veterinary Medicine, Chonnam National University, Gwangju 61186, Korea

<sup>2</sup>Department of Veterinary Obstetrics, College of Veterinary Medicine, Chonnam National University, Gwangju 61186, Korea

<sup>3</sup>Department of Veterinary Pathology, College of Veterinary Medicine, Chonnam National University, Gwangju 61187, Korea

 OPEN ACCESS

Received: Jul 9, 2019

Revised: Aug 20, 2019

Accepted: Aug 20, 2019

\*Corresponding author:

Chang-min Lee

Department of Veterinary Laboratory Medicine, College of Veterinary Medicine, Chonnam National University, 77 Yongbong-ro, Buk-gu, Gwangju 61186, Korea.  
E-mail: cmlee1122@jnu.ac.kr

Sang-ik Park

Department of Veterinary Pathology, College of Veterinary Medicine, Chonnam National University, 77 Yongbong-ro, Buk-gu, Gwangju 61187, Korea.  
E-mail: sipark@jnu.ac.kr


© 2019 The Korean Society of Veterinary Science

This is an Open Access article distributed under the terms of the Creative Commons Attribution Non-Commercial License (<https://creativecommons.org/licenses/by-nc/4.0>) which permits unrestricted non-commercial use, distribution, and reproduction in any medium, provided the original work is properly cited.


ORCID iDs

Keon Kim 

<https://orcid.org/0000-0002-8759-7764>

Sang-ik Park 

<https://orcid.org/0000-0003-1709-0324>

Chang-min Lee 

<https://orcid.org/0000-0002-7867-1053>

## ABSTRACT

Two American Cocker Spaniels and one Bichon Frise were presented to our veterinary teaching hospital with an enlarged clitoris. Diagnostic imaging showed that the structure was composed of bony material. Exploratory laparotomy revealed uterine-like structures and testes which had an epididymis unilaterally. Surgical removal of internal genitalia, gonads and protruded clitoris were performed well. Histological evaluation revealed; inactive testes, female internal genital tracts with ambisexual ductal remnants, and prominent ossification in the clitoris. All 3 cases were diagnosed with male pseudohermaphroditism. In author's knowledge, this is the first report in Bichon Frise dog with os clitoris and also, it describes not common cases in small dog breeds with os clitoris.

**Keywords:** American Cocker Spaniel; Bichon Frise; male pseudohermaphroditism; os clitoris; persistent Müllerian duct

Mammals have 3 types of sex: chromosomal, gonadal, and phenotypic sex. Normal sexual development progresses in sequential steps. Sex development is processed through a series of steps under genetic and hormonal control. Abnormal differentiation of the gonads and/or internal and external genitalia often cause disorders of sexual development (DSD) [1,2]. Animals with DSD are classified as disorders of chromosomal, gonadal or phenotypic sex. For instance, true hermaphroditism is known as one of the “disorders of chromosomal sex,” which don't have either XY or XX chromosome. “Disorders of gonadal sex” have normal sex chromosome, but the gonadal sex does not correspond with the chromosomal sex (“sex-reversed”) [3,4]. Pseudohermaphroditism is a disorder of “phenotypic sex development” with only one type of gonadal tissue, either ovaries or testes, but the opposite phenotype [5]. Male pseudohermaphroditism (MPH) is a DSD where both gonads are testes, but the internal genital tract or external genitalia are incompletely masculinized [6]. Phenotypic masculinization is regulated by hormones from embryonic testes [7]. Abnormalities associated with these hormones can lead to MPH by affecting the Müllerian and Wolffian ducts at the embryonic stage. Clitoral abnormalities in dogs are typically related to DSD [5]. Limited reports of DSD with os clitoris have been reported, including MPH in large [8] or mixed breeds [9], or FPH [10]. Here, to our knowledge, we report for the first time case of

**Funding**

This work was supported by the National Research Foundation of Korea (NRF) grant funded by the Korea government (MSIT) (No. 2019060984).

**Conflict of Interest**

The authors declare no conflicts of interest.

**Author Contributions**

Conceptualization: Kim K, Lee SH, Lee CM. Data curation: Lee SH, Son CH. Formal analysis: Lee SH, Son CH, Park SI. Funding acquisition: Kim K, Lee CM. Project administration: Kim K, Park SI, Lee CM. Resources: Lee SH, Son CH, Park SI. Supervision: Son CH, Park SI, Lee CM. Validation: Kim K, Lee SH, Son CH. Visualization: Kim K, Lee SH, Son CH. Writing - original draft: Kim K, Park SI, Lee CM. Writing - review & editing: Kim K, Lee SH, Son CH, Park SI, Lee CM.

**Table 1.** Signalment and characteristics of the 3 cases on physical examination

Characteristics	Case 1	Case 2	Case 3
Breeds	American Cocker Spaniel	American Cocker Spaniel	Bichon Frise
Age (mo)	7	5	5
Weight (kg)	9.9	5.8	3.9
Gross appearance	Enlarged clitoris protruding from the vulva		
Palpation	Hard bony material palpated in the clitoris		
Discharge	Exudate with pus	No exudate	No exudate

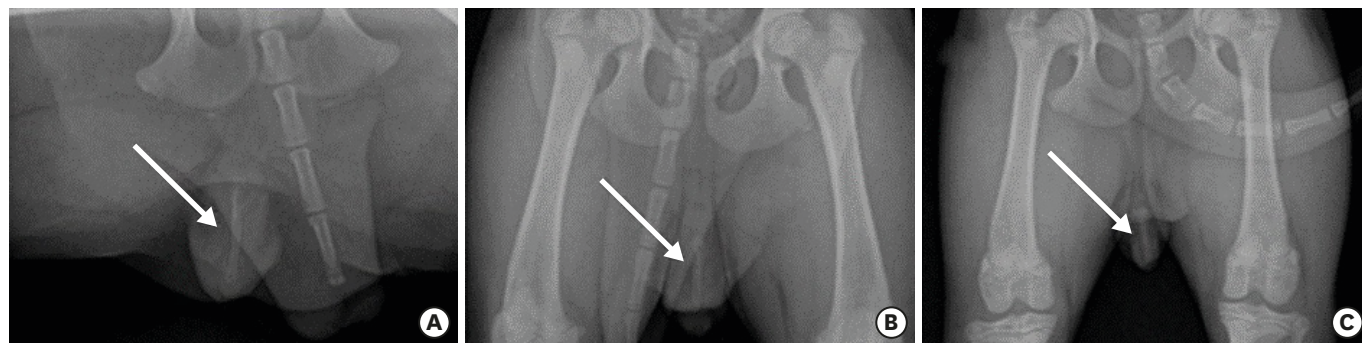
Legend of Figures

MPH accompanied by os clitoris in Bichon Frise and describe 2 case of MPH with os clitoris in small dog breed (American Cocker Spaniel).

Two American Cocker Spaniel dogs and one Bichon Frise dog were referred to the veterinary teaching hospital with a history of vulvar licking. All dogs were 5–7 months old, and weighed less than 10 kg. On physical examination, inspection of the external genitalia revealed the presence of an enlarged clitoris projecting out from the vulva in all 3 cases with vulvar exudates in cases 1 and 2. Palpation of the vulva revealed a hard bony material in the clitoris in all cases. A fissure was present dorsally above the clitoris in case 1. Urethral opening was not observed in cases 2 and 3 during the inspection of the vagina with a colposcope. All patient information obtained at presentation is summarized in **Table 1**.

When a bony structure is detected in ambiguous external genitalia during palpation, diagnostic imaging techniques can help diagnose MPH. In one study, the presence of os clitoris could be apparently made on radiographic evaluation only, when any information of the gonadal tissue was not provided [11]. To date, there have been no reports that have conclusively proved the presence of os clitoris with MPH on radiographic evaluation. Considering these points, we conducted a thorough examination not only by radiography but also ultrasonographic examination. Radiographic imaging showed bone density in the enlarged clitoris in all 3 cases (**Fig. 1**). On abdominal ultrasonography, the uterine structure was evident in case 3, but ambiguous in cases 1 and 2. Case 1 had an incomplete uterine structure without uterine horn while case 2 did not present the overall uterine structure during evaluation. Hypochoic oval-shape structures were detected around the bladder area in all cases.

Blood samples were collected into ethylenediaminetetraacetic acid and heparin containing tubes for screening tests, such as complete blood cell count and serum biochemistry analysis.



**Fig. 1.** Radiographic findings of clitoris in 3 cases. Plain radiography revealed a clearly identifiable structure with obvious bone density (arrows) in the enlarged clitoris of all 3 cases. All images were obtained by positioning in the dorsal recumbent position in (A) case 1, (B) case 2, and (C) case 3.

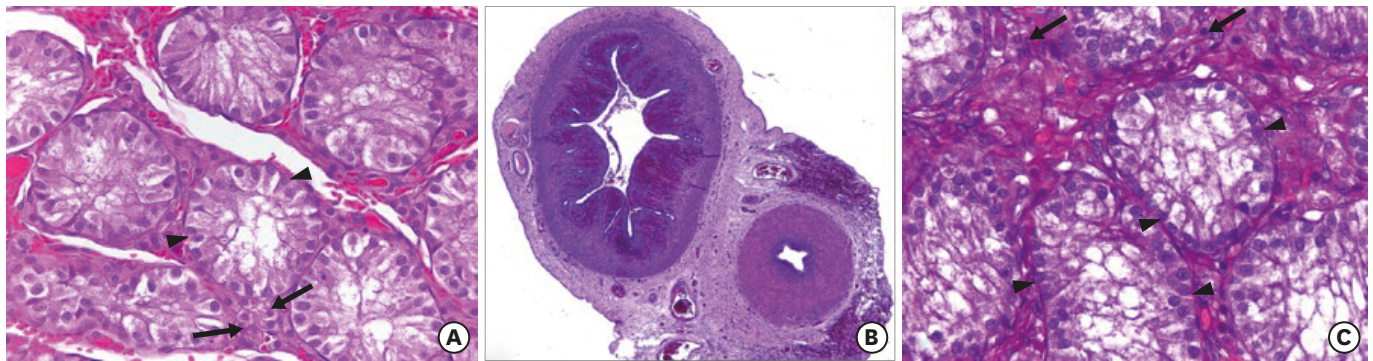All screening hematological examination results acquired from the 3 cases were within the normal reference ranges.

Laparotomy under general anesthesia was performed for surgical removal of the gonads, internal genitalia and os clitoris. The dogs were positioned in a dorsal recumbent position and the surgical regions were clipped and prepared aseptically. Before laparotomy, 0.9% normal saline was administered and maintained throughout the surgery. Prophylactic antibiotics: cefazolin (Cefazolin Inj; Chong Keun Dang, Korea) 22 mg/kg intravenously was administered. After premedication with glycopyrrolate (SEDAJECT; Samu Median, Korea) 0.005 mg/kg subcutaneous in cases 2 and 3, anesthetic induction was performed by injecting tiletamine and zolazepam (Zoletil; Virbac Animal Health, France) 0.05 mg/kg intramuscular with xylazine (Rompun; Bayer Korea Ltd, Korea) 1 mg/kg intramuscular. Anesthesia was maintained with isoflurane (Ifran; Hana Pharm, Korea) and oxygen was delivered through an endotracheal tube. During the laparotomy, dissection of the gonads and the tubular structure connected with them was performed in the dorsal recumbent position. Subsequently, episiotomy was conducted after repositioning the dog in the ventral recumbent position. Postoperatively, 7.5% povidone-iodine ointment was applied on the external genitalia along with injection of tramadol (Toranzin; Samsung Pharmaceutical, Korea) 4 mg/kg subcutaneous. After recovery, the dogs were discharged with a prescription for amoxicillin clavulanic acid (Amocra; Kuhnil, Korea) 12.5 mg/kg by mouth, prednisone (Solondo; Yuhan, Korea) 0.5 mg/kg by mouth and liver protectants twice a day for 7 days by mouth.

During the laparotomy, abdominal exploration for diagnosis was carried out simultaneously. The gonads of both sides were located around the bladder and notably, their gonads looked like testicles with intact epididymis on the left in all cases. Complete female internal genitalia were revealed, including uterine horns, body, and cervix; however, their structure was ambiguous. Two structures which were attached to the gonadal structures could be found lateral to the uterine horns. Ligamental structures similar to testis gubernaculum were also confirmed in cases 2 and 3. Although limited to only individual cases, there were some remarkable structures including vessels analogous to the middle uterine artery in case 2 and pampiniform plexus in case 3. After the laparotomy, episiotomy was performed and the os clitoris could be obtained.

Histologic examination of gonads revealed the evident presence of testes which mainly consisted of testis with fully developed epididymis in all cases (**Fig. 2**). The testis was composed of inactive seminiferous tubules. The epididymal ducts were lined by pseudostratified columnar epithelium. In addition, the bony structure in the clitoral part was also examined histologically. The bone material stained homogeneously and included osteocytes, but there was no trace of osteoclasts or hematopoietic cells, despite a form of primitive bone marrow formation. Specially, in case 2, histopathologic evaluation of the uterine-like structure revealed both remnants of Wolffian and Müllerian ducts (**Fig. 2**).

At postoperative follow-up, the owners reported resolution of associated clinical signs in all 3 dogs, such as licking or vulvar exudates. Along with good compliance of medication, no surgical complications had been reported for any dog at the time of writing this paper. Unfortunately, the karyotype analysis through polymerase chain reaction was not performed, due to cost burden of owners. If the analysis was performed, the mechanism of karyotype can be explained in these cases.



**Fig. 2.** Histological result of gonads and reproductive tracts in 3 cases. The testicles were composed of seminiferous ducts which were lined by only spermatogonia (arrows heads) and interstitial cells (arrows) in case 1 (A) and case 3 (C). There was not any evidence of spermatogenesis. Uterine-like structure with remnants of both the mesonephric duct and the paramesonephric duct was found exclusively in case 2 (B).

Persistent Müllerian duct syndrome (PMDS), a rare type of MPH, is a known autosomal recessive inherited abnormality in the Miniature Schnauzer. This term is used for male dogs presenting with testes with female internal genitalia like oviduct, uterus, and cranial vagina, in which the Müllerian duct has failed to regress [12]. The regression of the Müllerian duct is controlled by Müllerian-inhibiting factor (MIF), which is secreted by Sertoli cells in the testes [13]. In this study, ambiguous female genital tract was found in all 3 cases. The presence of this structure can be attributable to the defect of regression of the Müllerian ducts due to a partial deficiency of MIF, caused by functionally inactive testes. In addition to the rarity of PMDS and none of the present dogs being a Miniature Schnauzer, very unique structures of the uterus were revealed in case 2: in the surrounding area of the uterine tube, remnants of both, the Müllerian and Wolffian, ducts were found histologically.

All our MPH cases presented with an os clitoris. According to a case report on clitoral hypertrophy, formation of the os clitoris was induced by the effects of methyltestosterone [14]. This means androgenic hormones, whether inherent or acquired, could affect osteogenesis in the clitoris. MPH with os clitoris could occur due to partial, but sufficient secretion of androgens in the fetus. Androgen hormone levels should not be too high to lead to MPH and simultaneously not be too low, in order to form a bony structure in the clitoris. In this regard, the concurrence of MPH and os clitoris could be very rare. In fact, only limited cases of MPH with os clitoris have been reported in dogs [8,9].

Few studies regarding the correlation of MPH with specific dog breeds are extant. Only Miniature Schnauzers have been reported to inherit MPH as an autosomal recessive trait [2]. In this report, American Cocker Spaniels and Bichon Frise presented with MPH. Some previous reports of MPH in American Cocker Spaniels have been published; however, none has described the presence of os clitoris [15]. Moreover, this is the first paper reporting of a Bichon Frise with MPH. These cases are even rarer with respect to PMDS. Especially, coexistence of Wolffian and Müllerian ducts in case 2 as reproductive structures associated with MPH has never reported before.

## REFERENCES

1. Jang SJ, Kim YJ, Kim G, Choi SH. Male pseudohermaphroditism in a Maltese/poodle mixed dog. *J Biomed Res* 2014;15:36-39.

**CROSSREF**



2. Sumner SM, Grimes JA, Wallace ML, Schmiedt CW. Os clitoris in dogs: 17 cases (2009–2017). *Can Vet J* 2018;59:606-610.  
[PUBMED](#)
3. Lyle SK. Disorders of sexual development in the dog and cat. *Theriogenology* 2007;68:338-343.  
[PUBMED](#) | [CROSSREF](#)
4. Kang HG, Kim IH, Kim HJ, Hwang DY, Jee SW, Noh GJ. A female hermaphrodite American cocker spaniel dog with Sry-negative XX sex reversal. *J Embryo Transf* 2008;23:119-125.
5. Poth T, Breuer W, Walter B, Hecht W, Hermanns W. Disorders of sex development in the dog-Adoption of a new nomenclature and reclassification of reported cases. *Anim Reprod Sci* 2010;121:197-207.  
[PUBMED](#) | [CROSSREF](#)
6. Weng Q, Murase T, Asano M, Tsubota T. Male Pseudohermaphroditism in a raccoon dog (*Nyctereutes procyonoides*). *J Vet Med Sci* 2005;67:603-605.  
[PUBMED](#) | [CROSSREF](#)
7. Meyers-Wallen VN. Inherited disorders in sexual development. *J Hered* 1999;90:93-95.  
[PUBMED](#) | [CROSSREF](#)
8. Wernham BG, Jerram RM. Male pseudohermaphroditism in a Labrador Retriever, and a review of mammalian sexual differentiation. *N Z Vet J* 2006;54:248-252.  
[PUBMED](#) | [CROSSREF](#)
9. Del Amo AN, Luca JD, Zufriategui L, Armocida A, Barbeito CG, Gobello C. Male pseudohermaphroditism in a dog: a case report. *Commun Theriogenology* 2001;1:1-11.
10. Sacks MK, Béraud R. Female pseudo-hermaphroditism with cloacal malformation and related anomalies in a dog. *Can Vet J* 2012;53:1105-1108.  
[PUBMED](#)
11. Kutzler M, Keller G, Smith F. Os clitoridis on radiographs submitted for coxofemoral dysplasia evaluations. *Proc Soc Theriogenol* 2013;362.  
[PUBMED](#)
12. Romagnoli S, Schlafer DH. Disorders of sexual differentiation in puppies and kittens: a diagnostic and clinical approach. *Vet Clin North Am Small Anim Pract* 2006;36:573-606.  
[PUBMED](#) | [CROSSREF](#)
13. Meyers-Wallen VN, Donahoe PK, Ueno S, Manganaro TF, Patterson DF. Müllerian inhibiting substance is present in testes of dogs with persistent müllerian duct syndrome. *Biol Reprod* 1989;41:881-888.  
[PUBMED](#) | [CROSSREF](#)
14. Smeak DD, Turner H. Treatment of clitoral hypertrophy containing an os clitoris and urethra in a young greyhound dog: a detailed surgical description. *Can Vet J* 2014;55:836-840.  
[PUBMED](#)
15. Alam MR, Cho YG, Cho SJ, Lee JI, Lee HB, Tae HJ, Kim IS, Kim NS. Male pseudohermaphroditism in dogs: three case reports. *Vet Med* 2007;52:74-78.  
[CROSSREF](#)