

## CASE REPORT

# Primary coronary artery pseudoaneurysm in a patient with familial hypercholesterolemia

Toshiki Fujiyoshi  | Masaki Kano | Hitoshi Ogino

Department of Cardiovascular Surgery, Tokyo Medical University, Tokyo, Japan

**Correspondence**

Toshiki Fujiyoshi, Department of Cardiovascular Surgery, Tokyo Medical University, 6-7-1 Nishishinjuku, Shinjuku-ku, Tokyo 160-0023, Japan.  
Email: fff.toshiki@gmail.com

**Abstract**

Rare primary coronary artery pseudoaneurysms in a young patient with heterozygous FH was successfully repaired with direct closure of intimal defects with aneurysmorrhaphy.

**KEY WORDS**

coronary artery aneurysm, heterozygous familial hypercholesterolemia, pseudoaneurysm

## 1 | INTRODUCTION

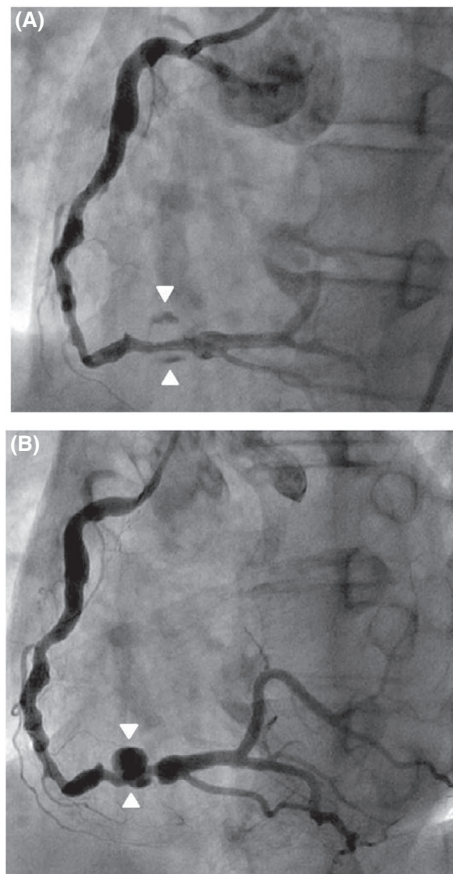
Familial hypercholesterolemia (FH) is one of the risk factors for coronary artery disease (CAD). In homozygous FH, CAD occurs extremely high and younger than heterozygous FH, which are sometimes associated with aneurysmal changes of the coronary artery.<sup>1,2</sup> According to previous reports, although heterozygous FH also developed coronary artery aneurysms (CAAs), those are commonly the fusiform types.<sup>3</sup> Here, we describe a rare case with heterozygous FH complicated with primary coronary artery pseudoaneurysms (CAPAs).

## 2 | CASE

A 48-year-old man with a history of nonmedicated heterozygous FH was referred to our hospital due to sudden onset of chest pain and ventricular fibrillation. Electrocardiogram revealed ST segment elevation on the leads of II, III, and aVF and ST segment depression on the leads of I, aVL, and V2-V5. Echocardiography demonstrated severely impaired motion of the inferior wall of left ventricle. Laboratory blood examination revealed a white blood cell count of 9500/ $\mu$ L, an aspartate aminotransferase level of 58 U/L, a lactate dehydrogenase level of 289 U/L, a creatinine kinase level of 122 mg/dL, a D-dimer level of 0.73  $\mu$ g/mL, a total cholesterol level

of 388 mg/dL, an LDL cholesterol level of 196 mg/dL, and a Troponin-T level of 0.120 ng/mL. These results suggested acute myocardial infarction on the inferior wall of the left ventricle. Emergency coronary angiography (CAG) was performed, which revealed a thrombotic occlusion of the RCA. With a support of intra-aortic balloon pumping, percutaneous coronary intervention (PCI) with aspiration of the fresh thrombus in the RCA, balloon angioplasty, and thrombolytic therapy using urokinase was performed. Subsequently, CAG showed successful recanalization of the RCA with saccular type CAAs (Figure 1A). So, anticoagulant therapy with warfarin and oral hypolipidemic agent with Statin was introduced for CAAs and adverse coronary event. The post-PCI course was good, and the patient was discharged 3 weeks after the PCI.

However, a recent follow-up CAG after 3 years showed 90% stenosis of the proximal and distal sides of the CAA involvements of the RCA (Figure 1B), and 90% stenosis with ectasia of the left anterior descending artery (LAD) and the first diagonal branch (D1). Off-pump coronary artery bypass grafting (OPCAB) to the LAD, D1, and RCA using bilateral internal thoracic arteries and the left radial artery was carried out. After the coronary revascularization, the CAAs of the RCA were exposed. There were two saccular CAAs. The proximal and distal sides of the CAAs were clamped and a larger size CAA was opened. Both of the CAAs were pseudoaneurysms with intimal defects (Figure 2A,B). A small amount of



**FIGURE 1** Coronary angiography images. A, Postangioplasty CAG showed pooling of contrast medium in the CAAs. B, Preoperative CAG showed CAA with stenosis of the proximal and distal sides

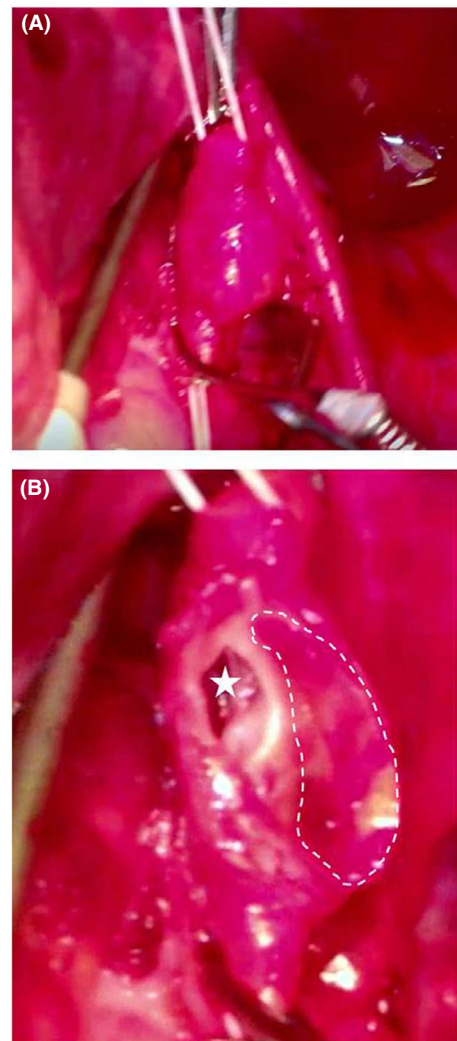
mural thrombi were also found in the both CAAs and removed clearly. So, direct linear closure of the intimal defects of CAAs was carried out, which were followed by aneurysmorrhaphy.

Histopathological findings of the CAAs wall revealed the pseudo-intima and fibrosis fibrotic media with an atherosclerotic change. However, no inflammatory changes were detected.

Postoperative CAG showed patency of the bypass grafts and complete disappearance of CAAs in the RCA. After the surgery, the patient was medicated dual antiplatelet therapy and subcutaneous injection of Evolocumab for an LDL cholesterol value of 100 mg/dL or less.

### 3 | DISCUSSION

Coronary ectasia including CAAs formation is one of the uncommon angiographic findings at an estimated incidence of 0.3%-4.7%.<sup>4,5</sup> The clinical significance of this condition is unclear, and there are some disputes regarding its relationship with occlusive coronary artery disease. In various reports, ectasia has been described either as an isolated congenital lesion or associated with coronary atherosclerosis, syphilis, congenital heart disease, scleroderma, polyarteritis nodosa,



**FIGURE 2** Intra-operative findings. A, CAA on the RCA. B, A larger size CAA was opened. Intimal defect (star sign) was detected. The pseudo-intima (dotted lines) was also detected

Ehlers-Danlos syndrome, bacterial infections, and Kawasaki syndrome.<sup>3</sup> On the other hand, CAPSs are predominantly associated with iatrogenic lesions, particularly in traumatic injury from catheter-based interventions. In the presented case, CAPAs on the RCA was already confirmed in the first PCI. The traumatic nature was negative. Reportedly, in cases with FH, CAAs are associated with revealed circumferential intimal thickening.<sup>3</sup> On the other hand, hypercholesterolemia causes to progress of vascular endothelial dysfunction, that caused foaming of the intima and the fragile intima collapsed with plaque rupture, as is FH.<sup>6</sup> In this case, the plaque rupture led to the formation of a pseudoaneurysm. This is extremely rare of primary CAPS in a patient with heterozygous FH.

The clinical presentation of pseudo-CAAs varies, however, it usually includes angina pectoris and myocardial infarction. Because of potential lethal risks of thrombosis formation, its distal embolization, and rupture, false CAAs should be treated. However, no standard therapies exist. The therapeutic options include placement of covered stents,

embolization with spring coils, and operative resection with bypass.<sup>7,8</sup> In our case, the off-pump repair with direct closure of the intimal defects in the two false CAAs and aneurysmorrhaphy in conjunction with OPCAB was performed.

In conclusion, rare primary false CAAs in a young patient with heterozygous FH was successfully repaired with direct closure of intimal defects with aneurysmorrhaphy.

## CONFLICT OF INTEREST

None declared.

## AUTHOR CONTRIBUTION

TF: wrote this paper. MK: involved in data correction. HO: revised this paper.

## ORCID

Toshiki Fujiyoshi  <https://orcid.org/0000-0002-1118-6643>

## REFERENCES

1. Haitas B, Baker SG, Meyer TE, Joffe BI, Seftel HC. Natural history and cardiac manifestations of homozygous familial hypercholesterolemia. *Q J Med.* 1990;76:731-740.
2. Bujo H, Takahashi K, Saito Y, Maruyama T, Yamashita S. Clinical features of familial hypercholesterolemia in Japan in a database from 1996-1998 by the research committee of the ministry of health, labour and welfare of Japan. *J Atheroscler Thromb.* 2004;11:146-151.
3. Sudhir K, Ports TA, Amidon TM, et al. Increased prevalence of coronary ectasia in heterozygous familial hypercholesterolemia. *Circulation.* 1995;91(5):1375-1380.
4. Oliveros RA, Falsetti HL, Carroll RJ, Heinle RA, Ryan GF. Atherosclerotic coronary artery aneurysm: report of five cases and a review of the literature. *Arch Intern Med.* 1974;134:1072-1076.
5. Swaye PS, Fisher LD, Litwin P, et al. Aneurysmal coronary artery disease. *Circulation.* 1983;67:134-138.
6. Ross R, Faggiotto A, Bowen-Pope D, Raines E. The role of endothelial injury and platelet and macrophage interactions in atherosclerosis. *Circulation.* 1984;70(5 Pt 2):III77-III82.
7. Erol MK, Bozkurt E, Arslan S. Percutaneous sealing of coronary aneurysm by grafted stent implantation. *Heart.* 2004;90:1309.
8. Kereiakes DJ, Long DE, Ivey TD. Coil embolization of a circumflex coronary aneurysm at the time of percutaneous coronary stenting. *Catheter Cardiovasc Interv.* 2006;67:607-610.

**How to cite this article:** Fujiyoshi T, Kano M, Ogino H. Primary coronary artery pseudoaneurysm in a patient with familial hypercholesterolemia. *Clin Case Rep.* 2019;7:1916–1918. <https://doi.org/10.1002/ccr3.2402>