

## Rest/stress intradermal lymphoscintigraphy in diagnosis of lipedema

### ABSTRACT

Lipedema is a chronic and progressive disease characterized by a symmetrical and bilateral swelling of the lower extremities. In general, the feet are not involved. Lipedema is believed to affect nearly 1 in 9 adult women worldwide. Despite this relatively common disease, lipedema is often confused with primary lymphedema or obesity. In clinically advanced lipedema stages, fat continues to build up and may block the lymphatic vessels causing a secondary lymphedema (Lipo-Lymphedema). We consecutively evaluated 54 women with a clinical diagnosis of lower limbs lipedema. Two doses of  $^{99m}\text{Tc}$ -nanocolloid were injected intradermally at the first intermetatarsal space and in the lateral malleolar area. Two static planar scans were taken at rest immediately following the intradermal injection. Subsequently, all patients were asked to perform an isotonic muscular exercise (stepping) for 2 min. Then, post exercise scans were performed to monitor the tracer pathway. Subsequently, the patient was asked to take a 30–40 min walk (prolonged exercise) and delayed scans were acquired. In early clinical stages, the lymphatic flow is usually preserved and the rest/stress intradermal lymphoscintigraphy may visualize a normal lymphatic drainage with a frequent pattern (tortuous course) of the leg lymphatic pathway. In clinically advanced stages, lymph stagnation areas were observed. Unlike obesity, lipedema fat storage is resistant to dietary regimen, bariatric surgery, and physical activity. Surgical treatment (tumescant liposuction and reductive surgery) is the most effective treatment to remove adipose tissue. Complex decongestive therapies are helpful in reducing the lymph stagnation, especially in patients with advanced lipolymphedema.

**Keywords:**  $^{99m}\text{Tc}$ -HSA, intradermal, lipedema, lymphoscintigraphy, stress

### INTRODUCTION

Lipedema was first described by Allen and Hines in 1940.<sup>[1]</sup> It is a chronic and progressive painful disease due to a disproportionate hyperplasia and hypertrophy of adipocytes in the subcutaneous tissue of the lower limbs. The cause and pathogenesis of lipedema are thought to be a genetic disorder with an autosomal dominant inheritance with presentation being limited to the female gender.<sup>[2]</sup> Lipedema is characterized by a symmetrical and bilateral swelling of the lower extremities (sometimes also upper limbs), extending from hips to ankles classically sparing the dorsum of the feet and hands. Lipedema is characterized by a symmetrical and bilateral swelling of the lower extremities (sometimes also upper limbs), extending from hips to ankles classically sparing the dorsum of the feet and hands [Figure 1].

Women with early lipedema report a rapid growth of the subcutaneous adipose tissue frequently activated by puberty,

pregnancy, or menopause. Women in later stages of lipedema have a classic “column leg” appearance, with masses of nodular fat.<sup>[3]</sup> As lipedema worsens, chronic fatty redistribution may

**GIROLAMO TARTAGLIONE, GIUSEPPE VISCONTI<sup>1</sup>,  
ROBERTO BARTOLETTI<sup>2</sup>, FRANCESCO PIO IERIA,  
MARZIA SALGARELLO<sup>1</sup>**

Department of Nuclear Medicine, Cristo Re Hospital, <sup>1</sup>Centre for Surgical Treatment of Lymphedema, Dipartimento Salute della Donna, del Bambino e di Sanità Pubblica, UOC Chirurgia Plastica, Fondazione Policlinico Universitario “Agostino Gemelli” IRCCS, <sup>2</sup>Department of Oncology, Oncological Rehabilitation, IDI IRCCS, Rome, Italy


**Address for correspondence:** Dr. Girolamo Tartaglione, Department of Nuclear Medicine, Cristo Re Hospital, 25 Via Delle Calasanziane, Rome 00167, Italy. E-mail: girtart@gmail.com

**Submitted:** 09-Jan-2020, **Revised:** 04-Mar-2020,  
**Accepted:** 04-Mar-2020, **Published:** 27-Jun-2020

This is an open access journal, and articles are distributed under the terms of the Creative Commons Attribution-NonCommercial-ShareAlike 4.0 License, which allows others to remix, tweak, and build upon the work non-commercially, as long as appropriate credit is given and the new creations are licensed under the identical terms.

**For reprints contact:** WKHLRPMedknow\_reprints@wolterskluwer.com

**How to cite this article:** Tartaglione G, Visconti G, Bartoletti R, Ieria FP, Salgarello M. Rest/stress intradermal lymphoscintigraphy in diagnosis of lipedema. World J Nucl Med 2020;19:376-81.

Access this article online	
<b>Website:</b> www.wjnm.org	<b>Quick Response Code</b> 
<b>DOI:</b> 10.4103/wjnm.WJNM_5_20	

be associated with heaviness, bruising, burning, itching, and pain. In later stages, the disease might progress to secondary lymphedema, known as lipolymphedema.

Lipedema is believed to affect nearly 1 in 9 adult women worldwide.<sup>[4]</sup>

Despite this relatively common disease, there are few physicians who are aware of it. The diagnosis of lipedema is clinical and mainly relies on history and clinical evaluation.<sup>[5]</sup> Lymphatic flow is usually preserved, and lipedema patients usually have normal lymphoscintigrams, in early stages. However, lipedema is underdiagnosed, and often confused with primary lymphedema, obesity, or chronic venous insufficiency.

In our study, we propose rest/stress lymphoscintigraphy in early stage of lipedema to confirm diagnosis, or to evaluate altered lymphatic drainage in clinically advanced stages of lipolymphedema.

## MATERIALS AND METHODS

We consecutively studied 54 women (aged  $46 \pm 19$  years) with a clinical diagnosis of lower limb lipedema.

Tight and elastic clothes were removed before examination. Two doses of  $^{99m}\text{Tc}$ -HSA nanocolloidal, 50–80 MBq in 0.3 mL, were injected intradermally at the first intermetatarsal space and in the lateral malleolar area. This was followed by a soft massage around the injection site. We used a dual-head gamma camera (Infinia-Xeleris GP3; GE Medical System, Milwaukee, WI, USA), equipped with low-energy general-purpose parallel-hole collimators, to increase gamma-camera sensitivity.

The lower limbs were scanned in a supine position reducing the distance between the collimator and limbs to improve resolution. We used following parameters: Preset time 180" to 300", matrix  $128 \times 128$ , 140 keV  $\pm$  10%. Usually, the injection points were positioned outside of the field of view. Two static planar scans taken in anterior and posterior views were acquired at rest immediately following the injection (one for the legs and one for the thighs).

Subsequently, all patients were asked to perform an isotonic muscular exercise (stepping) for 2 min. The exercise is followed by post exercise scans to monitor the tracer pathway.

Subsequently, the patient performed 30–40 min walking exercise.

A series of new limb images including iliac and abdominal area for lower limbs were acquired at 60 min. This technique was used to evaluate the effect of prolonged exercise and visualize the lymph nodes, lymphatic pathways starting from the injection points.<sup>[6,7]</sup>

The time in minutes was evaluated from injection to the appearance of the tracer (tracer appearance time [TAT]) in the inguinal or axillary lymph nodes. Normally, TAT is  $< 10$  min. All scintigraphic images were evaluated qualitatively by two independent observers, and TATs were recorded. In order to quantify the visual scintigraphic findings, a numeric transport index (TI), combining a visual assessment of five criteria (temporal and spatial distribution of the radionuclide, appearance time of lymph nodes, and graded visualization of lymph nodes and vessels) was applied into a modified method as previously described by Kleinhans *et al.*<sup>[8]</sup> In normal cases, TI ranges from 0 to 10. A minimum of 3 points were assigned when the scan at rest showed no flow or delayed flow. Higher values describe a more severe degree of lymphatic disorders.

## RESULTS

We scanned consecutively 54 consecutive women, mean age 47.1 years ( $\pm$  19.3), range 17–86 years.

The mean body mass index (BMI) was 32.3, with a range 21.7–58.5 (normal value: 18.5–24.9). The rest scan showed a normal visualization of lymphatic vessel along the great saphenous vein in 36 out of 108 limbs (33.3%). Stress scan showed a complete visualization of lymphatic pathways from injection sites to inguinal lymph nodes in 100 of 108 limbs (92.5%). A tortuous course of the lymph pathway of the legs, together with some visualization of collateral flow was observed in 75% of legs. The presence of collaterals and/or popliteal node uptake occurred in 53 out of 108 limbs (49.1%). Delayed scan showed tracer stagnation areas in 16 out of 108 limbs (14.8%), dermal backflow in 3 out of 108 limbs (2.8%) (both major sign of a lymphatic disorder). Deep lymphatic vessels and popliteal node uptake, a minor sign of lymphatic disorder, were observed in 39 out of 108 limbs (36%). The TAT in the inguinal lymph node was  $< 10$  min in 100 out of 108 Limbs (92.5%). The mean transport index was 9, with a range 3–16 (normal value  $< 10$ ). Age, height, weight, BMI, and TI for single limb are summarized in Table 1.

## DISCUSSION

Lipedema is frequently misdiagnosed or confused with primary lymphedema, obesity, and chronic venous insufficiency.<sup>[9]</sup> Lipedema almost exclusively appears in women, is symmetric and spares feet, whereas lymphedema is usually asymmetric,

**Table 1: Age, height, weight, body mass index, right lower limb transport index, left lower limb transport index**

Age years	Height	Weight	BMI	TI right	TI left
81	155	90	0.37	3	3
41	168	117	0.41	3	9
35	166	74	0.27	9	3
51	170	70	0.24	11	11
27	165	91	0.33	11	9
19	160	97	0.38	9	9
64	162	140	0.53	3	3
77	162	90	0.34	3	3
49	168	75	0.27	13	13
23	158	100	0.40	8	10
79	160	105	0.41	6	3
26	172	68	0.23	9	6
78	153	115	0.49	9	9
82	180	93	0.29	6	20
54	169	114	0.40	11	13
54	169	81	0.28	14	12
39	160	84	0.33	8	9
67	154	74	0.31	9	10
44	163	70	0.26	9	9
33	165	90	0.33	6	5
20	169	70	0.25	9	6
41	159	92	0.36	10	11
31	176	90	0.29	11	12
54	168	90	0.32	11	9
74	165	105	0.39	6	3
77	160	150	0.59	16	14
35	160	67	0.26	9	3
24	158	64	0.26	11	10
17	170	84	0.29	9	6
42	175	70	0.23	11	7
32	183	90	0.27	9	6
33	159	58	0.23	14	14
54	153	58	0.25	14	10
70	162	94	0.36	15	9
35	172	125	0.42	10	10
33	164	84	0.31	10	10
66	158	80	0.32	11	9
72	160	60	0.23	12	12
49	160	68	0.27	12	9
17	167	77	0.28	10	12
38	150	73	0.32	12	12
23	168	74	0.26	9	13
57	163	124	0.47	10	12
40	165	85	0.31	6	5
51	165	66	0.24	10	9
52	160	67	0.26	11	10
23	169	73	0.26	10	10
39	178	84	0.27	9	8
64	165	77	0.28	9	8
48	165	84	0.31	9	16
37	160	97	0.38	14	15
36	160	138	0.54	10	10

Contd...

**Table 1: Contd...**

Age years	Height	Weight	BMI	TI right	TI left
52	170	63	0.22	13	13
86	163	85	0.32	18	15
47.1	164.4	87.1	0.32	9.8	9.4
19.3	6.78	21.19	0.08	3.1	3.7

BMI: Body mass index; TI: Transport index

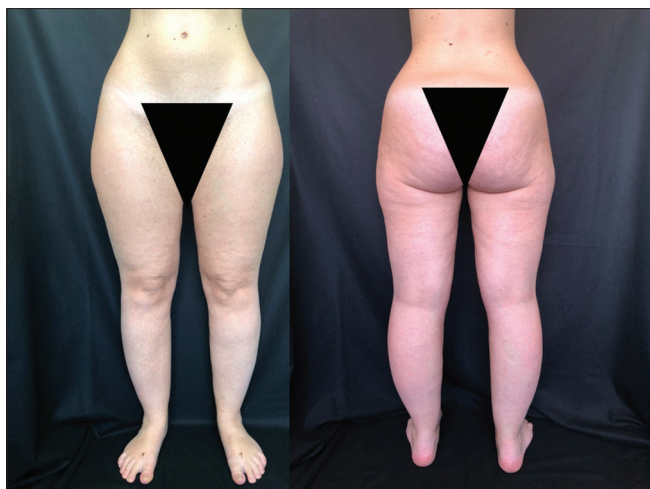swelling may interest the entire limb, including the feet. Lipedema may change minimally with elevation or compression. Lipedema is painful and associated with easy bruising. Obesity is characterized by an increase fat all over the body. Cellulite may cause a disproportionate amount of fat accumulation in the legs but is not associated to pain. Chronic venous insufficiency can cause swelling and pain, however, it is not usually symmetric and commonly presents varicose veins. Nevertheless, lipedema is mostly unknown, therefore resulting in a lack of recognition. A 2012 survey of lipedema patients, conducted by the British Lymphology Society and Lipoedema, UK, found that only 9% of patients were diagnosed with lipedema the first time they reported their symptoms.<sup>[10]</sup>

An online survey questionnaire, conducted on 209 female patients with lipedema who had undergone tumescent liposuction in a single center in Germany, found that most of the patients (mean age, 38.5 years) noticed the first manifestation of the disease at the age of 16 years, followed by a mean of 15 years to reach the diagnosis.<sup>[11]</sup>

Lipedema is related to eating habits. This can be seen in advanced stages of lipedema which are more frequently linked to being overweight and obesity. A patient with unhealthy eating habits may undergo more advanced stages of lipedema. An increased intake of energy-dense foods, high fat content foods, a sedentary lifestyle and genetic susceptibility may result in an associated obesity, that worse the symptoms of lipedema. The prevalence of being overweight and obesity among children and adolescents aged 5–19 years has risen dramatically from 4% in 1975 to over 18% in 2016.<sup>[12]</sup> Recently, in a paper by Faerber resulted that more than 50% of lipedema patients in Germany are also obese. Lipedema and obesity may reinforce each other, this leading an accelerated deterioration of disease.<sup>[13]</sup>

In a recent statistic from Lymphedema Center in Santa Monica, CA concluded that 50% of their patients in the last decade (2010–2019) had lipedema (vs. the 21% in the decade 2000–2009).<sup>[14]</sup>

In the previous studies, the most common method used to perform lymphoscintigraphy of the extremities was

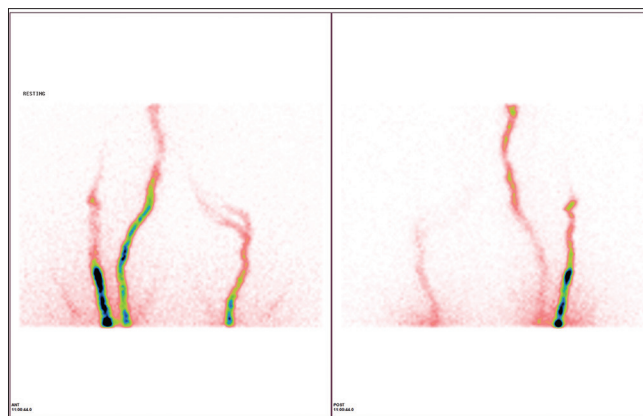


**Figure 1: Lower limbs lipedema in anterior and posterior views. The subcutaneous fat is increased above all in the area of buttocks and hips**

to inject 74–296 MBq of millipore-filtered  $^{99m}\text{Tc}$  sulfur colloid or  $^{99m}\text{Tc}$ -nanocolloids suspended in 0.10 mL of saline subcutaneously into the interdigital web spaces. Previous studies on lipedema patients showed a delayed lymph flow in the absence of major signs of lymphedema. [15-20]

This innovative technique rest/stress intradermal lymphoscintigraphy consists of an intradermal administration of a radiotracer and a different tracer injection site. The intradermal injection allows a better absorption of the tracer by the lymphatic capillary network of the dermis, this allows for a better visualization of lymphatic pathways and regional lymph nodes in shorter time. The tracer injection sites used in this study were the first intermetatarsal space and the lateral malleolar area.

The intradermal rest/stress intradermal lymphoscintigraphy in lipedema patients shows a complete visualization of lymphatic pathways and inguinal lymph nodes after a brief exercise (2 min) in almost all cases. On the contrary to lymphedema patients, we may observe a scarce resistance to the tracer injection by the intradermal way in all lipedema patients. Probably, this depends on a normal pressure in the peripheral lymphatic system. A normal TAT and an early visualization of lymphatic pathways and regional lymph nodes allows for an easy differential diagnosis between lipedema and primary lymphedema. The presence of collateral pathways and/or uptake of popliteal nodes may be considered minor signs of a lymphatic disorder. By injecting radiotracer intradermally, we visualized a tortuous course of the lymph pathway in the legs of 75% of lipedema patients, [Figures 2-4] combined with a normal inguinal node TAT in 92.5% of limbs imaged.



**Figure 2: 66-year-old woman, body mass index = 30.2. Resting scan shows a “tortuous course” of lymphatic pathways of legs, as a typical pattern of lipedema**

In our experience, we observed the same pattern in 10%–15% of patients with primary or secondary lymphedema. A delayed TAT, a higher TI, and the presence of major signs of lymphedema allow for a differential diagnosis of lymphatic disorders.

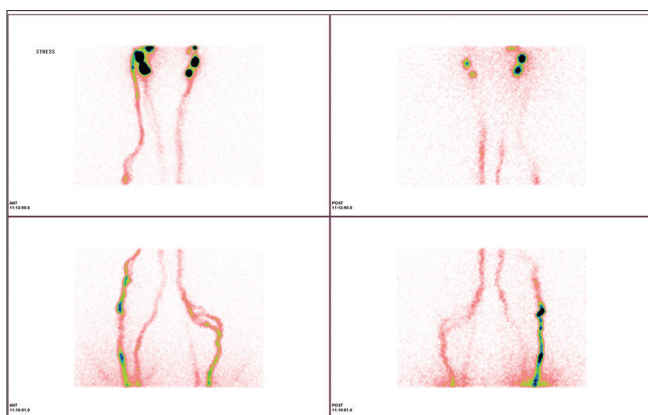
A tortuous course of lymph pathway may also be observed in patients with filarial lymphedema, a pathology endemic in West and Central Africa. The worms responsible for disease progressively occupy the subcutaneous tissue provoking lymphedema in the years after infection. When lymphatic filariasis develops into chronic conditions, it leads to secondary lymphedema. Until very recently, diagnosing lymphatic filariasis had been extremely difficult, since parasites could only be microscopically detected in the blood. The development of a card test to detect high levels of circulating parasite antigens in the blood may clarify diagnosis.<sup>[21]</sup>

Analogous scintigraphic patterns have been observed in patients with Prader–Willi syndrome. This rare genetic syndrome is characterized by excessive eating and gradual development of morbid obesity.<sup>[22]</sup>

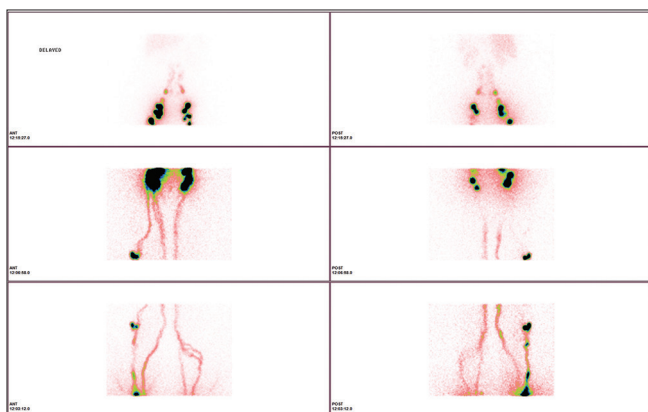
Probably, lymph adapts its course to the increasing presence of subcutaneous fat.

A tortuous lymphatic pathway may be considered a typical pattern of lipedema and of diseases involving subcutaneous tissue [Figures 2-4].

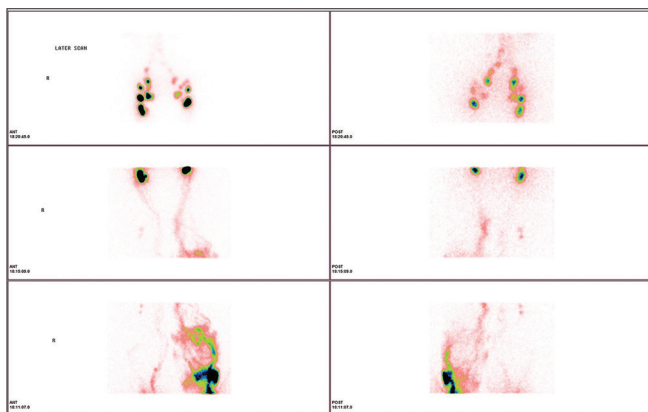
In clinically advanced stages of lipedema, we observed tracer stagnation areas or lymphangiectasia. In this case, the chronic buildup of fat most likely damages the lymph collector determining a secondary lymphedema (lipolymphedema) [Figure 5].



**Figure 3:** (Same patient) Stress scan shows a clear and complete visualization of lymphatic pathways from injection sites on the feet to inguinal lymph nodes (tracer appearance time <10 min). The scan confirms a bilateral tortuous course of lymphatic vessels of legs and the presence of collaterals



**Figure 4:** (Same patient) Delayed scan shows an unusual uptake of the right popliteal node (demonstrating the involvement of deeper lymphatic drainage), and a normal uptake of inguinal, ileal and periaortic lymph nodes



**Figure 5:** 64-year-old woman, body mass index = 0.53. Delayed scan shows a tracer stagnation area at third medium of the left leg in a patient with an advanced clinical stage of lipolymphedema

## CONCLUSION

Rest/stress intradermal lymphoscintigraphy shows a normal lymphatic drainage, a normal uptake of regional lymph node,

absence of lymph stagnation area after muscular exercise and normal TI value, in early and intermediate clinical stages of lipedema. Using our method, we observed a tortuous course of lymphatic pathways in 75% of legs of women with lipedema.

Tracer stagnation areas or dermal backflow, an expression of secondary damage to lymphatic vessels (lipolymphedema) was observed in only few patients with and advanced stage of lipedema.

Distinct from other forms of fatty deposition, diet, or exercise are ineffective as treatment for the fat deposition in lipedema patient. Combined decongestive therapy may reduce symptoms and may be recommended for patients with a demonstrable lymphatic disfunction and is recommended in the all patients to avoid significant weight gain.<sup>[22]</sup>

Surgical treatment of lipedema should be based on the features of each patient. For patients without lymphatic functional impairment, liposculpture of affected areas represent a valid solution in reducing the fat accumulation while shaping the entire leg and ankle. Liposuction nowadays is a safe and well-established procedure.<sup>[23-26]</sup>

Being a blind procedure, liposuction might lead to injures of microvascular structures of the adipose tissue (including lymphatic channels), which are usually not clinically relevant.

However, in the setting of an impaired lymphatic drainage, microvascular injuries lead to a clinically relevant lymphatic impairment, ultimately leading to secondary lymphedema.

As for now, in our center, we are prospectively evaluating lipedema patients undergoing liposculpture according to our surgical inclusive criteria and use of intraoperative Indocyanine Green fluorescence-navigated surgery, to evaluate the liposuction safety for those with an impaired lymphatic function.<sup>[27]</sup>

## Declaration of patient consent

The authors certify that they have obtained all appropriate patient consent forms. In the form the patient(s) has/have given his/her/their consent for his/her/their images and other clinical information to be reported in the journal. The patients understand that their names and initials will not be published and due efforts will be made to conceal their identity, but anonymity cannot be guaranteed.

## Financial support and sponsorship

Nil.

## Conflicts of interest

There are no conflicts of interest.

## REFERENCES

- Allen EV, Hines EA. Lipedema of the legs: A syndrome characterized by fat legs and orthostatic edema. *Staff Meet Mayo Clin* 1940;15:184-7.
- Child AH, Gordon KD, Sharpe P, Brice G, Ostergaard P, Jeffery S, *et al.* Lipedema: An inherited condition. *Am J Med Genet A* 2010;152A:970-6.
- Buck DW 2<sup>nd</sup>, Herbst KL. Lipedema: A relatively common disease with extremely common misconceptions. *Plast Reconstr Surg Glob Open* 2016;4:e1043.
- Földi E, Földi M, Tischendorf F. Adipositas, lipedema and lymphostasis. *Med Welt* 1983;34:198-200.
- Shavit E, Wollina U, Alavi A. Lipoedema is not lymphoedema: A review of current literature. *Int Wound J* 2018;15:921-8.
- Tartaglione G, Pagan M, Morese R, Cappellini GA, Zappalà AR, Sebastiani C, *et al.* Intradermal lymphoscintigraphy at rest and after exercise: A new technique for the functional assessment of the lymphatic system in patients with lymphoedema. *Nucl Med Commun* 2010;31:547-51.
- Tartaglione G, Visconti G, Bartoletti R, Gentileschi S, Salgarello M, Rubello D, *et al.* Stress lymphoscintigraphy for early detection and management of secondary limb lymphedema. *Clin Nucl Med* 2018;43:155-61.
- Kleinhans E, Baumeister RG, Hahn D, Siuda S, Büll U, Moser E. Evaluation of transport kinetics in lymphoscintigraphy: Follow-up study in patients with transplanted lymphatic vessels. *Eur J Nucl Med* 1985;10:349-52.
- Wright T: Introduction to Lipedema. Available from: <https://www.veindirectory.org/magazine/article/education/introduction-to-lipedema>. [Last accessed on 2020 Mar 26].
- Lipoedema UK's Big Survey. Available from: <https://www.lipoedema.co.uk/lipoedema-uks-big-survey/>. [Last accessed on 2020 Mar 26].
- Bauer AT, von Lukowicz D, Lossagk K, Aitzetmueller M, Moog P, Cerny M, *et al.* New Insights on lipedema: The enigmatic disease of the peripheral fat. *Plast Reconstr Surg* 2019;144:1475-84.
- Wollina U. Lipedema: Up-to-date of a long forgotten disease. *Wien Med Wochenschr* 2017;167:343-8.
- World Health Organization. Available from: <https://www.who.int/news-room/fact-sheets/detail/obesity-and-overweight>. [Last accessed on 2020 Mar 26].
- Iker E. From Diagnosis to Lymphedema Management. Available from: <https://lymphaticnetwork.org/news-events/from-diagnosis-to-lymph-edema-management>. [Last accessed on 2020 Mar 26].
- Faerber G. Ernährungstherapie bei Lipödem und Adipositas – Ergebnisse eines leitliniengerechten Therapiekonzepts. *Vasomed* 2017;4:176-77.
- Boursier V, Pecking A, Vignes S. Comparative analysis of lymphoscintigraphy between lipedema and lower limb lymphedema. *J Mal Vasc* 2004;29:257-61.
- Forner-Cordero I, Oliván-Sasot P, Ruiz-Llorca C, Muñoz-Langa J. Lymphoscintigraphic findings in patients with lipedema. *Rev Esp Med Nucl Imagen Mol* 2018;37:341-8.
- Weissleder H, Brauer JW, Schuchhardt C, Herpertz U. Value of functional lymphoscintigraphy and indirect lymphangiography in lipedema syndrome. *Z Lymphol* 1995;19:38-41.
- Kar SK, Dwibedi B, Das BK, Agrawala BK, Ramachandran CP, Horton J. Lymphatic pathology in asymptomatic and symptomatic children with *Wuchereria bancrofti* infection in children from Odisha, India and its reversal with DEC and albendazole treatment. *PLoS Negl Trop Dis* 2017;11:e0005631. Available from: <https://doi.org/10.1371/journal.pntd.0005631>. [Last accessed on 2020 Mar 26].
- Freedman DO, de Almeida Filho PJ, Besh S, Maia e Silva MC, Braga C, Maciel A. Lymphoscintigraphic analysis of lymphatic abnormalities in symptomatic and asymptomatic human filariasis. *J Infect Dis* 1994;170:927-33.
- Subramanyam P, Palaniswamy SS. Lymphoscintigraphy in unilateral lower limb and scrotal lymphedema caused by filariasis. *Am J Trop Med Hyg* 2012;87:963-4.
- Moshiri M, Katz DS, Boris M, Yung E. Using lymphoscintigraphy to evaluate suspected lymphedema of the extremities. *AJR Am J Roentgenol* 2002;178:405-12.
- World Health Organization. Available from: <https://www.who.int/news-room/fact-sheets/detail/lymphatic-filariasis>. [Last accessed on 2020 Feb 12].
- Dadras M, Mallinger PJ, Corterier CC, Theodosiadi S, Ghods M. Liposuction in the treatment of lipedema: A longitudinal study. *Arch Plast Surg* 2017;44:324-31.
- Schmeller W, Hueppe M, Meier-Vollrath I. Tumescant liposuction in lipedema yields good long-term results. *Br J Dermatol* 2012;166:161-8.
- Rapprich S, Dingler A, Podda M. Liposuction is an effective treatment for lipedema-results of a study with 25 patients. *J Dtsch Dermatol Ges* 2011;9:33-40.
- Baumgartner A, Hueppe M, Schmeller W. Long-term benefit of liposuction in patients with lipoedema: A follow-up study after an average of 4 and 8 years. *Br J Dermatol* 2016;174:1061-7.