



NOTE

Pathology

Pyelonephritis caused by *Mannheimia varigena* in a Holstein calf

Tetsuya KOMATSU¹⁾, Nanami INABA¹⁾, Eri WATANDO¹⁾, Kennosuke SUGIE¹⁾,
Kumiko KIMURA²⁾, Ken KATSUDA³⁾ and Tomoyuki SHIBAHARA^{2,4)*}

¹⁾Aichi Prefectural Chuo Livestock Hygiene Service Center, 1-306 Jizono, Miaicho, Okazaki, Aichi 444-0805, Japan

²⁾Division of Pathology and Pathophysiology, National Institute of Animal Health, National Agriculture and Food Research Organization (NARO), 3-1-5 Kannondai, Tsukuba, Ibaraki 305-0856, Japan

³⁾Division of Bacterial and Parasitic Disease, National Institute of Animal Health, National Agriculture and Food Research Organization (NARO), 3-1-5 Kannondai, Tsukuba, Ibaraki 305-0856, Japan

⁴⁾Department of Veterinary Science, Graduate School of Life and Environmental Sciences, Osaka Prefecture University, 1-58 Rinku-oraikita, Izumisano, Osaka 598-8531, Japan

ABSTRACT. A 7-day-old calf died following development of mild respiratory symptoms. Postmortem examination revealed the kidneys were inflamed, and Gram-negative bacteria was detected in the kidneys, supporting the diagnosis of suppurative pyelonephritis. *Mannheimia varigena* antigen was found in the lesions and the cytoplasm of macrophages and neutrophils in the renal cortex. The Gram-negative bacilli from the kidney were identified as *M. varigena* by sequencing the 16S rDNA. Although *M. varigena* is known to cause bovine respiratory disease syndrome, shipping fever, and meningitis, it was unknown that it could also cause suppurative pyelonephritis. Our study provides the first evidence of suppurative pyelonephritis caused by *M. varigena* in cattle and information that would improve our understanding, diagnosis, and treatment for *M. varigena* infections.

KEY WORDS: cattle, *Mannheimia varigena*, suppurative pyelonephritis

J. Vet. Med. Sci.

81(8): 1113–1116, 2019

doi: 10.1292/jvms.19-0211

Received: 18 April 2019

Accepted: 18 June 2019

Advanced Epub: 28 June 2019

Mannheimia is a Gram-negative bacterium genus that encompasses *M. haemolytica*, *M. varigena*, *M. glucosida*, *M. granulomatis*, and *M. ruminalis* [3]. The most commonly studied *Mannheimia* is *M. haemolytica*, which is associated with diseases such as shipping fever, bovine respiratory disease syndrome [7], and peritonitis [9] in cattle. However, *M. varigena* infection is also associated with a number of conditions such as lung disease [2], shipping fever [10] and could also cause lesions such as suppurative meningitis [5], mastitis, endocarditis, and enteritis [3]. *M. varigena* is normally found within the oral cavity and the gastrointestinal tract [3], but could also be isolated from the upper respiratory tract of healthy calves [4] and the uterus of dairy cows [18]. Although *M. varigena* infection had been reported, there are few studies on histopathology and drug resistance studies using clinically isolated *M. varigena*.

Antibiotic resistance is an emerging global problem in livestock animals, and multi drug resistance had been reported in *M. haemolytica* [14] and drug resistance gene was not only *M. haemolytica* [14] but also *M. varigena* [12, 13], however, the information of drug resistance using clinically isolated *M. varigena* is limited.

Here, we report a fatal case of pyelonephritis caused by *M. varigena* infection, providing histopathological and bacterial characteristic of *M. varigena* in a neonatal calf.

A 7-day-old female Holstein calf at a farm housing 45 crossbred and 45 Holstein cattle was presented with rough breathing and fever (38.7°C) in January 2016. Despite ampicillin treatment, the calf died the next day. The animal was brought to Aichi Prefectural Chuo Livestock Hygiene Service Center where a postmortem necropsy was performed. *Mycoplasma bovis* was isolated from a nasal and ear swab of two calves that had died within a week of each other and no symptoms were detected in the adult cows and the other calves.

Necropsy examination revealed that both kidneys were inflamed, and small, dark-red lesions were scattered throughout the renal cortex (Fig. 1a). Hemorrhage was found in the renal pelvis on the cut surface of the kidney. Furthermore, the lungs showed dark red lobules. However, no visible lesions were found in the other organs. Tissue samples of the liver, spleen, left kidney, heart, lung, thymus, and brain were fixed in 10% neutral-buffered formalin. Fixed tissues were embedded in paraffin wax, sectioned at approximately 3 μm thickness, and stained with hematoxylin and eosin (H&E) or Gram stain for histological examination. To

*Correspondence to: Shibahara, T.: tshiba@affrc.go.jp

©2019 The Japanese Society of Veterinary Science



This is an open-access article distributed under the terms of the Creative Commons Attribution Non-Commercial No Derivatives (by-nc-nd) License. (CC-BY-NC-ND 4.0: <https://creativecommons.org/licenses/by-nc-nd/4.0/>)

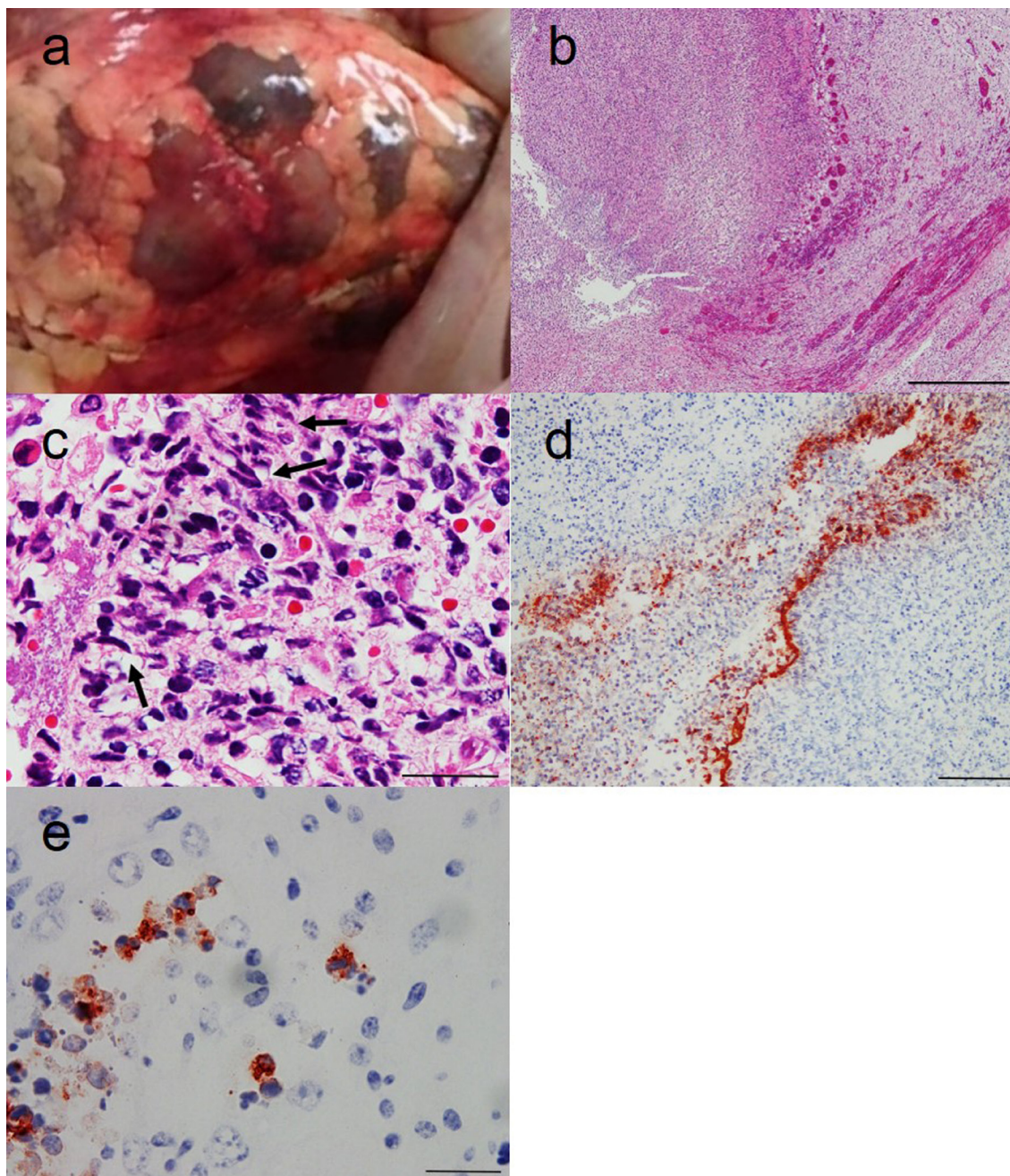


Fig. 1. a. Kidney, swollen and small, dark-red lesions scattered throughout the cortex are visible. b. Suppurative lesion with congestion and hemorrhage in the renal pelvis. H&E staining. Bar=500 μ m. c. Infiltration of many oat-like cells (arrows) and neutrophils in the suppurative lesion of renal pelvis. H&E staining. Bar=20 μ m. d. *Mannheimia varigena* antigen was detected in the suppurative lesion of renal pelvis. Bar=100 μ m. e. *M. varigena* antigen was detected in the cytoplasm of macrophages and neutrophils in the interstitium of renal cortex. Bar=20 μ m.

label the *M. varigena* antigen, 3- μ m thick sections of formalin fixed samples of liver, spleen, kidney, and lung were treated with 3% hydrogen peroxide in methanol to suppress endogenous peroxidase activity. Antigen retrieval was performed by treating the sections with 0.1% actinase E solution in phosphate buffered saline at 37°C for 20 min. The tissues were then incubated with rabbit anti-*M. varigena* 971 strain serum (National Institute of Animal Health, Tsukuba, Japan) as primary antibody for 60 min at room temperature followed by a secondary antibody (Histofine Simple Stain MAX-PO (Multi; Nichirei Bioscience Inc., Tokyo, Japan) for 30 min at room temperature. The sections were then incubated with aminoethyl carbazole (AEC) substrate solution (Histofine Simple Stain AEC solution; Nichirei Bioscience Inc.) at room temperature for 5 min. and then counterstained with hematoxylin. Sections of tissues containing *M. varigena* and pieces of liver (into which *M. haemolytica* serotypes A1, A2, A5-A9, A12-A14, A16, *Bibersteinia trehalosi* serotypes T3, T4, T10, T15 and *M. glucosida* had been injected) were used as positive controls in order to verify the immunohistochemical specificity of the reaction. *Pasteurella haemolytica* biotype A had 13 serotypes and *P.*

haemolytica biotype T had 4 serotypes [16]. Subsequently, in 1999, based on the results from DNA-DNA hybridization and 16S RNA studies, all serotypes of *P. haemolytica* biotype A were grouped under a newly created genus *Mannheimia* [16]. All serotypes under biotype A became *M. haemolytica* except A11, which became *M. glucosida*. All four serotypes of *P. haemolytica* biotype T were named as *P. trehalosi* retaining the genus *Pasteurella* [16]. Further taxonomical analysis in 2007 resulted in the creation of a new genus, *Bibersteinia*, under which were included all the four *P. trehalosi* serotypes, later named as *B. trehalosi* [16].

Suppurative lesions were widely detected in the renal pelvic mucous membrane and renal papilla (Fig. 1b) and showed numerous neutrophils and oat-like cells (Fig. 1c). Gram-negative bacilli were detected in the lesions and the lumen of the renal pelvis.

Moderate to severe congestion and hemorrhage were observed surrounding the suppurative lesion in the inner medulla (Fig. 1b), and thrombi were also scattered in the lesions. Cellular debris and neutrophils were found in some of the collecting and renal tubules; the neutrophils had also infiltrated the interstitium surrounding the tubules. In other organs, thymocytes were decreased in the thymus cortex, and neutrophils were found around the white pulp of the spleen. Slight edema and congestion were observed in the lung. No significant lesions were detected in other organs. Gram-negative bacteria with *M. varigena* antigens were detected in the suppurative lesion and lumen of renal pelvis (Fig. 1d) and cytoplasm of macrophages and neutrophils in the interstitium (Fig. 1e). No antigen was detected in the liver, spleen and lung. In addition, a positive reaction was detected only in the positive control sections of tissues containing *M. varigena*, but not in the other positive controls. The rabbit anti-*M. varigena* 971 strain serum specifically reacted with *M. varigena* by immunohistochemical analysis.

To isolate the bacteria, tissue homogenates prepared from the liver, spleen, left kidney, heart, lung, and brain were spread onto normal sheep blood agar, chocolate agar, and deoxycholate-hydrogen sulfide-lactose agar plates. The agar plates were incubated at 37°C in 5% CO₂ with and without oxygen. Gram-negative bacilli were isolated from only the left kidney sample. No bacteria were isolated from any of the other samples tested. The isolates from the kidney were applied to biochemical testing using the API 20 NE system (BioMérieux, Inc., Marcy l'Etoile, France), according to the manufacturer's instructions, which confirmed the presence of *M. haemolytica* (1420004).

To detect *Mycoplasma*, lung homogenate supernatant was incubated in NK liquid medium (Kanto Chemical Co., Inc., Tokyo, Japan) at 37°C in aerobic conditions for 3 days. After incubation, medium was centrifuged and sediment was used for DNA extraction. Genomic DNA was extracted from both isolates and sediment by using Instagene Matrix (Bio-Rad Laboratories, Hercules, CA, U.S.A.) according to the manufacturer's instructions.

To identify if *M. haemolytica*, *M. glucosida*, *M. ruminantis*, *M. granulomatis*, and *M. varigena* were present in the isolate, specific PCR assay for 16S ribosomal DNA was performed and sequenced [3, 11]. The partial sequence analysis of the 16S rDNA from the isolate (1,468 bp region) showed 99.0% similarity with *M. varigena* type strain, supporting the presence of *M. varigena* in the isolate. The 16S rDNA sequences were deposited to DNA Data Bank of Japan (Accession Number: LC466640). *M. bovis* [6] and *M. dispar* [15] were not detected from the DNA sample of sediment using PCR.

To determine the susceptibility of the *M. varigena* to antibiotics, minimum inhibitory concentration (MIC) was calculated using broth dilution method according to clinical laboratory standards institute (CLSI) method [8] against ampicillin (ABPC), ceftiofur (CTF), tetracycline (TC), florfenicol (FF), enrofloxacin (ERFX), and danofloxacin (DNFX). The breakpoints of these antibiotics were referred from the breaking point of *M. haemolytica* based on CLSI [8] and Alexander *et al.* [1]. The isolate analyzed in the current study was susceptible to all antimicrobial drugs (Table 1).

Our results confirmed *M. varigena* infection in the dead Holstein calf, which could be the cause of the suppurative lesions in the renal pelvis. *M. bovis* was not detected in the lung homogenates, and therefore, it is unlikely to be associated with the pulmonary lesions. Although *M. varigena* could cause various lesions such as suppurative meningitis [5], mastitis, endocarditis, enteritis [3], and pneumonia [2], it is unknown if *M. varigena* is associated with pyelonephritis, and therefore, this is the first report of pyelonephritis caused by *M. varigena*.

In the current study, suppurative lesions and bacterial isolation were limited only to the kidney. Gram staining and histological examination revealed that *M. varigena* was present only in the suppurative lesions of kidney. Although the bladder or ureter were not examined, *M. varigena* would be infected via urethra because of limited detection of *M. varigena*.

In our case, the isolates were misidentified as *M. haemolytica* by commercial biochemical test. However, the 16S rDNA profiles differ between the different *Mannheimia* species [11] and we determined the isolated bacteria to be *M. varigena* using this method. It was reported that *M. varigena* is the most frequently isolated bacteria from bovine respiratory disease after *M. haemolytica* [17], and reliable detection methods for *M. varigena* such as PCR would be useful for accurate and rapid diagnosis.

Drug resistance is one of the biggest concerns in raising livestock. Although tetracycline [13] and multi-drug resistance genes

Table 1. Antimicrobial susceptibility tests

Class	Antimicrobial agents	MIC	Breaking point	Reference
Penicillin	Ampicillin (ABPC)	≤1	16	[1]
Cephem	Ceftiofur (CTF)	≤0.12	8	[8]
Tetracycline	Tetracycline (TC)	0.5	8	[8]
Amphenicol	Florfenicol (FF)	≤1	8	[8]
New Quinolone	Enrofloxacin (ERFX)	≤0.03	2	[8]
	Danofloxacin (DNFX)	≤0.03	0.25	[8]

MIC: minimum inhibitory concentration.

[12] had been detected previously in *M. varigena* [4], the isolate in this study did not show drug resistance to any of the tested drugs. Although the calf in this study was treated with ampicillin immediately following presentations of breathing difficulties, the symptoms were not alleviated despite lack of resistance to ampicillin. This could be explained in part by the fact that kidney functions were attenuated beyond recovery before ampicillin treatment. Therefore, it is important that diagnosis is made rapidly in these situations.

In conclusion, we have reported a unique case of pyelonephritis caused by *M. varigena* in a calf. Although *M. varigena* could cause a number of diseases, pyelonephritis had not been associated with *M. varigena* infection. *M. varigena* could be misidentified by using commercially available biochemical test and 16S rDNA sequence analysis is required to correctly identify *M. varigena* infection. This study provides evidence that *M. varigena* could cause pyelonephritis and correct identification of the infectious agent and drug resistance would be useful for future treatments.

ACKNOWLEDGMENTS. The authors thank Mr. M. Kobayashi, Ms. M. Shimada, and Mr. K. Hirano for histopathological assistance.

REFERENCES

1. Alexander, T. W., Cook, S., Klima, C. L., Topp, E. and McAllister, T. A. 2013. Susceptibility to tulathromycin in *Mannheimia haemolytica* isolated from feedlot cattle over a 3-year period. *Front. Microbiol.* **4**: 297. [Medline] [CrossRef]
2. Angen, Ø., Ahrens, P. and Bisgaard, M. 2002. Phenotypic and genotypic characterization of *Mannheimia (Pasteurella) haemolytica*-like strains isolated from diseased animals in Denmark. *Vet. Microbiol.* **84**: 103–114. [Medline] [CrossRef]
3. Angen, O., Mutters, R., Caugant, D. A., Olsen, J. E. and Bisgaard, M. 1999. Taxonomic relationships of the [*Pasteurella*] *haemolytica* complex as evaluated by DNA-DNA hybridizations and 16S rRNA sequencing with proposal of *Mannheimia haemolytica* gen. nov., comb. nov., *Mannheimia granulomatis* comb. nov., *Mannheimia glucosida* sp. nov., *Mannheimia ruminalis* sp. nov. and *Mannheimia varigena* sp. nov. *Int. J. Syst. Bacteriol.* **49**: 67–86. [Medline] [CrossRef]
4. Cattr, B., Decostere, A., Schwarz, S., Kehrenberg, C., de Kruif, A. and Haesebrouck, F. 2006. Detection of tetracycline-resistant and susceptible pasteurellaceae in the nasopharynx of loose group-housed calves. *Vet. Res. Commun.* **30**: 707–715. [Medline] [CrossRef]
5. Cattr, B., Opsomer, G., Decostere, A., Feyen, B., de Kruif, A. and Haesebrouck, F. 2004. Fatal meningitis in a calf caused by *Mannheimia varigena*. *Res. Vet. Sci.* **77**: 187–188. [Medline] [CrossRef]
6. Chávez González, Y. R., Ros Bascuñana, C., Bölske, G., Mattsson, J. G., Fernández Molina, C. and Johansson, K. E. 1995. In vitro amplification of the 16S rRNA genes from *Mycoplasma bovis* and *Mycoplasma agalactiae* by PCR. *Vet. Microbiol.* **47**: 183–190. [Medline] [CrossRef]
7. Clawson, M. L., Murray, R. W., Sweeney, M. T., Apley, M. D., DeDonder, K. D., Capik, S. F., Larson, R. L., Lubbers, B. V., White, B. J., Kalbfleisch, T. S., Schuller, G., Dickey, A. M., Harhay, G. P., Heaton, M. P., Chitko-McKown, C. G., Brichta-Harhay, D. M., Bono, J. L. and Smith, T. P. 2016. Genomic signatures of *Mannheimia haemolytica* that associate with the lungs of cattle with respiratory disease, an integrative conjugative element, and antibiotic resistance genes. *BMC Genomics* **17**: 982. [Medline] [CrossRef]
8. Clinical and Laboratory Standard Institution Guidelines 2015. Performance Standards for Antimicrobial Disk and Dilution Susceptibility Tests for Bacteria Isolated from Animals. Approved Standard-Third ed., CLSI document VET01S, CLSI, Wayne.
9. Harada, N., Takizawa, K., Matsuura, T., Yokosawa, N., Tosaki, K., Katsuda, K., Tanimura, N. and Shibahara, T. 2019. Bovine peritonitis associated with *Mannheimia haemolytica* serotype 2 in a three-day-old Japanese Black calf. *J. Vet. Med. Sci.* **81**: 143–146. [Medline] [CrossRef]
10. Harhay, G. P., Murray, R. W., Lubbers, B., Griffin, D., Koren, S., Phillippy, A. M., Harhay, D. M., Bono, J., Clawson, M. L., Heaton, M. P., Chitko-McKown, C. G. and Smith, T. P. 2014. Complete closed genome sequences of four *Mannheimia varigena* isolates from cattle with shipping fever. *Genome Announc.* **2**: e00088–e14. [Medline]
11. Katsuda, K., Ojima, T., Tomiyama, M., Sato, Y. and Mikami, O. 2016. PCR identification of *Mannheimia* species isolated from cattle. *J. Farm Anim. Infec. Dis.* **5**: 3 (in Japanese).
12. Kehrenberg, C. and Schwarz, S. 2002. Nucleotide sequence and organization of plasmid pMVSCS1 from *Mannheimia varigena*: identification of a multiresistance gene cluster. *J. Antimicrob. Chemother.* **49**: 383–386. [Medline] [CrossRef]
13. Kehrenberg, C., Salmon, S. A., Watts, J. L. and Schwarz, S. 2001. Tetracycline resistance genes in isolates of *Pasteurella multocida*, *Mannheimia haemolytica*, *Mannheimia glucosida* and *Mannheimia varigena* from bovine and swine respiratory disease: intergeneric spread of the *tet(H)* plasmid pMHT1. *J. Antimicrob. Chemother.* **48**: 631–640. [Medline] [CrossRef]
14. Klima, C. L., Alexander, T. W., Read, R. R., Gow, S. P., Booker, C. W., Hannon, S., Sheedy, C., McAllister, T. A. and Selinger, L. B. 2011. Genetic characterization and antimicrobial susceptibility of *Mannheimia haemolytica* isolated from the nasopharynx of feedlot cattle. *Vet. Microbiol.* **149**: 390–398. [Medline] [CrossRef]
15. Mori, Y., Nishimoto, S., Omoto, T., Muneta, Y., Shimoji, Y. and Kobayashi, H. 1998. Detection of *Mycoplasma dispar* from pneumonic lungs of beef cattle. *Jpn. J. Mycoplasmaology.* **25**: 78–80 (in Japanese).
16. Murugananthan, A., Shanthalingam, S., Batra, S. A., Alahan, S. and Srikumaran, S. 2018. Leukotoxin of *Bibersteinia trehalosi* contains a unique neutralizing epitope, and a non-neutralizing epitope shared with *Mannheimia haemolytica* Leukotoxin. *Toxins (Basel)* **10**: 220. [Medline] [CrossRef]
17. Rérat, M., Albini, S., Jaquier, V. and Hüsey, D. 2012. Bovine respiratory disease: efficacy of different prophylactic treatments in veal calves and antimicrobial resistance of isolated *Pasteurellaceae*. *Prev. Vet. Med.* **103**: 265–273. [Medline] [CrossRef]
18. Santos, T. M., Gilbert, R. O. and Bicalho, R. C. 2011. Metagenomic analysis of the uterine bacterial microbiota in healthy and metritic postpartum dairy cows. *J. Dairy Sci.* **94**: 291–302. [Medline] [CrossRef]