

X-rays had little value in diagnosing children's abnormal skull shapes, and primary care clinicians should refer concerns to specialist teams

Hugh O'Sullivan¹  | Shirley Bracken² | Jodie Doyle¹ | Eilish Twomey³ |
Dylan J. Murray² | Louise Kyne¹

¹Department of Paediatrics, Children's Health Ireland at Temple Street, Dublin, Ireland

²National Paediatric Craniofacial Centre, Children's Health Ireland at Temple Street, Dublin, Ireland

³Radiology Department, Children's Health Ireland at Temple Street, Dublin, Ireland

Correspondence

Hugh O'Sullivan, Department of Paediatrics, Children's Health Ireland at Temple Street, Dublin, Ireland.

Email: hugh.o-sullivan@ucdconnect.ie

Abstract

Aim: This study examined the consensus between the primary care radiological diagnosis and specialist clinical diagnosis of abnormal skull shapes in children.

Methods: We performed a retrospective review of children treated at the National Paediatric Craniofacial Centre at Children's Health Ireland, Dublin, Ireland. Group 1 were referred by primary care colleagues concerned about suspected abnormal skull shapes from 1 January 2015 to 30 May 2017. These included cases where they sought specialist confirmation that the skull shape was normal. Group 2 underwent surgery for craniosynostosis from 1 January 2011 to 25 October 2017. The primary care skull X-ray reports were examined for both groups to see whether they matched the specialist diagnosis.

Results: Group 1 comprised 300 children, and 59 (20%) had pre-referral skull X-rays. The primary care X-ray reports and specialist diagnoses agreed in 44 (75%) cases, including 19 (43%) who had a normal skull shape. Group 2 comprised 274 children, and 63 (23%) had pre-referral skull X-rays. In this group, there was agreement in 41 (65%) diagnoses; however, the primary care X-ray reports did not diagnose craniosynostosis for the remaining 22 (35%) children.

Conclusion: X-rays were of little value in diagnosing abnormal skull shapes, especially craniosynostosis, and primary care clinicians should refer concerns to specialist teams.

KEYWORDS

abnormal skull shape, craniosynostosis, craniofacial surgery, deformational plagiocephaly, skull X-rays

Previously presented as a poster at the 26th European Society for Paediatric Neurosurgery Congress and 9th Europaediatrics Congress.

This is an open access article under the terms of the Creative Commons Attribution-NonCommercial-NoDerivs License, which permits use and distribution in any medium, provided the original work is properly cited, the use is non-commercial and no modifications or adaptations are made.

© 2020 The Authors. *Acta Paediatrica* published by John Wiley & Sons Ltd on behalf of Foundation Acta Paediatrica.

1 | INTRODUCTION

It is relatively common for infants and children to present to primary care services with abnormal skull shapes.¹ The National Paediatric Craniofacial Centre at Children's Health Ireland, Dublin, Ireland, receives a large number of primary care referrals each year.² Skull shape pathology can be divided into two main categories: deformational plagiocephaly³ and craniosynostosis, where premature ossification and closure of the skull sutures occurs.¹ Craniosynostosis is estimated to occur in an average of one in 2300 live births.⁴

As the brain undergoes rapid growth in the first 2 years of life, patent skull sutures are essential to allow concomitant expansion of the skull.¹ When brain growth occurs in a confined environment, intracranial pressure rises, and it has been suggested that this has been associated with the intellectual disability and neurological sequelae seen in many cases of syndromic craniosynostosis.⁵ Furthermore, the appearance of craniosynostosis can be quite striking and that is why there are cosmetic and psychological reasons for corrective surgery.⁵

Diagnosing abnormal skull shapes and differentiating between deformational plagiocephaly and craniosynostosis can be challenging for clinicians. The abnormality is normally first noticed by parents or caregivers, who consult their family doctor.⁴

Investigations often include three-view radiography to visualise the skull suture fusion.⁶ However, it is widely accepted that this investigation is difficult to interpret and rarely, if ever, provides a definite diagnosis of craniosynostosis.² Apart from the additional burden this places on parents to attend an additional investigation, this also exposes infants and children to ionising radiation, which theoretically increases their risk of developing malignancies.⁶ That is why the suitability of this diagnostic test has been called in question.

Suspected abnormal skull shapes accounted for 66% of new referrals to our specialist centre in the 12-month period from 30 June 2012 to 1 July 2013,² and in 50% of cases, there was agreement between the primary care referral report and the clinical diagnosis by the specialist team. The current study examined the skull X-rays of children in two groups during two periods: those who were referred with an abnormal or questionable skull shape and those who had surgery for craniosynostosis. Agreement between the primary care radiological diagnosis and specialist clinical diagnosis was investigated to determine the value of X-rays in diagnosing children with abnormal skull shapes.

2 | METHODS

We conducted a retrospective study that examined the healthcare records of two groups of children who had a skull X-ray performed as part of their primary care referral to our specialist centre. The children in group 1 were referred between 1 January 2015 and 30 May 2017 with suspected abnormal skull shapes or requests to confirm that their skull shapes were normal. Group 2 consisted of children

Key notes

- This study examined the consensus between the primary care radiological diagnosis and the specialist clinical diagnosis of abnormal skull shapes in children.
- The primary care X-ray reports and specialist diagnoses agreed in 75% of cases, but this fell to 65% in children who later required surgery for craniosynostosis.
- X-rays were of little value in diagnosing abnormal skull shapes, especially craniosynostosis, and primary care clinicians should refer concerns to specialist teams.

who underwent cranial vault surgery for confirmed craniosynostosis during the period 1 January 2011 to 25 October 2017.

Confirmation of the primary care referral and specialist clinical diagnosis was obtained from clinical letters, and the radiology reports were examined for the radiological diagnosis for each child. Agreement between the radiological diagnosis and the clinical diagnosis was reported as a match and lack of agreement was reported as no match.

Ethical approval for this study was provided by the Research Ethics Committee of Children's Health Ireland (application number 18.015).

3 | RESULTS

Group 1 comprised 300 children. Of these, 59 (20%) had a skull X-ray prior to their referral to our specialist centre, and the clinical diagnoses provided by their primary care clinicians comprised 17 (29%) with craniosynostosis, 19 (32%) with deformational plagiocephaly and 23 (39%) with a normal skull. In 44/59 (75%) cases, there was a match between the radiological diagnosis and the clinical diagnosis provided by our specialist team. This included confirmation that 19/44 (43%) had a normal skull shape. There was no match for the 7/17 (41%) children initially diagnosed with craniosynostosis, 4/19 (21%) children with deformational plagiocephaly and 4/23 (17%) with a normal skull shape (Figure 1). The outcomes of these 300 children following review by the specialist team can be seen in Figure 2.

Group 2 comprised 274 children who underwent correctional surgery for craniosynostosis and included 63 (23%) who had skull X-rays performed before their referral to our specialist team. Figure 3 presents the agreement and the various success rates when the craniosynostosis subtypes were identified. Craniosynostosis was classified as either single suture, which included sagittal, metopic, unicoronal and lambdoid, or multi-suture, which occurred mostly in children with craniofacial syndromes. A match was reported for 41/63 (65%) of the children in this group. These comprised a match of two (100%) lambdoid diagnoses, three (50%) unicoronal, four (44%) multi-suture, five (36%) metopic and 27 (84%) sagittal.

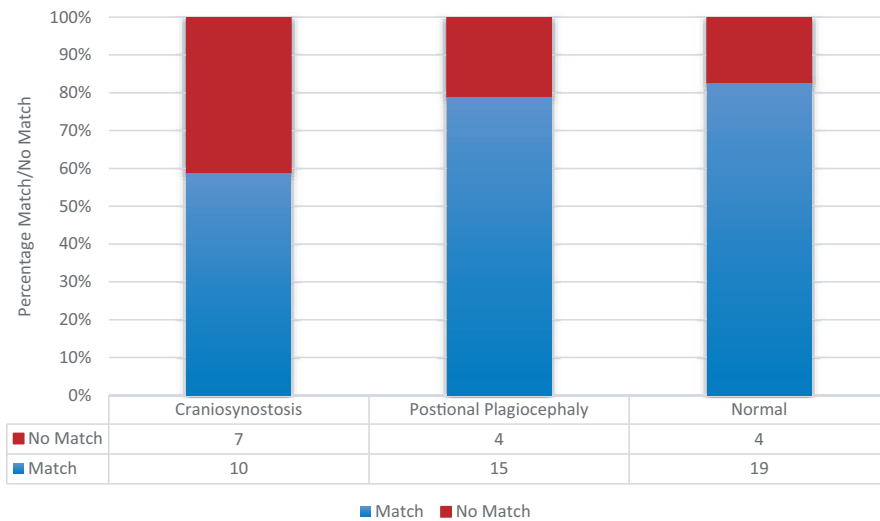


FIGURE 1 Group 1 radiological and clinical consensus [Colour figure can be viewed at wileyonlinelibrary.com]

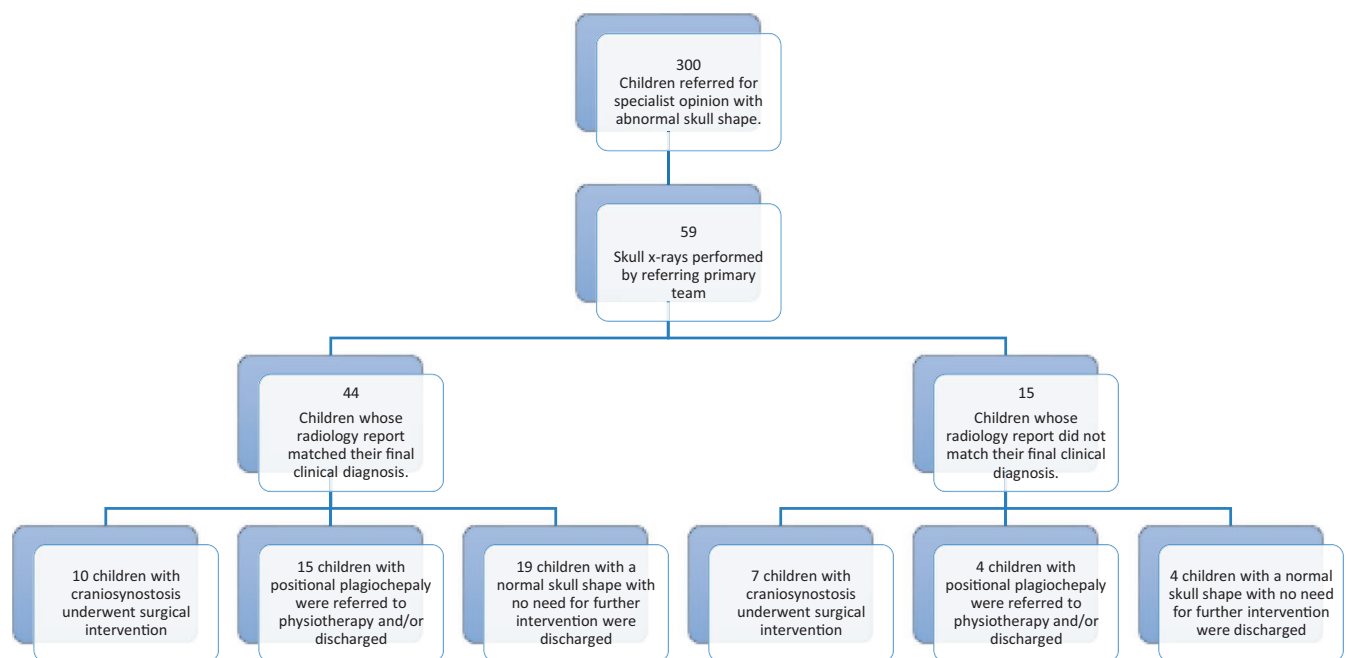


FIGURE 2 Group 1 outcomes of children referred with abnormal skull shape [Colour figure can be viewed at wileyonlinelibrary.com]

In this group, there was no match for 17/63 (27%) results, while a further five (8%) were inconclusive; however, all of the children in this group underwent correctional surgery for craniosynostosis (Figure 4).

4 | DISCUSSION

The findings from our study indicate that primary care clinicians were not always confident about skull X-rays when they referred children with abnormal skull shapes to our specialist team or wanted confirmation that the shape was normal. In our study, the radiology report did not match the clinical diagnosis for 15 (25%) of the 59 children in group 1, who were referred for assessment of their skull shape, together with an X-ray. Fortunately, while no match was

identified for 7 of the 17 children with craniosynostosis, they were still referred. However, 19 children in this group who had a normal skull reported on X-ray report were still referred to our specialist centre for a second opinion.

In group 2, 63 children (23%) had a skull X-ray performed and subsequently underwent correctional surgery for craniosynostosis. We found that even when craniosynostosis was correctly diagnosed, primary care clinicians had varying levels of success in determining the craniosynostosis subtype when they consulted the skull X-rays. It may be tempting to argue in favour of skull X-rays when planning surgery, but we must consider that 17 (27%) of these X-ray reports were not a match and a further five (8%) were inconclusive. We believe that the stark discrepancy in clinical and radiological findings in the two groups shown was a strength of this study.

FIGURE 3 Group 2 radiological and clinical consensus [Colour figure can be viewed at wileyonlinelibrary.com]

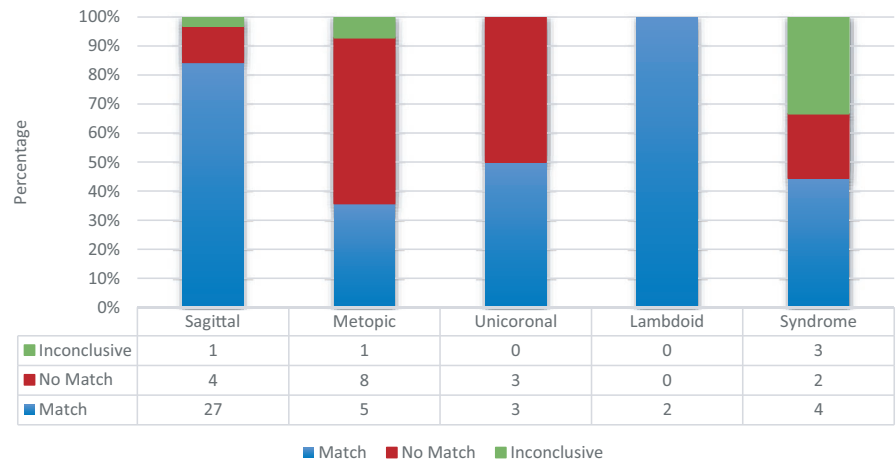
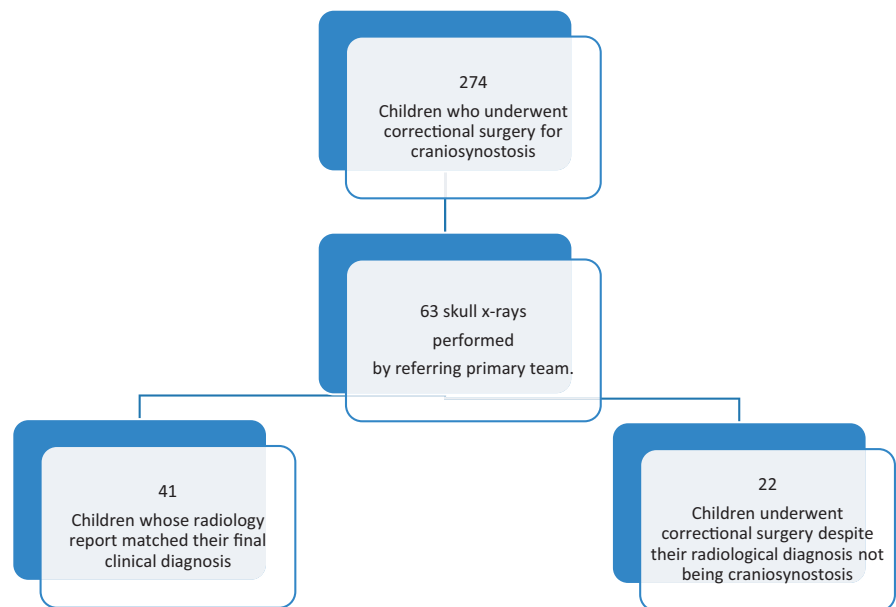


FIGURE 4 Group 2 children who underwent correctional surgery for craniosynostosis [Colour figure can be viewed at wileyonlinelibrary.com]



We were not privy to the circumstances around the referral process of these children, for example whether the referral was made by the same primary care clinician who ordered the X-ray. This is admittedly a limitation of this study. However, the skull X-rays were ultimately not useful and they just added unnecessary procedures during the referral to our specialist team. In general, CT scans are far more useful for planning surgery and they are the first-line investigation used by our specialist team to confirm clinical suspicions of craniosynostosis.

Educating healthcare professionals about abnormal skull shapes is essential. This can be achieved by traditional undergraduate training or using more innovative technology, such as mobile phone apps or distance teaching that can reach clinicians at all levels. Since June 2016, our specialist centre has invited primary care clinicians and other interested clinicians to observe our new patient clinics. This has been very successful, with 14 of the 19 clinicians who attended up to January 2018, reporting that this was very beneficial for their everyday practice. A Talking Heads Education Morning was also held in June 2018,⁷ and this was

attended by over 50 clinicians, primary care physicians, family doctors, neonatologists and paediatricians.

So what should paediatricians or primary care physicians do when they are confronted with a case of abnormal skull shape? We feel that including photographs with a detailed referral² is often sufficient for a diagnosis. They are also relatively quick, easy to obtain and can be taken by the referring clinician or the parents. We have included information on the photographs that are most useful on our website.⁸ The six most useful photographs are of the front of the head and face, looking upwards from the nose to the brow, top of the head, back of the head and both the right and left side of the head and face.

5 | CONCLUSION

This study examined the consensus between the primary care radiological diagnosis and specialist clinical diagnosis of abnormal skull shapes in children. It showed that X-rays were of little value in

diagnosing abnormal skull shapes, especially craniosynostosis, and primary care clinicians should refer concerns to specialist teams. Providing a range of photographs with their detailed diagnosis is particularly useful and is often sufficient for a diagnosis.

CONFLICT OF INTEREST

The authors have no conflicts of interest to declare.

ORCID

Hugh O'Sullivan  <https://orcid.org/0000-0002-0269-6991>

REFERENCES

1. Blaser S, Padfield P, Chitayat D, Forrest CR. Skull base development and craniosynostosis. *Pediatr Radiol*. 2015;45:485-496.
2. Curran TA, McGillivray A, Murray D. A review of the craniofacial referrals to the national paediatric craniofacial centre and introduction of a new referral pathway. *Ir Med J*. 2016;109(1):325.
3. Siegenthaler M. Methods to diagnose, classify, and monitor infantile deformational plagiocephaly and brachycephaly: a narrative review. *J Chiropr Med*. 2015;14:191-204.
4. Mathijssen IMJ. Guideline for care of patients with the diagnoses of craniosynostosis: working group on craniosynostosis. *J Craniofac Surg*. 2015;26:1735-1807.
5. Ridgway E, Weiner H. Skull deformities. *Pediatr Clin N Am*. 2004;51:359-387.
6. Rozovsky K, Udjus K, Wilson N, Barrowman NJ, Simanovsky N, Miller E. Cranial ultrasound as a first-line imaging examination for craniosynostosis. *Paediatrics*. 2016;137(2):2015-2230.
7. National Paediatric Craniofacial Centre; 2018. <http://www.craniofacial.ie/education/talking-heads-education-morning-16th-june-2018/> Accessed July 01, 2019
8. Craniofacial Ireland; 2020. <http://www.craniofacial.ie/healthcare-professionals/referral/> Accessed November 10, 2020.

How to cite this article: O'Sullivan H, Bracken S, Doyle J, Twomey E, Murray DJ, Kyne L. X-rays had little value in diagnosing children's abnormal skull shapes, and primary care clinicians should refer concerns to specialist teams. *Acta Paediatr*. 2021;110:1330-1334. <https://doi.org/10.1111/apa.15686>