




## CASE REPORT

# A case report of prostate adenocarcinoma with leptomeningeal carcinomatosis and intracerebral metastasis

Danial Fazilat-Panah<sup>1</sup>  | Nahid Ahmadi<sup>1</sup> | Dariush Moslemi<sup>1</sup> |  
Masoumeh Karimi<sup>1</sup> | Alireza Taji<sup>1</sup> | Mansoureh Dehghani<sup>2</sup> |  
Ali Emadi Torghabeh<sup>3,4</sup>  | Zahra Keshtpour Amlashi<sup>5</sup>  |  
Mohammadreza Saghafi<sup>6</sup> | Maedeh Alsadat Fatemi<sup>1</sup>

<sup>1</sup>Cancer Research Center, Babol University of Medical Sciences, Babol, Iran

<sup>2</sup>Neyshabur University of Medical Sciences, Neyshabur, Iran

<sup>3</sup>Cancer Research Center, Mashhad University of Medical Sciences, Mashhad, Iran

<sup>4</sup>Department of Radiotherapy and Oncology, Faculty of Medicine, Mashhad University of Medical Sciences, Mashhad, Iran

<sup>5</sup>Hamadan University of Medical Sciences, Hamadan, Iran

<sup>6</sup>Qazvin University of Medical Sciences, Qazvin, Iran

## Correspondence

Nahid Ahmad, Cancer Research Center, Babol University of Medical Sciences, Babol, Iran.

Email: Nahidahmadi1989@gmail.com

## Funding information

Babol University of Medical Sciences

## Abstract

Despite the fact that prostate cancer is the most prevalent cancer in men, metastases to the central nervous system including leptomeningeal involvement by prostate carcinoma is a rare event. The prognosis of metastatic prostate cancer is very poor due to lack of CNS penetrating therapeutic agents.

## KEYWORDS

CNS metastasis, leptomeningeal carcinomatosis, prostate cancer

## 1 | INTRODUCTION

Despite the prostate cancer is the most prevalent men cancer, metastases to the central nervous system including leptomeningeal involvement by prostate carcinoma are a rare event. Here, we detected leptomeningeal carcinomatosis based on MRI findings in a 67-year-old patient with

castration-resistant metastatic prostate cancer who presented paraplegia and paresthesia of both limbs.

Prostate cancer is second only to lung cancer as a leading cause of cancer-related death in men.<sup>1</sup> Most men with prostate cancer have asymptomatic and indolent disease. In advanced stages, the most common locations of metastasis from the prostate are bone, lung, and liver.<sup>2</sup> Central

This is an open access article under the terms of the Creative Commons Attribution License, which permits use, distribution and reproduction in any medium, provided the original work is properly cited.

© 2021 The Authors. *Clinical Case Reports* published by John Wiley & Sons Ltd.

nervous system (CNS) complications commonly occur in the late stages of advanced disease. In rare occasions, leptomeningeal carcinomatosis (LC) can occur in patients with prostate cancer.<sup>3,4</sup> In addition to the metastatic disease, paraneoplastic syndromes such as neuropathies, cerebellar ataxia, and limbic and brainstem encephalitis, may also occur.<sup>5,6</sup> Here, we report a patient with metastatic prostate cancer who developed CNS symptoms, and the MRI study of the brain revealed leptomeningeal metastasis.

## 2 | CASE

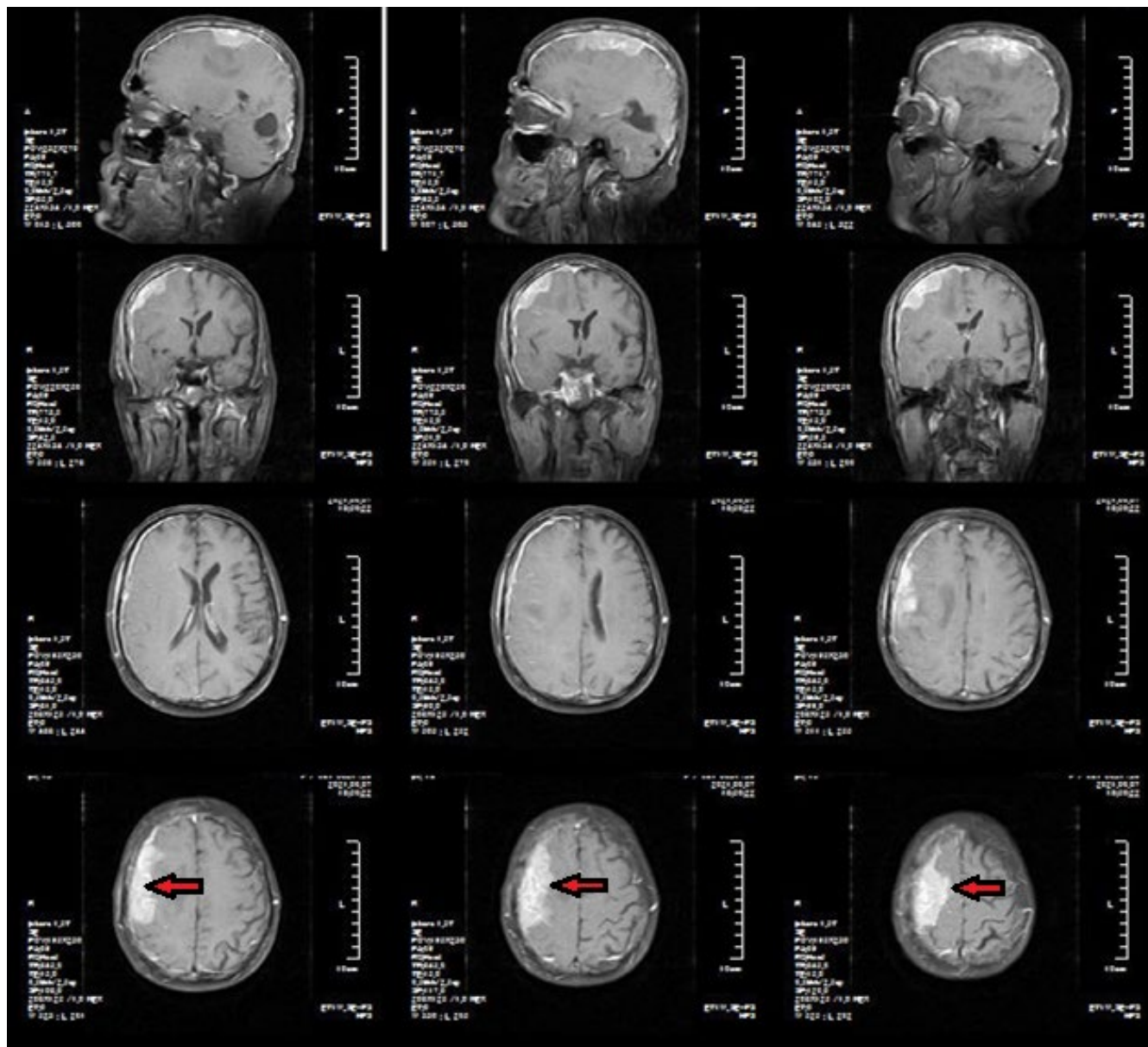
The case is a 67-year-old male patient who was first admitted to the urology department with a history of dysuria and dribbling at the termination of urination, 3 years ago. There were no other significant medical or familial histories. Further assessments showed an elevated prostate-specific antigen (PSA, 50 ng/mL) in addition to normal values for complete blood count, kidney, and liver function, alkaline phosphatase, and lactate dehydrogenase. A computed tomography scan (CT) of the chest, abdomen, and pelvis with and without intravenous contrast was obtained showing an enlarged prostate without any regional lymph-nodes involvement or distant metastasis. A 12-core transrectal ultrasound-guided prostate needle biopsy (TRUS) revealed a high-grade adenocarcinoma of the prostate (the Gleason score 4 + 4 = 8). The patient underwent a whole body bone scan demonstrating no clear evidence of bone metastasis. As a patient with high-risk prostate cancer, the patient received 2 months of neoadjuvant gonadotropin-releasing hormone (GnRH) agonist. Subsequently, definitive radiotherapy of whole pelvis (50 gray [Gy]/25 fractions [frs]) with a tumor bed boost of 20 Gy in 10 frs was prescribed, along with a concurrent GnRH agonist. After completion of radiotherapy, GnRH agonist was continued and a PSA nadir of 1 ng/mL was recorded. Five months later, the patient underwent a whole body bone scan due to generalized bone pain showing wide-spread bone metastases of thoracolumbar vertebral spine. The serum level of the PSA raised to 280 ng/mL, while the serum level of the testosterone was 5 ng/dL proving a diagnosis of castration-resistant prostate cancer. At this point, zoledronic acid was prescribed 4 mg monthly and palliative radiotherapy to the symptomatic regions was performed (30 Gy/10 frs). After the completion of palliative radiotherapy, the patient was treated with docetaxel (75 mg/m<sup>2</sup>) every 3 weeks and daily prednisolone (5 mg twice a day) for ten courses resulting in significant reduction of serum level of PSA to 5 ng/mL. After 5 months of follow-up, the serum level of PSA raised to 260 ng/mL and the patient developed paraplegia and paresthesia of both limbs. A brain magnetic resonance

imaging (MRI) with and without contrast showed diffuse high signal intensity within the subarachnoid space of the sulci and cisterns on post-contrast T1-weighted images (Figure 1). The patient refused lumbar puncture (LP) for cerebrospinal fluid (CSF) examination.

Patient received whole brain radiotherapy (WBRT) at a dose of 30 Gy in 10 frs. After WBRT, abiraterone acetate (1,000 mg daily) plus prednisolone (5 mg twice daily) was prescribed; however, no significant response was detected. Therefore, a rechallenge by docetaxel plus prednisolone was considered. After five courses, the patient had a stable disease and the level of PSA was decreased to 10 ng/mL.

## 3 | DISCUSSION

Leptomeningeal carcinomatosis (LC) is an uncommon complication of cancer in which the disease metastasizes to the meninges; the term “leptomeninges” refers to the combination of the two meninges, the arachnoid and the pia mater, between which circulates the cerebrospinal fluid. It is estimated that LC occurs in 5% of cancer patients and is most often terminal. Leptomeningeal spread occurs more with hematologic tumors, such as leukemia, at an incidence of 10–15%, and much less frequently with solid tumors at an incidence of 1–5%, the most common being breast, lung, melanoma, gastrointestinal, and primary CNS tumors.<sup>7,8</sup> LC is a rare complication in the course of prostate cancer. An example of the prevalence of LC can be provided by a 33-year retrospective review published by the University of Texas MD Anderson Cancer Center. The study aimed to detect all patients with LC originating from primary GU cancer. Of the 93,960 GU cancer patients, a mere 31 cases of LC were identified, which is approximately 0.03%. Of those that were identified, only 7 were prostate in origin.<sup>9</sup> The most common intracranial sights of metastatic prostate cancer are the leptomeninges (67%), cerebrum (25%), and cerebellum (8%).<sup>10</sup> Typical presenting symptoms of LC include altered mental status, headache, nausea, vomiting, and cranial nerve palsies.<sup>11,12</sup> The patient in this report presented with paraplegia and paresthesia of both limbs. LC diagnosis is challenging given the poor sensitivity of diagnostic modalities. Following detailed physical examination, the patient should undergo a contrast MRI. However, the reported sensitivity is highly variable across the literature ranging from 77 to 100%. As in our patient, diffuse enhancement of the leptomeninges was discovered. Logically, the next step would be an LP. The most definitive tool in the diagnosis of LC is the LP, searching for cytological identification of malignant cells in the CSF.<sup>4</sup> Given that CSF cytology can have false-negative rates as high as 35%, currently, MRI with contrast is considered the most sensitive imaging modality, with almost 100% sensitivity. Gadolinium-enhanced T1-weighted MRI sequences



**FIGURE 1** Brain MRI obtained in sagittal, axial, and coronal planes. On post-contrast MRI images, there are diffuse enhancement of leptomeninges. There is also an enhancing mass at the upper aspect of the parietal lobe (red arrow)

are considered the best noninvasive means of detecting LC. Diagnostic findings include leptomeningeal enhancement of the brain, spinal cord, cauda equina, or sub-ependymal areas. The enhancement may extend into the sulci of the cerebrum or folia of the cerebellum.<sup>13</sup> Experts suggest that when there is strong evidence of LC on MRI, cytological confirmation is not necessary, and physicians can proceed with the treatment.<sup>14</sup> Our patient refused LP and treatment began based on clinical findings and MRI. There is currently no standard treatment for prostate cancer LC and a decision is best made by a multidisciplinary team. Quality of life should be a focal point and the ultimate treatment goal without exception. Treatment options suggested by the literature include hormonal treatment (in castration-sensitive

prostate cancer), corticosteroids, debulking surgery, WBRT, and intrathecal chemotherapy. However, all of these treatments have been associated with poor outcomes.<sup>15</sup> The present patient was treated with WBRT followed by ineffective hormonal treatment, so he was rechallenged with systemic chemotherapy resulting in favorable clinical and biological responses. Longer follow-up and further studies are preferable to come to a conclusion about a standard approach, especially as the prevalence of LC cases tends to increase as a result of more effective treatments and extended survival in prostate cancer patients.

Currently available therapeutic agents in the management of metastatic and locally advanced prostate cancer do not cross blood-brain barrier adequately. It

seems that improvement of radiotherapy techniques beside finding more about the tumor biology and inventing new targeted drugs might help local and systemic control of patients with prostate adenocarcinoma with leptomeningeal carcinomatosis and intracerebral metastasis.<sup>16-22</sup>

## 4 | CONCLUSION

In prostate cancer patients who present with focal neurological symptoms any time during the course of metastatic phase, leptomeningeal carcinomatosis should be taken into consideration, although it is rare. Timely diagnosis and proper treatment approach may prevent symptom exacerbation and improve quality of life.

### ACKNOWLEDGEMENTS

This study was fully funded by the Babol University of Medical Sciences. We would like to thank the patient for his consent for publication of his data.

### CONFLICTS OF INTEREST

Authors declare that they have no conflicts of interest.

### AUTHOR CONTRIBUTIONS

All authors contributed equally.

### ETHICAL APPROVAL

The study was approved by Babol University of medical Sciences.

### CONSENT

An informed written consent form was obtained from patient.

### DATA AVAILABILITY STATEMENT

The data sets used and/or analyzed during the current study are available from the corresponding authors per request.

### ORCID

Danial Fazilat-Panah  <https://orcid.org/0000-0003-4194-6575>

Ali Emadi Torghabeh  <https://orcid.org/0000-0003-2090-8182>

Zahra Keshtpour Amlashi  <https://orcid.org/0000-0001-7126-0393>

### REFERENCES

- Landis SH, Murray T, Bolden S, Wingo PA. Cancer statistics, 1999. *CA Cancer J Clin.* 1999;49(1):8-31.
- Cone LA, Koochek K, Henager HA, et al. Leptomeningeal carcinomatosis in a patient with metastatic prostate cancer: case report and literature review. *Surg Neurol.* 2006;65(4):372-375.
- Dehghani M, PeyroShabany B, Shahraini R, et al. A case report of prostate cancer with leptomeningeal metastasis. *Cancer Rep.* 2021:e1463. <https://doi.org/10.1002/cnr.2.1463>
- Grossman SA, Krabak MJ. Leptomeningeal carcinomatosis. *Cancer Treat Rev.* 1999;25(2):103-119.
- Baloh R, DeRossett S, Cloughesy T, et al. Novel brainstem syndrome associated with prostate carcinoma. *Neurology.* 1993;43(12):2591.
- Camerlingo M, Nemni R, Ferraro B, et al. Malignancy and sensory neuropathy of unexplained cause: a prospective study of 51 patients. *Arch Neurol.* 1998;55(7):981-984.
- Batool A, Leptomeningeal KA. Leptomeningeal carcinomatosis. 2018.
- Carroll RD, Leigh EC, Curtis Z, Thorpe A, Ballengee J, Pacioles T. A case of leptomeningeal carcinomatosis from aggressive metastatic prostate cancer. *Case Rep Oncol.* 2019;12(1):311-316.
- Yust-Katz S, Mathis S, Groves MD. Leptomeningeal metastases from genitourinary cancer: the University of Texas MD Anderson cancer center experience. *Med Oncol.* 2013;30(1):429.
- Olson ME, Chernik NL, Posner JB. Infiltration of the leptomeninges by systemic cancer: a clinical and pathologic study. *Arch Neurol.* 1974;30(2):122-137.
- Bernstein WB, Kemp JD, Kim GS, Johnson VV. Diagnosing leptomeningeal carcinomatosis with negative CSF cytology in advanced prostate cancer. *J Clin Oncol.* 2008;26(19):3281-3284.
- Wang N, Bertalan MS, Brastianos PK. Leptomeningeal metastasis from systemic cancer: review and update on management. *Cancer.* 2018;124(1):21-35.
- DeAngelis LM, Boutros D. Leptomeningeal metastasis. *Cancer Invest.* 2005;23(2):145-154.
- Neeman E, Salamon N, Rettig M. Leptomeningeal carcinomatosis of prostate cancer: a case report and review of the literature. *Rev Urol.* 2020;22(2):80.
- Orphanos G, Ardavanis A. Leptomeningeal metastases from prostate cancer: an emerging clinical conundrum. *Clin Exp Metas.* 2010;27(1):19-23.
- Ghahramani-Asl R, Porouhan P, Mehrpouyan M, et al. Feasibility of treatment planning system in localizing the COVID-19 pneumonia lesions and evaluation of volume indices of lung involvement. *Dose Response.* 2020;18(3):1559325820962600.
- Homaei Shandiz F, Fanipakdel A, Forghani MN, et al. Clinical efficacy and side effects of IORT as tumor bed boost during breast-conserving surgery in breast cancer patients following neoadjuvant chemotherapy. *Indian J Gynecol Oncol.* 2020;18(2):46.
- Javadinia SA, Shahidsales S, Fanipakdel A, et al. Therapeutic potential of targeting the Wnt/ $\beta$ -catenin pathway in the treatment of pancreatic cancer. *J Cell Biochem.* 2018;120: 6833-6840. <https://doi.org/10.1002/jcb.27835>
- Javadinia SA, Shahidsales S, Fanipakdel A, et al. The esophageal cancer and the PI3K/AKT/mTOR signaling regulatory microRNAs: a novel marker for prognosis, and a possible target for immunotherapy. *Curr Pharm Des.* 2018;24(39):4646-4651.
- Javadinia SA, Gholami A, Joudi Mashhad M, et al. Anti-tumoral effects of low molecular weight heparins: a focus on the treatment of esophageal cancer. *J Cell Physiol.* 2018;233(10):6523-6529.

21. Taghizadeh Kermani A, Hosseini S, Fanipakdel A, et al. A randomized clinical trial on the antitumoral effects of low molecular weight heparin in the treatment of esophageal cancer. *J Cell Physiol.* 2019;234(4):4191-4199.
22. Fazilat-Panah D, Vakili Ahrari Roudi S, Keramati A, et al. Changes in cytokeratin 18 during neoadjuvant chemotherapy of breast cancer: a prospective study. *Iran J Pathol.* 2020;15(2):117-126.

**How to cite this article:** Fazilat-Panah D, Ahmadi N, Moslemi D, et al. A case report of prostate adenocarcinoma with leptomeningeal carcinomatosis and intracerebral metastasis. *Clin Case Rep.* 2021;9:e05000. <https://doi.org/10.1002/ccr3.5000>